

Assessment of Mediastinal Node Involvement by Endoscopic Ultrasonography for Lung Cancer

Hironobu TOOCHIKA

*The First Department of Surgery,
Nagasaki University School of Medicine*

Received for publication, June 25, 1991

ABSTRACT: In 71 patients with lung cancer, preoperative endoscopic ultrasonography (EUS) examination was conducted to evaluate a presence of lymph node metastasis in the mediastinum. The findings of EUS were retrospectively graded in the aspect of (1) the size and the ratio of long/short diameter, (2) the sharpness of the boundary echo, (3) the intensity of the internal echo, and (4) the texture of the internal echo.

The scores estimated herein were statistically significant and multiple correlation coefficient was well correlated as being 0.786. When regarding a 0-2 scores as being negative, a 3-4 score as being undetermined and a 5-7 score as being positive, sensitivity was 100%, specificity 95.7%, and overall accuracy was 96.4% according to retrospective analysis. On the other hand, sensitivity was 100%, specificity 93.8% and overall accuracy was 95.2% according to prospective study.

When the score of EUS examination was ranging three to four, it was difficult to determine positive node metastasis because there included many cases such as negative metastasis, small metastasis in the part of nodes and positive metastasis in well-differentiated adenocarcinoma. Therefore, it is a limit to evaluation by EUS examination.

Nodal involvement in the mediastinum well correlated with a presence of involved #7 node. Therefore, it is of great value to assess a presence of mediastinal node metastasis by evaluating #7 node by EUS examination.

INTRODUCTION

It is well accepted that positive node involvement is greatly influential on the prognosis. Therefore, preoperative assessment of nodal involvement is great value to determine the operative method and to select chemotherapy agent for the treatment of lung cancer¹⁾.

Many investigators²⁻⁴⁾ clarified that CT alone is not a sufficient tool to accurately decide a presence of node metastasis.

The purpose of this study is to evaluate the usefulness and efficacy of EUS to assess a presence of node metastasis in patients with lung cancers.

SUBJECTS AND METHODS

1. Cases studied

Seventy-one primary lung cancer surgical cases experiencing preoperative EUS examination were studied during the 2-year-and-4-month period starting from December 1988 to March 1991. A retrospective study was conducted on the 47 cases up to March 1990 and the result obtained were quantized to scoring numbers, while the 24 cases after April 1990 were subjected to EUS examination and the results were also converted to scores; these indicators were examined prospectively for the relation with the occurrence of lymph node metastasis.

The mean age of the patients was 63.7 (ranging from 37 to 78), of whom 63 were males and eight were females. Their primary sites of cancer development consisted of 45 cases of the right lung and 26 cases of the left lung. The pathological types included 32 cases of squamous cell carcinoma, 37 adenocarcinoma, and 2 large cell carcinoma. Regarding their histopathological N factor, 48 cases belonged to N0, 5 to N1, 17 to N2, and 1 to N3 (**Table 1**).

2. Type of unit and techniques used

The EUS unit adopted was Model EPE-703FP manufactured by Toshiba-Machida (external diameter: 12mm, central wave number: 7.5MHz). Approximately 5ml of non-aerated water was infused, and scanning was performed by the close contact balloon method. Recording was executed using a Polaroid camera. Since the tip of the EUS comprised a 4.5cm long hard portion (the ultrasound probe), careful insertion was required; practically, no problematical situation was experienced during the insertion in all cases. Although there were several cases of complaint on pharyngalgia after examination, no complications occurred.

Table 1. Primary Lung Cancer (71 Cases)

	Retrospective Evaluation	Prospective Evaluation	Total
Number of Cases	47	24	71
Mean Age	63.4	64.3	63.7
Sex			
Male	43	20	63
Female	4	4	8
Primary Site			
Right	26	19	45
Left	21	5	26
Pathological Type			
Squamous Cell Ca.	21	11	32
Adenocarcinoma	24	13	37
Large Cell Ca.	2	0	2
Pathological N			
N0	33	15	48
N1	3	2	5
N2	10	7	17
N3	1	0	1

3. Sites examined

The lymph node categorization followed General Rule for Clinical and Pathological Record of lung Cancer by the Japan Lung Cancer Society⁵⁾. Because the esophagus is situated on the left back side of the trachea, it was difficult to create an image either of the right superior or anterior mediastinum (Right #1, #2, #3, and #3a), resulting in no satisfactory observation. Right #4 was imageable when there was a swollen lymph node around the azygos vein. While the left superior mediastinum, bifurcation of the trachea, and the inferior mediastinum were well imaged, #1, #2, #3p, #8, and #9 often included no lymphadenopathy. Usually it was relatively easy to image #5 and #6, but they were often difficult to observe because of the aortic wall artifact or the long distance from the esophagus. Thus, the points of observation in the present study were defined as the lymph nodes at the bifurcation of the trachea (#7) and the A-P window (left #4). Since it was extremely difficult to conduct a 1:1 comparison of a surgically removed lymph node with an EUS-imaged lymph node, the whole group of lymph nodes at each site as a cluster was subjected to evaluation^{4, 6)}. The sites observed amounted to 96, of which 69 were the tracheal bifurcation and 27 were the A-P window.

4. Scoring

The EUS characteristics of the 66 sites in the 47 cases up to March 1990 were retrospectively examined. The lymph node images were converted to quantitized scores using (1) their size and rate of short/long diameter, (2) the sharpness of boundary echo, (3) the intensity of the internal echo, and (4) the texture of the internal echo (**Table 2**). With respect to the 30 sites in 24 cases after April 1990, preoperative EUS was conducted to determine the scores, and the relationship of these scores with lymph node metastasis was prospectively investigated. The scores were determined through independent evaluation by plural number of examiners, and the maximal value among the lymph node scores was adopted as the score of this site.

Statistical significance was determined using

Table 2. EUS Score

	Score
1. Size and Short Long Diameter*	
SD<5mm or S L≤0.25	0
SD>5mm and 0.25<S L≤0.75	1
SD>5mm and S L>0.75	2
2. Sharpness of Boundary Echo	
Dull and Weak	0
Moderately Sharp	1
Sharp and Strong	2
3. Intensity of Internal Echo	
High Intensity	0
Moderate Intensity	1
Low Intensity	2
4. Texture of Internal Echo	
Diffuse and Homogeneous Pattern	
or High Echoic Nodule	0
Rough and Granular Pattern	1

* SD : Short Diameter

S L: Short Long Diameter

 χ^2 test and multiple regression analysis.

RESULTS

1. Retrospective evaluation and scoring

In 66 sites of the 47 cases up to March 1990, the patterns of EUS image were retrospectively compared between metastasizing and no-metastasizing nodes which were histologically confirmed, and the findings of EUS were scored according to the size of nodes, the ratio of short/long diameter and characteristics of EUS figures.

a) The size and short/long diameter.

The long and short diameter and the ratio of short/long diameter were carefully analyzed.

1) In view of the relationship between long diameter and node metastasis, the greater the long diameter, the higher the positive node metastasis was seen without statistically significant difference (**Table 3a**).

2) With respect to the relationship between short diameter and node metastasis, the greater the short diameter, the higher the positive node metastasis was recognized, i.e. in the short diameter less than 5mm, positive node was none out of 27 sites evaluated, in the ranging from 6 to 10mm, 7 out of 28 (25.0%), in the ranging from 11 to 15mm, 2 out of 6 (33.3%), in the more than 16mm, 3 out of 5 (60%) respectively (**Table**

Table 3. Metastatic Rate by Size (Retrospective)

a. Metastatic Rate by Long Diameter

Lymph Node Involvement	Long Diameter (mm)				Total
	0~5	6~10	11~15	16~	
Metastasis (+)	0	3	1	8	12
Metastasis (-)	5	15	15	19	54

 $\chi^2=5.049$ ($p>0.05$)

b. Metastatic Rate by Short Diameter

Lymph Node Involvement	Short Diameter (mm)				Total
	0~5	6~10	11~15	16~	
Metastasis (+)	0	7	2	3	12
Metastasis (-)	27	21	4	2	54

 $\chi^2=13.679$ ($p<0.01$)

c. Metastatic Rate by Short/Long Diameter

Lymph Node Involvement	Short/Long Diameter			Total
	0~0.25	0.26~0.75	0.76~	
Metastasis (+)	0	8	4	12
Metastasis (-)	7	43	4	54

 $\chi^2=7.214$ ($p<0.05$)

3b).

3) As for the relationship between the ratio of short/long diameter and node metastasis, while the ratio of short/long diameter was ranging from 0 to 0.25, no positive rate of node metastasis was observed in 7 sites, the ratio ranging from 0.26 to 0.75 was 15.7% (8 out of 51 sites), the ratio from 0.76 to 1.00 was 50% (4 out of 8 sites). According to approach to 1.0 of the ratio of short/long diameter, positive node metastasis has increased (**table 3c**).

Nodal involvement correlated well with the short diameter and the ratio of short/long diameter rather than long diameter of nodes. It is suggestive that low incidence of node metastasis indicates the case of less than 5mm of short diameter and less than 0.25 of the ratio of short/long diameter.

b) The sharpness of boundary echo.

The findings of EUS for positive node metastasis were based on the sharpness and the intensity of boundary echo, and those of negative one were unsharpness and lessened intensity of boundary echo as shown in **Fig. 1** and **Fig. 2**.

c) The intensity of internal echo

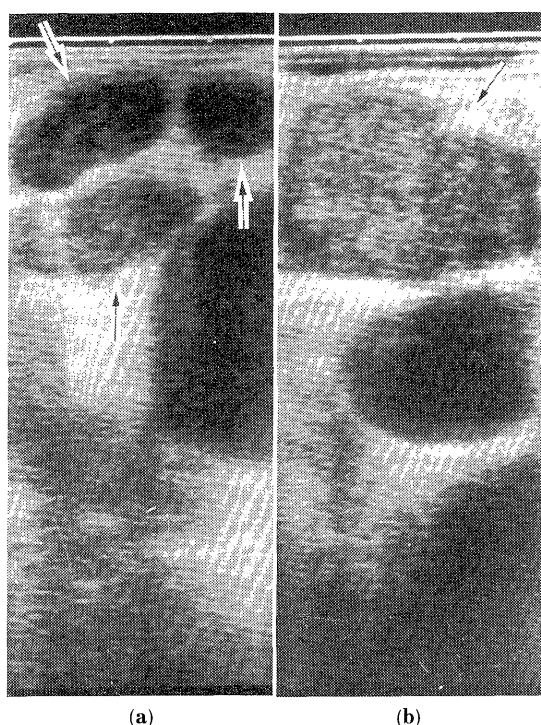


Fig. 1. Endoscopic ultrasonograms of metastatic lymph nodes showed sharp and strong echo of boundaries (a), low intensity of internal echo (a), and rough and granular pattern of internal texture (b).

(a) was EUS-Score 5, (b), EUS-Score 6.

The intensity of echo in metastasizing nodes was low in striking contrast to high echo in non-metastasizing one (**Fig. 1 and 2**).

d) The texture of internal echo

The texture of internal echo was analyzed, identifying between positive and negative node metastasized. In positive node metastasis, the texture of internal echo showed a rough and granular pattern. In contrast, in negative node metastasis, it showed the dense and compact pattern. A few cases with negative node metastasis showed a nodular echo with high density (**Fig. 1 and 2**).

2. Scoring and node metastasis

a) statistical evaluation

Retrospective study on scoring for each analyzed factor was made to evaluate a statistical significance in 47 patients in whom nodes of 66 sites were examined. As a result, node metas-

tasis correlated well with each factor (**Table 4**).

Contributable rates of each evaluated factor to node metastasis were calculated by using multiple regression analysis. It showed almost the same contributable rate as evaluated each factor except for a relatively low sensitivity of boundary echo. The correlation coefficient indicated 0.786, showing a good correlation (**Table 5**).

b) Total of score and node metastasis

1) Retrospective evaluation

A retrospective study was conducted with respect to the relationship between scoring and node metastasis in the 47 patients who were examined before March 1990. Metastatic rate to the nodes showed 0% in a 0-2 scores, 36.4% in a 3-4 scores and 80% in a 5-7 scores, indicat-

Table 4. Metastatic Rate by Each Factors (Retrospective)

1. Size and Short/Long Diameter

Lymph Node Involvement	Score			Total
	0	1	2	
Meta (+)	0	8	4	12
Meta (-)	27	25	2	54

$$\chi^2=16.296 \text{ (p<0.01)}$$

2. Sharpness of Boundary Echo

Lymph Node Involvement	Score			Total
	0	1	2	
Meta (+)	0	5	7	12
Meta (-)	26	25	3	54

$$\chi^2=28.874 \text{ (p<0.01)}$$

3. Intensity of Internal Echo

Lymph Node Involvement	Score			Total
	0	1	2	
Meta (+)	1	4	7	12
Meta (-)	44	8	2	54

$$\chi^2=31.044 \text{ (p<0.01)}$$

4. Texture of Internal Echo

Lymph Node Involvement	Score		Total
	0	1	
Meta (+)	4	8	12
Meta (-)	52	2	54

$$\chi^2=25.577 \text{ (p<0.01)}$$

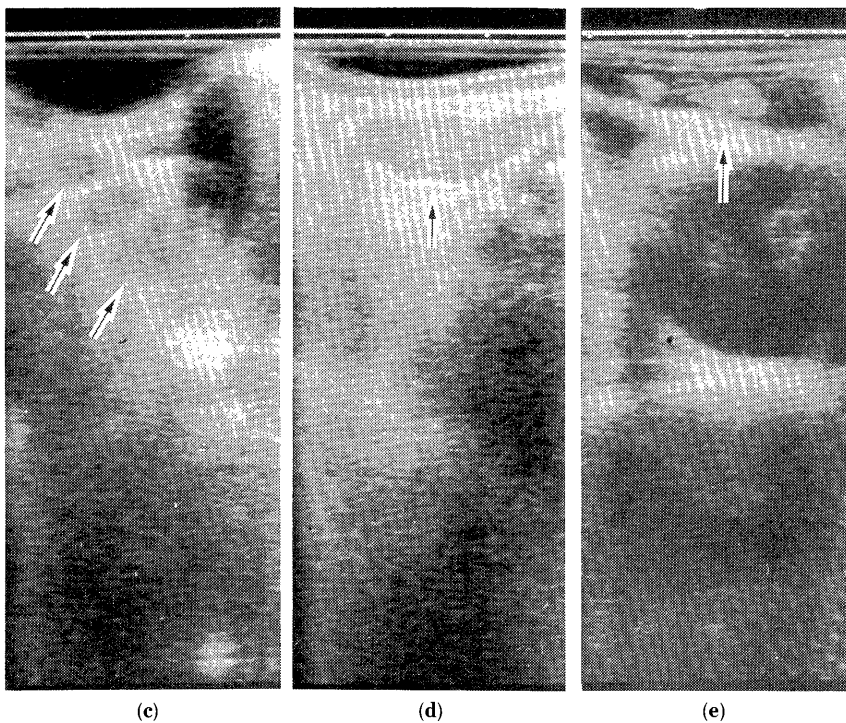


Fig. 2. Endoscopic ultrasonograms of non-metastatic lymph nodes showed dull and weak echo of boundaries (c), high intensity of internal echo (d), and diffuse and homogeneous pattern (d), or high echoic nodule (e) of internal texture.
(c) was EUS-Score 1, (d) and (e), EUS-Score 2.

Table 5. Multiple Regression Analysis (Retrospective)

Factor	F value	(confidence)
1. Size and Short/Long Diameter	5.032	(0.02853)
2. Sharpness of Boundary Echo	2.863	(0.09577)
3. Intensity of Internal Echo	5.577	(0.02142)
4. Texture of Internal Echo	5.818	(0.01888)

Multiple Correlation Coefficient=0.786 ($p < 0.01$)

ing a good correlation between score and node metastasis. Assuming that a 3-4 scores were inability to distinguish, a 0-2 scores indicated no metastasis to the nodes and 5-7 scores strongly suggested a positive of node metastasis, it is concluded that sensitivity increased to 100%, specificity leveled up to 95.7% and overall accuracy was 96.4% respectively (**Table 6a**).

Fig. 3 and **Table 7** showed the node with negative metastasis, the node unable to distinguish from a presence of metastasis and the

node with confirmation of positive metastasis.

2) Prospective evaluation

Prospective study was conducted in the 24 patients after April, 1990. EUS-scores were determined by preoperative EUS examination. On the basis of this study, prospective evaluation was made to define the correlation between node metastasis and EUS-scores. The metastatic rates correlated well with EUS-scores, showing 0% in a 0-2 score, 22.2% in a 3-4 score, 83.3% in a 5-7 score. When a 3-4 score was regarded as a case unable to distinguish, sensitivity increased to 100%, specificity was 93.8% and overall accuracy raised to 95.2% (**Table 6b**).

c) The relationship between EUS-scores and histologic types

1) The total scores and histology

In patients with squamous cell carcinoma, the metastasizing rate of the nodes were 0% in a

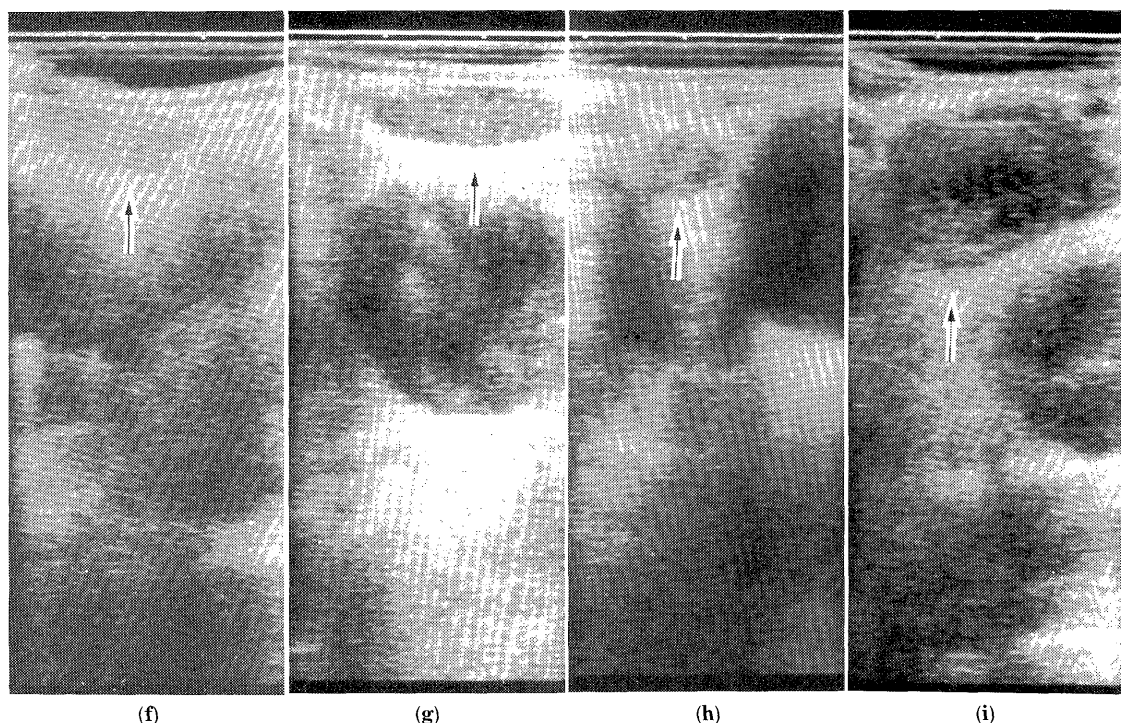


Fig. 3. Endoscopic ultrasonograms of lymph node (f), (g), (h), and (i)

Table 6. Metastatic Rate by Score

a. Retrospective

Lymph Node Involvement	Score			Total
	0~2	3~4	5~7	
Meta (+)	0	4	8	12
Meta (-)	45	7	2	54
Total	45	11	10	66
Sensitivity	100.0%			
Specificity	95.7%			
Accuracy	96.4%			

b. Prospective

Lymph Node Involvement	Score			Total
	0~2	3~4	5~7	
Meta (+)	0	2	5	7
Meta (-)	15	7	1	23
Total	15	9	6	30
Sensitivity	100.0%			
Specificity	93.8%			
Accuracy	95.2%			

Table 7. EUS-Score of Lymph Node (f), (g), (h), and (i)

	(f)	(g)	(h)	(i)
Size and Short/Long Diameter	1	1	2	1
Sharpness of Boundary Echo	0	2	1	2
Intensity of Internal Echo	0	1	1	2
Texture of Internal Echo	0	0	0	1
Total of Score	1	4	4	6
Lymph Node Metastasis	(-)	(-)	(+)	(+)
Pathology of Primary Tumor	Ad	Sq	Ad*	Ad

Ad: Adenocarcinoma

Sq: Squamous Cell Carcinoma

* Well Differentiated Adenocarcinoma

0-2 score, 10.0% in a 3-4 score, 62.5% in a 5-7 score, showing a close correlation. Except for a 3-4 score, sensitivity became 100%, specificity was 89.3% and overall accuracy was 90.9% (Table 8a).

In patients with adenocarcinoma, the metastasizing rate of the node were 0% in a 0-2 score, 50% in a 3-4 score, 100% in a 5-7 score, showing a close correlation. Except for a 3-4 score, sensitivity became 100%, specificity was 100%,

Table 8. Metastatic Rate by Pathological Type
a. Squamous Cell Carcinoma

Lymph Node Involvement	Score			Total
	0~2	3~4	5~7	
Meta (+)	0	1	5	6
Meta (-)	25	9	3	37
Total	25	10	8	43
Sensitivity	100.0%			
Specificity	98.3%			
Accuracy	90.9%			

b. Adenocarcinoma

Lymph Node Involvement	Score			Total
	0~2	3~4	5~7	
Meta (+)	0	5	7	12
Meta (-)	34	5	0	41
Total	34	10	7	51
Sensitivity	100.0%			
Specificity	100.0%			
Accuracy	100.0%			

overall accuracy was 100% (**Table 8b**)

In patients with large cell carcinoma, only two sites were eligible into this study. One was positive metastasis to node with 7 score, the other was negative with 1 score.

2) Histologic examination in the nodes with positive metastasis.

Nineteen nodes with positive metastasis were histologically examined. These were 6 squamous cell carcinomas (1 poorly differentiated, 5 moderately diff.), 12 adenocarcinomas (5 poorly, 6 moderate and 1 well diff.), 1 large cell carcinoma. From the standpoint of three factors of the size and ratio of short/long diameter, the sharpness of boundary echo and the texture of internal echo, there was a tendency toward much more decreased score in adenocarcinomas rather than in squamous cell carcinomas (**Table 9**). In view of the relationship between cell differentiation and EUS-score in adenocarcinoma, many numbers were scored 1 in size and ratio of short/long diameter regardless of cell differentiation. On the other hand, on the basis of three factors of the sharpness of boundary echo, the intensity of internal echo and the texture of internal echo, EUS-scores in moderate and well differentiated adenocarcinomas were

Table 9. EUS-Score of Metastatic Lymph Nodes by Pathological Type

1. Size and Short/Long Diameter

Pathological Type	Score			Total
	0	1	2	
Squamous Cell Ca.	0	3	3	6
Adenocarcinoma	0	10	2	12
Large Cell Ca.	0	0	1	1

2. Sharpness of Boundary Echo

Pathological Type	Score			Total
	0	1	2	
Squamous Cell Ca.	0	2	4	6
Adenocarcinoma	0	7	5	12
Large Cell Ca.	0	0	1	1

3. Intensity of Internal Echo

Pathological Type	Score			Total
	0	1	2	
Squamous Cell Ca.	1	2	3	6
Adenocarcinoma	0	5	7	12
Large Cell Ca.	0	0	1	1

4. Texture of Internal Echo

Pathological Type	Score		Total
	0	1	
Squamous Cell Ca.	1	5	6
Adenocarcinoma	6	6	12
Large Cell Ca.	0	1	1

more lowered than those in the poorly differentiated.

In the total EUS-score, a 3-4 score showed moderate to well differentiated adenocarcinoma in 4 out of 5 sites (**Table 10, Fig. 4**).

There was small sized metastasis into the two nodes which was delineated as the diameter less than 5mm, of which histologic types were poorly differentiated squamous cell carcinoma in one and poorly differentiated adenocarcinoma in the other.

3. Evaluation in indistinguished cases from node regarding EUS-score.

The interrelation between distinguishable nodes of #7 and #4 and indistinguishable node was evaluated in association with EUS-scores according to tumor locations.

Table 10. EUS-Score of Lymph Nodes with Metastasis of Adenocarcinoma by Differentiation

1. Size and Short/Long Diameter

Differentiation of Primary Tumor	Score			Total
	0	1	2	
Poorly	0	4	1	5
Moderately	0	5	1	6
Well	0	1	0	1

2. Sharpness of Boundary Echo

Differentiation of Primary Tumor	Score			Total
	0	1	2	
Poorly	0	2	3	5
Moderately	0	4	2	6
Well	0	1	0	1

3. Intensity of Internal Echo

Differentiation of Primary Tumor	Score			Total
	0	1	2	
Poorly	0	1	4	5
Moderately	0	4	2	6
Well	0	1	0	1

4. Texture of Internal Echo

Differentiation of Primary Tumor	Score		Total
	0	1	
Poorly	1	4	5
Moderately	4	2	6
Well	1	0	1

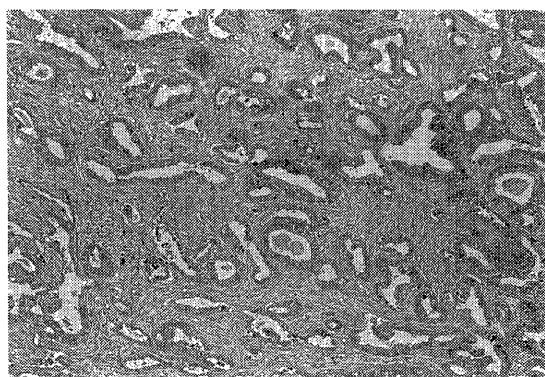
5. Total of EUS-Score

Differentiation of Primary Tumor	Score			Total
	0~2	3~4	5~7	
Poorly	0	1	4	5
Moderately	0	3	3	6
Well	0	1	0	1
Total	0	5	7	12

a) Lung cancer arising from the right side

The presence of node metastasis in #7 was evaluated in comparison with EUS-scores and node metastasis elsewhere in the mediastinum in cases of lung cancer arising from the right side (Table 11).

The high incidence (50 to 100%) of node metastasis of #1 to #4 was noted in cases with nodal involvement of #7. Unless the node of

**Fig. 4.** Microscopic finding of metastatic lymph node with Score 3 revealed a well differentiated adenocarcinoma. (H. E. x330)

#7 was involved, the incidence of nodal involvement in the node of #1 to #4 showed 5 to 20%.

In case of lung cancer arising from the middle lobe with positive node of #7, the incidence of metastasis into the node of #4 was 50%. In contrast, in cases of negative node of #7, there was none of node metastasis in #4.

From the standpoint of EUS-score, when it regard from 5 to 7 in EUS-score, the incidence of nodal involvement of #1 to #4 was high (25 to 100%). In contrast, it was 6 to 22% in frequency when was 0-2 EUS-score. And the incidence of node metastasis in #4 was 50% when EUS-score was 3-4 in #7 node. However, there was no chance of nodal involvement in the mediastinum in case of a 0-2 EUS-score.

b) lung cancer arising from the left

Nodal involvement in the mediastinum was evaluated in the aspect of a presence of left #4 and #7 node metastasis and EUS-score according to tumor location in cases of lung cancer arising from the left side (Table 12 and 13).

1) #7 node

When node metastasis in #7 was positive, there was no nodal involvement in the node of #1 to #3 on the left side. In contrast, high incidence of node metastasis in #4, #5 and #10 was noted, ranging from 33 to 100% in frequency.

In case of negative node metastasis of #7, two cases (14%) of #4 were positive node metastasis. A similar interrelation between positive node metastasis and EUS-score was recognized.

Table 11. Mediastinal Involvement by Metastasis of #7 and EUS-Score of #7
(Cases with the Right Lung Cancer)

a. Metastatic Rate by Metastasis of #7

Primary Site (n)	Metastasis of #7	Metastatic Rate of Mediastinal Lymph Nodes (%)						
		rt #1	rt #2	#3	rt #4	rt #8	rt #9	rt #10
RUL (2)	(+)	50	100	50				50
RUL (21)	(-)	5	5	10	20			5
RML (2)	(+)				50			50
RML (6)	(-)							
RLL (4)	(+)	75	50	50	75			75
RLL (10)	(-)		10	20	20			

b. Metastatic Rate by EUS-Score of #7

Primary Site (n)	EUS Score	Metastatic Rate of Mediastinal Lymph Nodes (%)						
		rt #1	rt #2	#3	rt #4	rt #8	rt #9	rt #10
RUL (4)	5~7	25	25	25				25
RUL (1)	3~4							
RUL (18)	0~2	6	11	11	22			6
RML (1)	5~7							
RML (2)	3~4				50			50
RML (5)	0~2							
RLL (2)	5~7	100	50	100	100			50
RLL (4)	3~4	25	50	25	50			50
RLL (8)	0~2			13	13			

Table 12. Mediastinal Involvement by Metastasis of #7 and EUS-Score of #7
(Cases with the Left Lung Cancer)

a. Metastatic Rate by Metastasis of #7

Primary Site (n)	Metastasis of #7	Metastatic Rate of Mediastinal Lymph Nodes (%)								
		lt #1	lt #2	#3	lt #4	lt #5	lt #6	lt #8	lt #9	lt #10
LUL (3)	(+)				100	33			33	66
LUL (14)	(-)				14					
LLL (0)	(+)									
LLL (7)	(-)									

b. Metastatic Rate by EUS-Score of #7

Primary Site (n)	EUS Score	Metastatic Rate of Mediastinal Lymph Nodes (%)								
		lt #1	lt #2	#3	lt #4	lt #5	lt #6	lt #8	lt #9	lt #10
LUL (2)	5~7				100					50
LUL (4)	3~4				50	25			25	25
LUL (11)	0~2				9					
LLL (0)	5~7									
LLL (3)	3~4									
LLL (4)	0~2									

When EUS-score indicated 5-7 in #7 node, there was significantly high incidence (50 to 100%) of node metastasis in #4, #5 and #10 nodes

although no metastasis in #1 to #3 nodes.

2) Left #4 node

When node metastasis in left #4 was positive,

Table 13. Mediastinal Involvement by Metastasis of Lt-#4 and EUS-Score of Lt-#4
(Cases with the Left Lung Cancer)

a. Metastatic Rate by Metastasis of Lt #4

Primary Site (n)	Metastasis of #4	Metastatic Rate of Mediastinal Lymph Nodes (%)								
		lt #1	lt #2	#3	lt #5	lt #6	lt #7	lt #8	lt #9	lt #10
LUL (5)	(+)				20		60		20	40
LUL (12)	(-)									
LLL (1)	(+)									
LLL (8)	(-)									

b. Metastatic Rate by EUS-Score of Lt #4

Primary Site (n)	EUS Score	Metastatic Rate of Mediastinal Lymphs Nodes (%)								
		lt #1	lt #2	#3	lt #5	lt #6	lt #7	lt #8	lt #9	lt #10
LUL (4)	5~7						100			
LUL (5)	3~4				20		20		20	20
LUL (8)	0~2									
LLL (1)	5~7									
LLL (1)	3~4									
LLL (7)	0~2									

there was no nodal involvement in the node of #1 to #3 on the left side. In contrast, high incidence of node metastasis in #5, #7, #9 and #10 on the left was noted, ranging from 20 to 60% in frequency. The results based on EUS-score were compatible with those of histologic examination.

In case of lung cancer arising from the upper lobe on the left side, there was no node metastasis in #1 to #3 nodes in the upper mediastinum on the left when EUS-scores indicated 5 to 7 in #4 nodes. On the other hand, high incidence (100%) of positive node metastasis in #7 was observed. In case of a 0-2 EUS-score in #4 node, there was no nodal involvement elsewhere in the mediastinum when lung cancer was arising from lower lobe on the left.

DISCUSSION

There is a great concern about the presence or the extent of nodal involvement in relation to improvement of the surgical outcome for lung cancer. It is well known that a presence of nodal involvement in the mediastinum (N2) means poor prognosis⁷⁾. Therefore, it is necessary to determine preoperatively as to whether nodal involvement is present or not¹⁾.

It is a rule that various kinds of diagnostic tools such as laminography, computed tomography (CT) and mediastinoscopy were applied for precise determination of N factor. According to clinical prevalence of CT examination, it is a common practice to assess a presence of node metastasis preoperatively. It is clarified that sensitivity in determining a presence of node metastasis is impropotional to specificity, when determined by the size of nodes on CT image. As a result, overall accuracy is reported as being 60 to 80%^{2~4)}.

In this study, the results of EUS examination performed since December 1988 were evaluated with respect to validity of preoperative assessment for node metastasis.

Natori⁸⁾ first attempted to assess the lesions in the hilum of the lung since EUS had been developed for cardiac sonography. Since then, it is clarified that EUS is of great use to determine the depth of cancer infiltration and a presence of node metastasis in the mediastinum.^{6, 8~10)}

It is characteristic that EUS enables each node to delineate more sharp than CT. In consequence, accurate evaluation of the size of node detected is promised in EUS examination.

It is now accepted^{4, 6, 12~15)} that sensitivity

ranges from 50 to 100%, specificity is 76 to 93%, overall accuracy indicates 71 to 94 % for assessment of node metastasios by EUS examination.

As the results of this series, the accuracy of EUS examination was 70 to 80%. Therefore, it is required that the texture of internal echo on the findings of EUS examination should be assessed in addition to the evaluation of the size of nodes detected. EUS examination is superior to assessment of the texture of internal echo. In fact, the assessment of the texture of internal echo depends on subjective judgement, so that we cannot deny to be short of an objective justification. Therefore, the scoring on the basis of findings of EUS examination was attempted in this series. The scoring was conducted with respect to the three points —the sharpness of margin, the intensity of internal echo and the texture of internal echo— in the 66 sites of the 47 patients exermined by March, 1990. The positive node features in the EUS examination revealed the low intensity of internal echo with sharp margin and rough texture of internal echo. On the other hand, the negative node features in the EUS examination showed the high density and dense texture of internal echo with irregular margin as reported by many inverstigators^{10, 16)}. Meanwhile, Murata¹⁰⁾ reported that the findings of sharp margin and unhomogenous internal echo were particulr in the nodes of positive metastasis.

In this series, validity of EUS examination for determination of node metastasis was evaluated in patients with lung cancer. Each factor in EUS examination correlated well with a presence of node metastasis with statistically significant difference ($p < 0.01$). In addition, the multiple correlation coefficient calculated by multiple correlation analysis was 0.786, indicating good correlation.

The possibility of positive node metastasis was very low in cases of 0 to 2 score, but in 5 to 7 score high possibility of node metastasis was revealed, whereas in 3 to 4 score one third was positive and two thirds were negative so that determination of positive node metasatasis was not cartain in cases of 3 to 4 score.

When regarding 3 to 4 score as ESU (\pm), 0-2 score as EUS (-) and 5 to 7 score as EUS (+),

sensitivity was 100%, specificity 95.7 and overall accuracy 96.4%, revealing a good result. A prospective study, in the 30 sites of 24 patients examined since April 1990, indicated that sensitivity was 100%, specificity 93.8% and overall accuracy 95.2% respectively. On the basis of this results, it is concluded that it is of great value to determine a presence of node metastasis by EUS examination.

Although sensibility was 100% in both squamous cell and adenocarcinomas, in relation to histologic types, the specificity in squamous cell carcinoma was inferior to that in adenocarcinoma. This is in association with non-specific node swelling in squamous cell carcinoma which is more often seen. This fact is based on overestimated result in squamous cell carcinoma for EUS (+) finding nodes. In fact, histoloigcally negative node was confirmed for the 3 EUS (+) finding nodes.

When compared with metastatic rates to nodes in case of EUS (+) finding, the frequency in adenocaricnoma was higher than that in squamous cell carcinoma. On the other hand, when compared with metastaitc rates to nodes in case of EUS (\pm) findig, the frequency in adenocarcinoma showed 50% despite 10% in squamous cell carcinoma.

The difference in metastatic rates between squamous cell carcinoma and adenocarcinoma was associatd with lowered scores in relation to findings in EUS examination except for the intensity of internal echo.

In analysis of differentiation, the scores in moderate and well differentiated adenocarcinomas were prone to be lower than those in poorly differentiated one. In view of the total of scores, those obtained from 4 sites out of the 5 sites were moderate and well differentiated adenocarcinoma. Kobayashi¹⁷⁾ reported that homogenous tissues demogenous low echogenic image in US-examination. It is suggested that high echogenic image with indefinite margin should be demonstrated in well-differentiated adenocarcinoma, because of admixture of fibrous tissues in stroma and ductal structers.

As for the rates of short/long diameter, most of adenocarcinoma showed elliptical shape.

It is expected that determination of node metastasis should be more enhanced in ac-

curacy when considering the types of histology and the grades of differentiation, because there are some differences in EUS-scores in accordance with histologic types and differentiations.

In addition, it is interesting to emphasize that determination of node metastasis is difficult when there is small metastasis in the part of nodes as reported by many investigators^{4, 6, 10, 15}. In this series, in case of a result of EUS (\pm) examination, it implies that it directly relates to negative node metastasis in squamous cell carcinoma although there is no denying the fact of a presence of small metastasis in the part of the node. Meanwhile, it is difficult to determine a presence of node metastasis in adenocarcinoma, because EUS (\pm) finding means not only a presence of small metastasis in nodes but also node metastasis in well differentiated adenocarcinoma. Therefore, EUS examination has a limit to determine node metastasis. Further detailed analysis in boundary and internal echo is needed for enhancement of diagnostic accuracy.

On the basis of this study, when #7 nodes are histologically involved and indicate a 5 to 7 score in EUS-examination, upper mediastinal nodes (#1 to 3) are also involved in cases with lung cancers on the right side. On the other hand, when the score in EUS examination is ranging from 0 to 2, node metastasis is seen in 5 to 20% in frequency. Therefore, it is concluded that EUS-examination is of great use to determine whether node metastasis is present or not, even though EUS-examination is difficult in evaluating #1 to #3 nodes on the right side.

Meanwhile, when #7 and/or #4 node metastases are histologically positive, hilar and infra-mediastinal nodes are involved in no cases with lung cancers on the left side. In this study, there was no metastasis in #1 to #3 nodes on the left side. It was consistent with the frequency in EUS-examination.

Careful evaluation enabled a presence of node metastasis in the mediastinum to be precise by EUS-examination in #4 and/or #7 nodes. In conclusion, EUS examination is of great value to evaluate node metastasis in the mediastinum by scoring, and also it is a simple and safe method to continuously evaluate with real time.

ACKNOWLEDGEMENT

The author thanks Prof. Masao Tomita, the First Department of Surgery, Nagasaki University School of Medicine, for his advice and revision, and also staff of the Department of surgery for their cooperation.

REFERENCES

- 1) Keiichi Masuzoe, Akira Suzuki, Takehito Nakabayashi, *et al.*: Evaluation of the Clinical TNM in Comparison with the Surgicopathological TNM in Lung Cancer. *Jap J Cancer Clinics*, 25: 181-189, 1979.
- 2) Hiroyuki Nishiyama, Masafumi Kajita, Heichi Yano, *et al.*: Computed Tomographic Evaluation of Mediastinal Lymph Node Metastasis from Primary Lung Cancer. *Lung Cancer (Japanese)*, 25: 977-985.
- 3) Doooms G.C., Hricak H.: Radiologic Imaging Modalities, Including Magnetic Resonance, for Evaluating Lymph Nodes (Medical progress). *West J Med*, 144:49-57, 1986.
- 4) Daiso Kondo, Tsuguo Naruke, Haruhiko Kondo, *et al.*: Endoscopic Ultrasound Examination for Mediastinal Lymph Node Metastasis of lung Cancer. *Jap J Resp Surg*, 2: 125-133, 1988.
- 5) The Japan Lung Cancer Society: General Rule of Clinical and Pathological Record of Lung Cancer. The 3rd Edition. Kinbara, Tokyo 1987.
- 6) Hajime Kumegawa: Study of the Endoscopic Ultrasonography for Esophageal Carcinoma. *Jap J Gastrointestinal Surg*, 18: 1774-1783, 1985.
- 7) Mitsuo Ohta, Nobuyuki Hara, Tasuku Nakada, *et al.*: Survival of Cases of Resected Primary Lung Cancer. *Lung Cancer (Japanese)*, 25: 77-83, 1985.
- 8) Hiroshi Natori, Shigeru Tamaki, Saburou Izumi, *et al.*: Transesophageal Ultrasonography of the Hilar and Mediastinal Disorders by Linear Electronic Scanning Array Transducer. *JSUM Proceeding*, 39: 55-56, 1981.
- 9) Junichi Kuramoto, Akio Hirosaki, Tetsurou Nishihira, *et al.*: A New Modelity for Diagnosis of the Mediastinal Lymphnode Metastasis of Esophageal Cancer -Transesophageal Ultrasonic Tomography of the Mediastinum-. *Clinical Surg*, 38: 1065-1071, 1983.
- 10) Yoko Murata: The Evaluation of Endoscopic Ultrasonography and Conventional Ultrasonography for Staging in Superficial Esophageal Cancer -Assesment by Histological Findings

- and Clinical Course—. *Jap J Gastrointestinal Surg*, **22**: 195-204, 1989.
- 11) Takashi Danbara, Hideo Kobayashi, Shigeru Tamaki, *et al.*: Endoscopic Ultrasonography for N-factor in Lung Cancer. *Lung Cancer* (Japanese), **24**: 499, 1984.
 - 12) Hiroyuki Soga, Ryuzo Takeuchi, Hajime Kurita, *et al.*: Ultrasonic Evaluation of Mediastinal Lymph Node Metastasis, Especially to Subcarinal Node, in Lung Cancer by Trans-Esophageal Radial Scan. *Clinical Surg*, **42**: 1045-1410, 1987.
 - 13) Hidehiko Sakio, Yutaka Yamaguchi: Transesophageal Endoscopic Ultrasonography for Preoperative Assessment of N-Factor in Lung Cancer. *Jap J Resp Surg*, **2**: 103-115, 1988.
 - 14) Hideo Kobayashi, Takashi Danbara, Shigeru Tamaki, *et al.*: Detection of the Mediastinal Lymph Nodes Metastasis in Lung Cancer by Endoscopic Ultrasonography. *Jap J Med*, **127**: 17-22, 1988.
 - 15) Yoshihiro Moriguchi: Usefulness of Endoscopic Ultrasonography in the Patients with Esophageal Cancer and Lung Cancer. *Kurume Med J*, **53**: 149-159, 1990.
 - 16) Heiji Yoshinaka: Evaluation of Abdominal Ultrasonography in Esophageal Cancer and Gastric Cancer Cases —Detection of Metastasized Lymph Nodes Surrounding the Celiac Axis—. *Igaku Kenkyu*, **53**: 247-265, 1983.
 - 17) Kobayashi T., Hayashi M., Tazaki H. *et al.*: Ultrasonic tissue characterization of malignant lymphoma. *J UOEH*, **8**: 63-72, 1986.