

Technical Report

High-speed digital imaging system with a transnasal flexible fiberoptic endoscope for observing vocal fold vibration

Kenichi KANEKO, Takeshi WATANABE, Chiharu KIHARA, Koichi SAKAGUCHI, Haruo TAKAHASHI

The aim of this study was to establish a method for observing vocal fold vibration using a transnasal flexible fiberoptic endoscope and a high-speed camera for clinical use. We assembled a high-speed digital imaging system with an ordinary flexible endoscope and a highly sensitive high-speed camera (HAD-D71; DITECT Corporation, Tokyo, Japan) with ISO 5,000,000. The camera had an 8-GB internal storage memory for video capture of up to 7.0 s with the usual setting of 640 × 480 pixels at 4000 fps. Using the nasal route, the system enabled us to observe vocal fold vibration during running speech with adequate brightness and good image quality. Our high-speed digital imaging system with a flexible endoscope can be a useful option to observe vocal fold vibration during running speech and is an alternative to difficult transoral rigid endoscopy in patients complaining of voice problems.

ACTA MEDICA NAGASAKIENSIA 61: 45–47, 2017

Key words: high-speed digital imaging, transnasal flexible fiberoptic endoscopy, vocal fold vibration, voice disorders, running speech

Introduction

Observing vocal fold vibration is essential when investigating the causes of voice hoarseness. Videostroboscopy has been widely used for this purpose, but its clinical use is limited because it relies on periodic vocal fold vibration and stable phonation frequency to activate the strobe light¹. These conditions are not always present in disordered voices. On the other hand, high-speed digital imaging (HSDI) has a clear advantage over videostroboscopy because it can visualize even aperiodic vocal fold vibration or unstable phonation frequency.

In the clinical setting, HSDI systems have used a rigid laryngeal endoscope^{2, 3} because of its superior brightness and optical resolution compared with the traditional transnasal flexible fiberoptic endoscope. However, it is sometimes difficult to transorally examine the vocal folds with a rigid endoscope due to individual differences in oropharyngeal anatomy and the gag reflex. Furthermore, the basic disad-

vantage of the procedure is the restriction of phonatory samples to vowels like /e/, and that in unnatural position of the subject with tongue protrusion.

To overcome these problems, we assembled a new and simple high-speed imaging system using a flexible endoscope and a high-speed digital camera (HAD-D71; DITECT Corporation, Tokyo, Japan) with excellent light sensitivity. Here we demonstrate the usefulness of our system for clinical application.

Technique

The HSDI system (Figure 1) consisted of the following components: (1) an HAD-D71 high-speed digital camera; (2) a 50-mm lens and lens adapters; (3) a flexible fiberoptic nasopharyngolaryngoscope with a distal tip diameter of 3.4 mm (PENTAX FNL-10RP3; HOYA Corporation, Tokyo, Japan); (4) a 400-W xenon constant light source (Titan 400;

Address correspondence: Kenichi Kaneko, MD, PhD, Department of Otolaryngology-Head and Neck Surgery, Nagasaki University Graduate School of Biomedical Sciences, 1-7-1 Sakamoto, Nagasaki 852-8501, Japan

Tel: +81-95-819-7349, Fax: +81-95-819-7352, Email: kkaneko@nagasaki-u.ac.jp

Received April 1, 2016; Accepted May 30, 2016



Figure 1. The high-speed digital imaging system using an HAD-D71 camera and a flexible fiberoptic nasopharyngolaryngoscope. In this figure, the camera is mounted on a tripod. However, it is usually placed on the shoulder of the examiner during video capture.

Sunoptic Technologies®, Florida, USA); (5) a foot switch; (6) a cardioid condenser lavalier microphone (AT831b; Audio-Technica U.S., Inc., Ohio, USA); (7) a mixer with microphone preamp and USB/Audio interface (Xenyx 302USB; Behringer GmbH, Germany); and (8) a personal computer. The system shared most of the components with the other HSDI system with a rigid endoscope³.

HAD-D71 is a digital camera with a light sensitivity of ISO 5,000,000 (monochrome or color). The camera had an 8-GB internal storage memory for video capture of up to 7.0 s with the usual setting of 640×480 pixels at 4000 fps. We preferred a monochrome camera because it could provide higher contrast images than a color camera. The weight of the camera was approximately 1.2 kg.

The recording, playback, and preservation of images were controlled by a software (HAS-X Viewer; DITECT Corporation, Tokyo, Japan) in the personal computer connected to the camera. The audio recording and playback were controlled by free software (Audacity®; Audacity Development Team, <http://audacity.sourceforge.net/>) in the same computer.

During video capture, the examiner recorded images in a circular recording mode, wherein the oldest image was overwritten by the newest until a trigger signal was given. The examiner also started audio waveform acquisition through two channels; the left channel was for the patient's voice and the right was for the trigger signal.

The examiner held the camera on his/her shoulder and transnasally inserted the flexible endoscope into the patient's larynx. The patient was instructed to phonate while the examiner observed the vocal folds through the monitor of the personal computer. When the examiner activated the foot switch, a trigger signal stopped the image recording and any images recorded for 7.0 s before the trigger were preserved.

The trigger signal was recorded as a waveform in a stereo audio file (44.1 kHz, 16-bit, WAVE file format) with waveforms from the microphone. Later on, the audio waveforms could be synchronized with the recorded images using the trigger signal. Figure 2 illustrates a diagram of the signals in the HSDI system.

Figure 3 shows example images of vocal fold vibration in a 44-year-old female who was examined using this system. She presented with a hoarse voice secondary to bilateral vocal fold nodules. In this case, the mucosal waves were reduced but present on the nodules; this finding indicated that the nodules were edematous and soft. Figure 4 illustrates a kymographic image of vocal fold vibration obtained from a healthy 51-year-old male during running speech. The vocal folds did not vibrate when pronouncing the voiceless plosives /p/ and /t/.

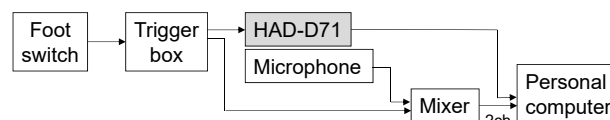


Figure 2. A diagram of signals in the HSDI system.

Discussion

Flexible endoscopy via the nasal cavity makes it possible to examine the vocal folds with less discomfort compared with rigid endoscopy via the oral cavity. It also allows examination during running speech, including consonants. This means that it will be helpful for diagnosis of functional abnormalities such as abductor spasmodic dysphonia. However, the use of an HSDI system with a flexible endoscope has been limited to basic research on vocal fold vibration because the quality of the images was not sufficient for clinical application.

Our new HSDI system enabled us to observe vocal fold vibration with adequate brightness and good image quality. The basic composition of the system was simple; it used a high-speed digital camera with excellent light sensitivity and spatial resolution, an ordinary flexible endoscope, a 400-W light source, and a personal computer. It did not need any additional equipment such as another light source to increase brightness.

However, in general, even if the camera has excellent spatial resolution, the image quality of an HSDI system with a flexible endoscope is limited because of the basic mechanism of the flexible endoscope, which uses a coherent fiber

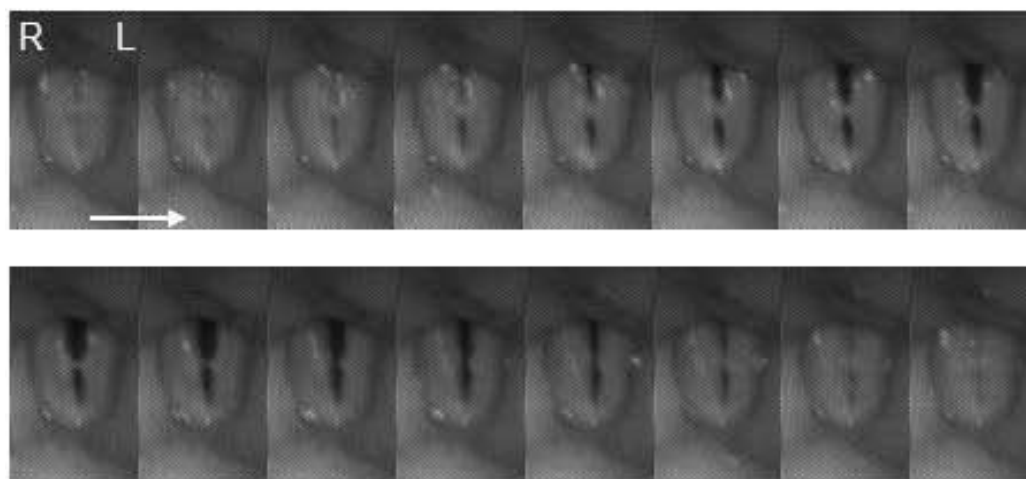


Figure 3. A 44-year-old female with hoarseness was examined using the HSDI system with a flexible fiberoptic endoscope. Findings show bilateral vocal fold nodules and vocal fold vibration. One glottal cycle (4 ms) is shown in 16 sequential images.

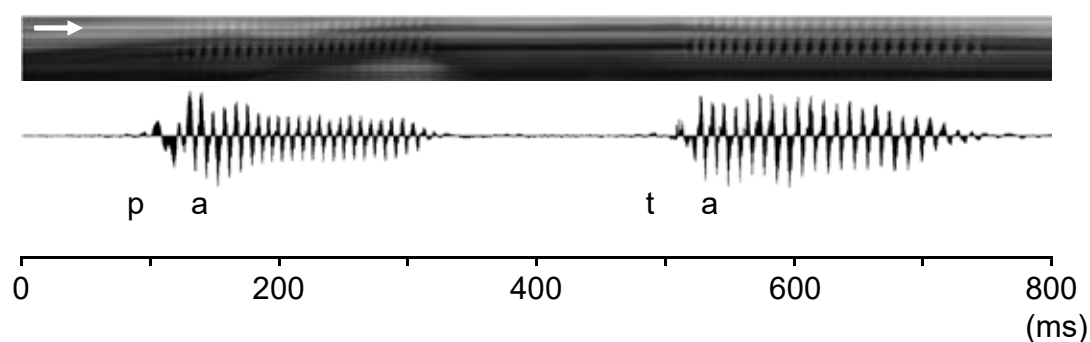


Figure 4. A healthy 51-year-old male was examined using the HSDI system with a flexible fiberoptic endoscope. Kymogram and sound waveforms obtained during phonation of “pata” over 800 ms.

bundle to transmit images to the camera. This bundle includes tens of thousands of fibers, each of which relays a single dot in a fiberoptic image; therefore, image quality depends on the number of fibers. From this point of view of obtaining better images, we consider an HSDI system with a rigid endoscope as the first choice for the observation of vocal fold vibration.

Our HSDI system with a flexible endoscope can be a useful option to observe vocal fold vibration during running speech and is an alternative to difficult transoral rigid endoscopy in patients complaining of voice problems.

Conflict of interest

No competing financial interests exist.

References

- 1) Kendall KA. High-speed laryngeal imaging compared with videostroboscopy in healthy subjects. *Arch Otolaryngol Head Neck Surg* 135: 274-281, 2009
- 2) Kaneko K, Sakaguchi K, Inoue M, Takahashi H. Low-cost high-speed imaging system for observing vocal fold vibration in voice disorders. *ORL J Otorhinolaryngol Relat Spec* 74: 208-210, 2012
- 3) Kaneko K, Watanabe T, Inoue M, Takahashi H. A novel high-speed digital imaging system for assessing vocal fold vibration. *Acta medica Nagasakiensia* 59: 37-40, 2014

