

**Standardized less invasive living donor hemihepatectomy by the hybrid method  
through short upper midline incision**

Akihiko Soyama, Mitsuhsa Takatsuki, Masaaki Hidaka, Izumi Muraoka, Takayuki  
Tanaka, Izumi Yamaguchi, Ayaka Kinoshita, Takanobu Hara, Susumu Eguchi

Department of Surgery, Nagasaki University Graduate School of Biomedical Sciences

**Running title:** Living donor hepatectomy by hybrid technique

**Address correspondence to:** Susumu Eguchi, MD.

Department of Surgery, Nagasaki University Graduate School of Biomedical Sciences,

1-7-1 Sakamoto, Nagasaki 852-8501, Japan

TEL: 81-95-819-7316

FAX: 81-95-819-7319

E-mail: [sueguchi@nagasaki-u.ac.jp](mailto:sueguchi@nagasaki-u.ac.jp)

## **ABSTRACT**

**Background:** Recently, the applications of less invasive liver surgery in living donor hepatectomy (LDH) have been reported. The objective of this study was to evaluate the safety and efficacy of our standardized hybrid method with midline incision in LDH.

**Methods:** Hemihepatectomy with the hybrid method was performed in recent 15 donors of 150 living donors between 1997 and August 2011. Six donors underwent right hemihepatectomy; nine donors underwent left hemihepatectomy. Eight centimeter subxiphoid midline incision was created for hand assistance during the liver mobilization and for graft extraction, using a GelPort® hand port device. Pneumoperitoneum (CO<sub>2</sub> at 8 mmHg) was established. A 5mm port was placed for dissection of the ligaments. After the sufficient mobilization of the liver, the hand-assist/extraction incision was extended up to 12 cm for the right hemihepatectomy and 10cm left hemihepatectomy. The laparotomy with short incision was retracted by Omni-Tract® (MN, USA) for optimal exposure. Encircling hepatic veins and hilar dissection were performed under direct vision. Parenchymal transection is performed with liver hanging maneuver. Bile duct division after the visualizing planned cutting

point by encircling the bile duct using a radiopaque marker filament under real-time C-arm cholangiography. **Results:** All the procedures have been completed without any extra subcostal incision. All the grafts were safely extracted through the 10-12cm upper midline incisions without any mechanical injury. The median operation duration of hemihepatectomy was 456 minutes. The median amount of blood loss was 520g, and no donors required allogenic transfusion. All the donors have returned to the preoperative activity level. Initial graft function was good in each case. **Conclusion:** LDH by hybrid method with short upper midline incision is a safe and reasonable standardized procedure.

## **Introduction**

The donor safety is utmost important issue in living donor liver transplantation (LDLT). Recently, the applications of less invasive liver surgery in living donor hepatectomy (LDH) have been reported (1, 2). We have adopted laparoscopy-assisted donor hepatectomy through the short upper midline incision with hilar dissection and parenchymal transection under direct vision. In that procedure, we have applied the useful techniques those we have established for the conventional open LDH. We herein describe the procedure of laparoscopic-assisted donor hepatectomy at our institute with the evaluation of the safety and efficacy of the hybrid method with short midline incision in LDH.

## **Patients and Methods**

Between 1997 and August 2011, a total of 150 LDLT were performed at our institution. Among them, recent 15 donors underwent laparoscopy-assisted donor hepatectomy that consisted of two phase of laparoscopic procedure and open procedure that is called hybrid technique (3). With the laparoscopy-assisted procedure, six donors

underwent right hemihepatectomy, and nine donors underwent left hemihepatectomy.

### *Right hemihepatectomy*

The donor was placed in supine position with the arms abducted. Eight cm subxiphoid midline incision was created for hand assistance during the liver mobilization and for graft extraction, using a GelPort hand port device (Applied Medical, CA, USA). Pneumoperitoneum (CO<sub>2</sub> at 8 mmHg) was established through a 5mm umbilical camera port. Once the liver was visualized, one additional 5 mm port was placed at the right flank or through the GelPort (Fig.1). The first assistant who stands on the left side of the donor manipulates the liver for the mobilization of the liver with hand-assist through the hand port. Through the right flank port, the surgeon, who stands on the right side of the donor, use the hook-type electrocautery for dividing ligaments and dissection for sufficient mobilization of the liver until nearby the lateral wall of the inferior vena cava. At this point, the hand port and the other ports were removed. The midline incision was extended up to 12 cm for subsequent open procedure. For a sufficient exposure, the short incision was retracted by Omni-Tract®

(MN, USA). After the exposing the inferior vena cava, dividing short hepatic veins and encircling hepatic veins were performed under direct vision.

Subsequently after the encircling the right hepatic vein, Penrose drain was passed around the hepatic vein for the liver-hanging maneuver. As a result of the sufficient mobilization of the right lobe and using the liver-hanging maneuver, transection line came just beneath the upper midline incision (Fig.2). Parenchymal transection was performed using CUSA<sup>TM</sup> and Tissue Link<sup>TM</sup> dissecting sealer (NH, USA), which was so-called two-surgeon technique (4). We performed bile duct division after the visualizing planned cutting point by encircling the bile duct using a radiopaque marker filament under real-time C-arm cholangiography (5). The resected right lobe was retrieved through the short upper midline incision.

#### *Left hemihepatectomy*

The donor position and the setting of laparoscopic procedure are the same as when right hemihepatectomy. As well as the right hemihepatectomy, during the left hemihepatectomy, the right lobe of the liver should be sufficiently mobilized. Otherwise,

the transection line along Cantlie line is not safely positioned under direct vision through the short upper midline incision. For the dissection of left triangular ligament and the left side of the coronal ligament, 5mm port was placed through the GelPort (Fig.3).

### **Intraoperative and postoperative outcomes**

The median operating time and blood loss were 456 (range 328-581) min and 520 (range 230-1000) g.

The donors were transferred to the surgical intensive care unit for an overnight stay. On postoperative day 1, they were transferred to the nursing ward, with surgical site pain controlled by parenteral analgesics. Donor recovery was uneventful besides one donor who needed relaparotomy for the removal of portal venous thrombus. Serum chemistries were similar to our open donors (data not shown). All donors fully recovered and returned to their previous activities. On follow-up as outpatients, wound healing is favorable in all the donors (Fig. 4).

## Discussion

We herein described 15 cases of donor hemihepatectomy with laparoscopic-assisted donor hemihepatectomy through the short upper midline incision.

Koffron *et al.* reported the first case of a laparoscopic, hand-assisted living donor right hepatic lobectomy using upper midline incision (1). In laparoscopy-assisted LDH at our institute, besides the procedures that Koffron *et al.* reported, we have introduced other techniques those we had established in open procedure.

We consider the dividing short hepatic veins and subsequent encircling the right hepatic vein or the common trunk of middle hepatic vein and left hepatic vein can be more securely performed under direct vision compared to laparoscopic procedure. Minimizing the blood loss is the most important element of laparoscopic liver surgery. Since the retrohepatic vena cava and the hepatic veins can be controlled for urgent extensive bleeding, dissecting those vessels under direct vision seems reasonable approach. Once the right lobe is mobilized, the liver can be rotated to the left of the midline and retracted; therefore, surgeon can easily approach the inferior vena cava and the right hepatic vein even through the mini-laparotomy with short upper midline



incision. Two-surgeon technique during parenchymal transection can be conducted as well as during open procedure with liver hanging maneuver that brings the transection line to just beneath the upper midline incision with pulling up the liver (4). As a result, parenchymal transection can be completed through the 10-12cm upper midline incisions without stress to surgeons.

Visualizing planned cutting point by encircling the bile duct using a radiopaque marker filament contributed to the avoiding biliary complication when dividing bile duct in smaller working space compared to open procedure (5). Depending on the type of graft, we set the different length of incision. We consider 12cm incision is required for safe retrieval of the right lobe graft, and 10cm for the left lobe graft.

In conclusion, LDH by hybrid method with upper midline incision is a safe and reasonable procedure with the combination of effective hand-assist and useful techniques that have been established in the open donor surgery.

## References

1. Koffron AJ, Kung R, Baker T, et al. Laparoscopic-assisted right lobe donor hepatectomy. *Am J Transplant.* 2006;6:2522-5.
2. Wakabayashi G, Nitta H, Takahara T, et al. Standardization of basic skills for laparoscopic liver surgery towards laparoscopic donor hepatectomy. *J Hepatobiliary Pancreat Surg.* 2009;16:439-44.
3. Buell JF, Cherqui D, Geller DA, et al. World Consensus Conference on Laparoscopic Surgery. The international position on laparoscopic liver surgery: The Louisville Statement, 2008. *Ann Surg.* 2009;250:825-30.
4. Takatsuki M, Eguchi S, Yamanouchi K, et al. Two-surgeon technique using saline-linked electric cautery and ultrasonic surgical aspirator in living donor hepatectomy: its safety and efficacy. *Am J Surg.* 2009;197:e25-7.
5. Takatsuki M, Eguchi S, Yamanouchi K, et al. Technical refinements of bile duct division in living donor liver surgery. *J Hepatobiliary Pancreat Sci.* 2011;18:170-5.

### **Figure legends**

**Fig.1** Trocar placement for laparoscopy-assisted donor hemihepatectomy. A 5mm camera port was placed at the umbilicus. Eight cm upper midline incision is made for setting Gel Port handport device for hand-assisted mobilization of the liver.

**Fig.2** Demarcation line appearance after the clamping the right hepatic artery and right branch of the portal vein. After the mobilization of the right liver, transection line comes just beneath the short upper midline incision with liver hanging maneuver.

**Fig.3** For dissection of the left triangular ligament and left side of coronal ligament, 5 mm trocar is placed through the GelPort hand port device.

**Fig.4** Wound of the upper midline 10 cm incision 1 month after the left hemihepatectomy. The wound of umbilical port became nearly invisible.

Fig. 1

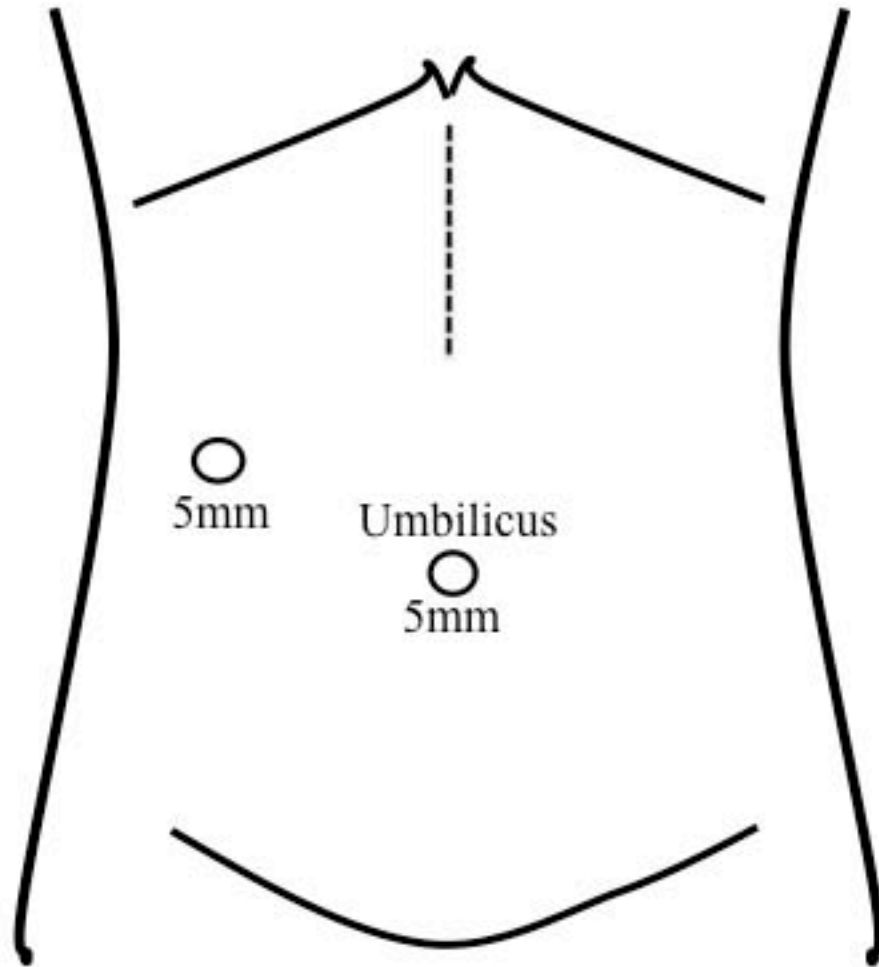


Fig. 2

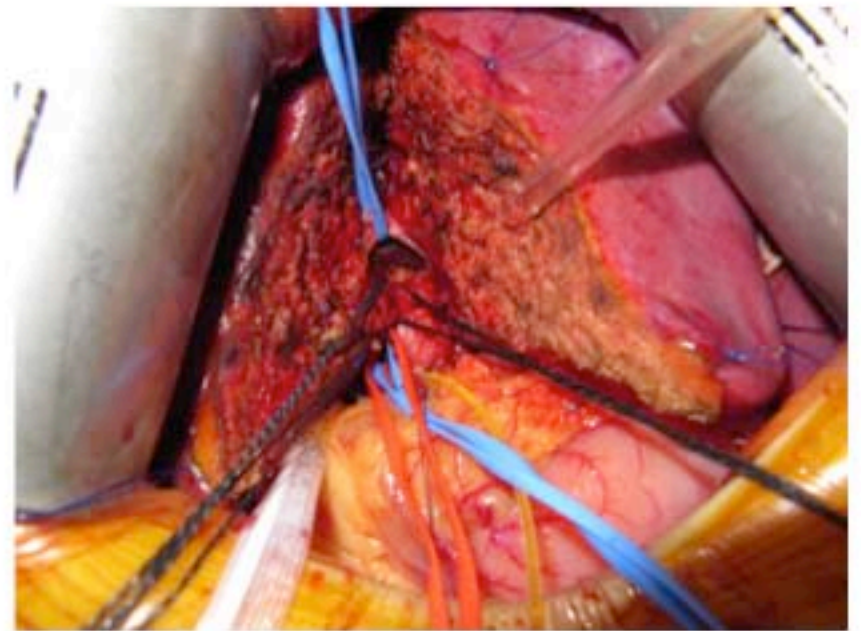
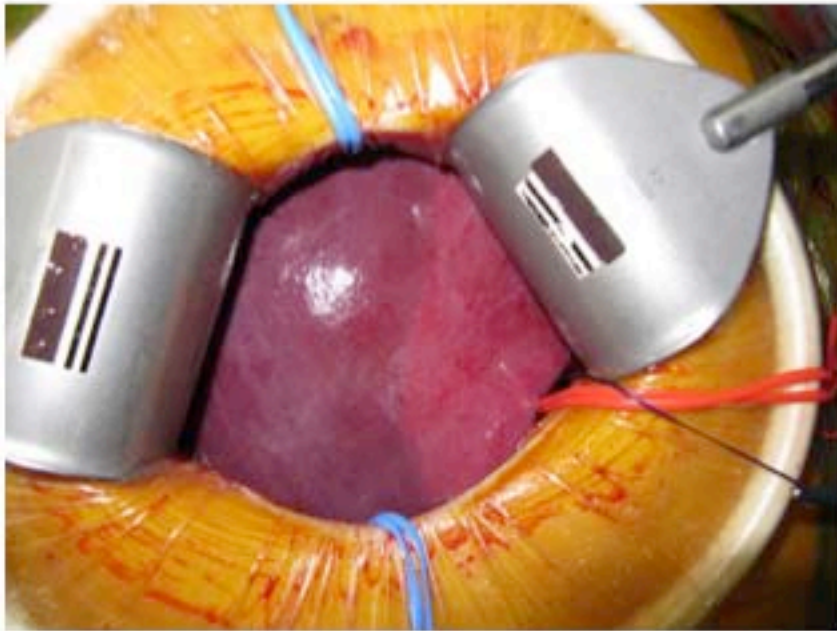


Fig. 3

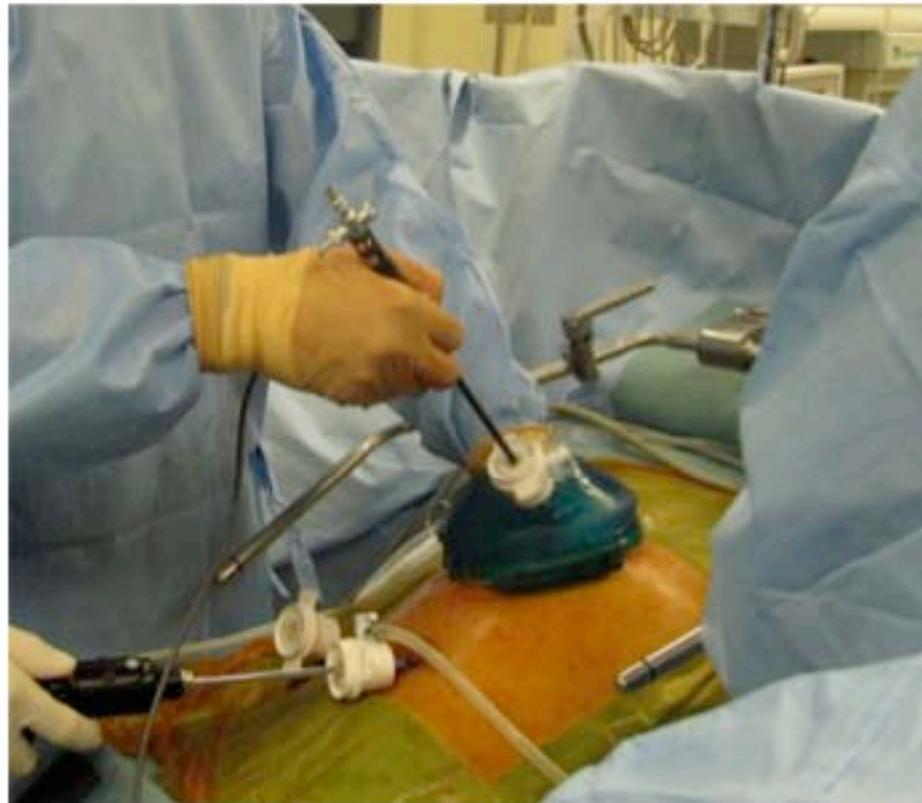

Fig. 4

