

Matsumoto et al. Succinate increases in vitreous fluid of active PDR patients.

Succinate increases in the vitreous fluid of patients with active proliferative diabetic retinopathy

Makiko Matsumoto¹⁾; Kiyoshi Suzuma¹⁾; Toshihide Maki²⁾; Hirofumi Kinoshita¹⁾; Eiko Tsuike¹⁾; Azusa Fujikawa¹⁾; and Takashi Kitaoka¹⁾

¹⁾Department of Ophthalmology and Visual Sciences, Graduate School of Biomedical Sciences, Nagasaki University, 1-7-1 Sakamoto, Nagasaki 852-8501, Japan

²⁾Nagasaki University Joint Research Center, Nagasaki University, 1-14 Bunkyo, Nagasaki 852-8521, Japan

Correspondence to: Kiyoshi Suzuma, MD, PhD
Department of Ophthalmology and Visual Sciences, Graduate School of Biomedical Sciences, Nagasaki University
1-7-1 Sakamoto, Nagasaki 852-8501, Japan
Fax: 011-81-95-819-7347; Tel: 011-8195-819-7345
E-mail: suzuma@nagasaki-u.ac.jp

Running head: Succinate increases in vitreous fluid of active PDR patients

Short title: Succinate increases in vitreous fluid of active PDR patients

Abstract

Purpose: To examine vitreous succinate levels from proliferative diabetic retinopathy (PDR) patients and ascertain their association with PDR activity.

Design: Comparative case series.

Methods: A total of 81 eyes of 72 PDR patients were divided into: active PDR (22 eyes), quiescent PDR (21 eyes), and active PDR with intravitreal bevacizumab injection (38 eyes). Twenty epiretinal membrane (ERM) patients (21 eyes) served as controls.

Results: Mean vitreous succinate levels were 1.27 μ M in ERM and 2.20 μ M in PDR, with the differences statistically significant ($P=0.03$). When comparing mean vitreous succinate levels (active PDR: 3.32, quiescent PDR: 1.02, and active PDR with intravitreal bevacizumab injection: 1.20 μ M), significant differences were found between active and quiescent PDR ($P < 0.01$), and between active PDR and active PDR with intravitreal bevacizumab injection ($P < 0.01$). Even though succinate levels were low, retinopathy activities were very high in patients with active PDR with intravitreal bevacizumab injection. Mean vitreous VEGF levels (active PDR: 1696 pg/ml, quiescent PDR: 110 pg/ml, and active PDR with intravitreal bevacizumab injection: n.d.) were similar to previous reports. Mean vitreous erythropoietin levels (active PDR: 703, quiescent PDR: 305, active PDR with intravitreal bevacizumab injection: 1562 mIU/ml) suggested very high retinopathy activities in patients with active PDR with intravitreal bevacizumab injection.

Conclusions: Succinate, like VEGF, may be an angiogenic factor that is induced by ischemia in PDR. Although succinate is reported to promote VEGF expression, VEGF inhibition decreases succinate. Thus, VEGF, via a positive feedback mechanism, may regulate succinate.

246 words /250 words

Matsumoto et al. Succinate increases in vitreous fluid of active PDR patients.

Intraocular neovascularization is the common final pathway in proliferative diabetic retinopathy (PDR) and it often results in vitreous hemorrhage, tractional retinal detachment, and neovascular glaucoma.^{1, 2} Vascular endothelial growth factor (VEGF) has long been recognized as the primary mediator of retinal angiogenesis.^{3, 4} Bevacizumab (Avastin; Roche, Reinach, Switzerland) is an anti-VEGF agent that was first used to treat metastatic colorectal cancer.⁵ Previous reports on the intravitreal injection of bevacizumab showed promise in targeting VEGF-implicated intraocular neovascularization that is associated with age-related macular degeneration and diabetic retinopathy.⁶⁻¹⁰ Recently, intravitreal bevacizumab injection has also gained popularity among vitreo-retinal surgeons as an adjunct to vitrectomy in the management of severe PDR.¹¹⁻¹³

Other growth factors and cytokines including angiopoietin-2,¹⁴ insulin-like growth factor-1,¹⁵ erythropoietin,¹⁶ hypoxia-inducible factor,¹⁷ platelet-derived growth factor,¹⁸ fibroblast growth factor-2¹⁹ and hepatocyte growth factor²⁰ have also been demonstrated to be involved in ocular angiogenesis. However, there appear to be additional mediators that might be participating in ocular angiogenesis.

In the ischemic brain, Krebs cycle intermediates, such as succinate, have been found to accumulate during conditions linked to the insufficient oxygen supply.^{21, 22} Recently, Sapieha et al. reported that succinate accumulates in the hypoxic retina of rodents and, via its cognate receptor G_s protein-coupled receptor-91, induces VEGF expression, and potentially mediates vessel growth during both normal retinal development and proliferative ischemic retinopathy.^{23, 24} We are unaware of previous reports on levels of succinate in the human vitreous fluid and aqueous humor.

METHODS

Consecutive patients with PDR and idiopathic epiretinal membrane (ERM) who were treated by pars plana vitrectomy at Nagasaki University Hospital between July 2008 and October 2010 were enrolled in the study. Using a 30-gauge needle, some patients with active PDR received intravitreal injection of bevacizumab (1.25 mg, 0.05 mL) via the pars plana. Injections were performed at 3.5 mm posterior to the limbus and done on days 1-7 (2.69 ± 1.58) prior to the planned vitrectomy. This procedure was performed as an adjunct to the vitrectomy that was used to manage the severe proliferative diabetic retinopathy. Subsequently, samples of undiluted vitreous fluid and aqueous humor were harvested from the eyes of the participating PDR or ERM patients. While none of the patients with ERM had diabetes mellitus, all of the PDR patients had type 2 diabetes. The 9 female and 11 male patients with ERM ($n = 9$ and $n = 12$ eyes, respectively) were 61.7 ± 6.9 years of age (mean \pm standard deviation). The 12 female and 27 male patients with PDR without intravitreal injection of bevacizumab ($n = 14$ and $n = 29$ eyes, respectively) were 65.0 ± 9.7 years of age. Age did not significantly differ between these two groups.

Based on a previously published method,³ we clinically classified PDR without intravitreal bevacizumab injection as being active PDR if there was evidence of perfused, multibranching iridic or preretinal capillaries. When active proliferation had fully regressed or if only non-perfused, gliotic vessels or fibrosis were present, patients were classified as having quiescent PDR without intravitreal bevacizumab injection. The 43 eyes of the 39 patients with PDR without intravitreal bevacizumab injection included 22 from 21 patients with active PDR (51.2%) and 21 from 18 patients with quiescent PDR (48.8%). The indications for vitrectomy in patients with quiescent PDR included established vitreous hemorrhage, cystoids or diffuse macular edema, or tractional retinal detachment with inactive fibrovascular proliferation. The 7 female and 14 male patients with active PDR without intravitreal bevacizumab injection ($n = 7$ and $n = 15$ eyes, respectively) were 65.3 ± 8.4 years of age. The 5 female and 13 male patients with quiescent PDR without intravitreal bevacizumab injection ($n = 7$ and $n = 14$ eyes, respectively) were 64.8 ± 11.2 years of age. The 8 female and 26 male patients with active PDR after intravitreal bevacizumab injection ($n = 10$ and $n = 28$ eyes, respectively) were 55.4 ± 12.1 years of age. The subjects in the group with active PDR with intravitreal bevacizumab injection had a younger average age as compared with the group with active PDR without intravitreal bevacizumab injection and the group with quiescent PDR without intravitreal bevacizumab injection. The younger age of the active PDR with intravitreal bevacizumab injection group was intentional, as the study was also designed to examine the relationship between age and succinate concentration.

In order to remove debris, the vitreous fluid and aqueous humor samples were clarified by centrifugation in sterile tubes at 15,000 rpm for 5 min and then rapidly frozen at -80°C . Corpuscles were separated from blood samples in sterile tubes by centrifugation at 5,000 rpm for 10 min, with the serum then also rapidly frozen at -80°C .

Succinate quantitation using HPLC/MS

We quantified succinate levels in the vitreous fluid, aqueous humor and serum using a previously described selective ion monitoring mode of high-performance liquid chromatography-mass spectrometry (HPLC/MS) with modifications.^{25, 26} The study utilized ion exclusion column chromatography using 0.1% formic acid as the eluent and negative mode detection with electrospray ionization (ESI) mass spectrometry to ensure we achieved optimal performance during the quantification.

Quantitative VEGF and erythropoietin

We measured VEGF and erythropoietin levels in the vitreous fluid using enzyme-linked immunosorbent assays (ELISA) (R&D Systems, Minneapolis, MN, USA).

Statistical analysis

The primary objective of this study was to determine whether succinate is significantly increased in patients with PDR. Levels of succinate were compared in the groups with ERM and with PDR without intravitreal bevacizumab injection using a two-tailed *t* test. A Dunn's test was used to compare the levels of succinate, VEGF and erythropoietin in active PDR without intravitreal bevacizumab injection, quiescent PDR without intravitreal bevacizumab injection and active PDR with intravitreal bevacizumab injection. Levels of succinate were compared in the groups with and without systemic and ocular factors using a two-tailed *t* test. Linear regression analysis (for the levels of succinate and age, and for the levels of succinate and hemoglobin A1c) along with tests of the regression were performed. All statistical analyses were carried out using Statflex ver. 6.0 software (Artech Co., Ltd., Osaka, Japan). Results are expressed as means \pm standard deviation, unless otherwise indicated. P values <0.05 were considered to be statistically significant.

RESULTS

Succinate increases in the vitreous fluid from PDR (active PDR and quiescent PDR) without intravitreal bevacizumab injection

In the first part of our study, we compared succinate levels between the PDR patients and the non-diabetic patients. The mean succinate levels in the vitreous fluid were 1.27 ± 0.86 and 2.20 ± 2.20 μM in the 20 ERM patients ($n = 21$) and in the 39 PDR patients without intravitreal bevacizumab injection ($n = 43$), respectively. The mean vitreous succinate level was significantly elevated in the PDR without intravitreal bevacizumab injection group as compared to the ERM group ($P=0.03$ t test; Figure 1 Top).

Succinate concentrations in the aqueous humor and serum of ERM and PDR (active PDR and quiescent PDR) without intravitreal bevacizumab injection

The mean succinate levels in the aqueous humor from patients with ERM ($n = 17$) and PDR without intravitreal bevacizumab injection ($n = 31$) were 1.94 ± 1.85 and 2.02 ± 1.63 μM , respectively. There were no significant differences noted among the groups (Figure 1 Middle). The mean succinate levels in the serum from patients with ERM ($n = 10$) and PDR without intravitreal bevacizumab injection ($n = 15$) were 1.37 ± 0.73 and 1.15 ± 0.54 μM , respectively. There were no significant differences noted among the groups (Figure 1 Bottom).

Comparison of the vitreous succinate levels in active PDR without intravitreal bevacizumab injection, quiescent PDR without intravitreal bevacizumab injection and active PDR with intravitreal bevacizumab injection

Next, we compared the succinate levels in active PDR without intravitreal bevacizumab injection, quiescent PDR without intravitreal bevacizumab injection and active PDR with intravitreal bevacizumab injection in order to assess their association with PDR activity. The mean succinate levels in the vitreous fluid were 3.32 ± 2.43 , 1.02 ± 1.05 and 1.20 ± 1.47 μM in the 21 patients with active PDR without intravitreal bevacizumab injection ($n = 22$), 18 patients with quiescent PDR without intravitreal bevacizumab injection ($n = 21$) and 34 patients with active PDR with intravitreal bevacizumab injection ($n = 38$), respectively. The mean vitreous succinate level was significantly elevated in active PDR without intravitreal bevacizumab injection when compared to both the quiescent PDR without intravitreal bevacizumab injection ($P < 0.01$, Dunn's test) and active PDR with intravitreal bevacizumab injection ($P < 0.01$, Dunn's test; Figure 2 Top). Surprisingly, there were similar levels noted for quiescent PDR without intravitreal bevacizumab injection and active PDR with intravitreal bevacizumab injection, even though the retinopathy activities were very high for all of the active PDR patients with intravitreal bevacizumab injection.

Succinate concentration in the aqueous humor and serum of the active PDR without intravitreal bevacizumab injection, quiescent PDR without intravitreal bevacizumab injection and active PDR with intravitreal bevacizumab injection

The mean succinate levels in the aqueous humor from the active PDR without intravitreal bevacizumab injection (n = 13), quiescent PDR without intravitreal bevacizumab injection (n = 15) and active PDR with intravitreal bevacizumab injection (n = 31) patients were 2.10 ± 1.73 , 2.08 ± 1.51 and 1.00 ± 0.93 μM , respectively. The aqueous humor succinate level in active PDR without intravitreal bevacizumab injection tended to be higher than that seen in the active PDR with intravitreal bevacizumab injection, although this difference was not statistically significant (Figure 2 Middle).

The mean succinate levels in the serum of the active PDR without intravitreal bevacizumab injection (n = 9), quiescent PDR without intravitreal bevacizumab injection (n = 6) and active PDR with intravitreal bevacizumab injection (n = 20) patients were 1.30 ± 0.59 , 0.93 ± 0.42 and 1.10 ± 1.02 μM , respectively. There were no significant differences found among these groups (Figure 2 Bottom).

VEGF and erythropoietin concentrations in vitreous fluid of active PDR without intravitreal bevacizumab injection, quiescent PDR without intravitreal bevacizumab injection and active PDR with intravitreal bevacizumab injection

To confirm the retinopathy activities of the PDR patients, we examined VEGF and erythropoietin concentrations in the vitreous fluid. While the VEGF vitreous levels were 1695 ± 1955 pg/ml in the active PDR patients without intravitreal bevacizumab injection (n = 22) and 110 ± 149 pg/ml in the quiescent PDR patients without intravitreal bevacizumab injection (n = 20), all of the active PDR patients with intravitreal bevacizumab injection (n = 10) had levels that were below the limits of detection, similar to that which has been previously reported.^{3, 27, 28} The mean vitreous VEGF level was significantly elevated in active PDR without intravitreal bevacizumab injection when compared to both quiescent PDR without intravitreal bevacizumab injection ($P < 0.01$, Dunn's test) and active PDR with intravitreal bevacizumab injection ($P < 0.01$, Dunn's test; Figure 3 Top). Similar to the results reported in a previous study,¹⁶ the mean erythropoietin vitreous levels were 703 ± 669 and 305 ± 244 mIU/ml in active PDR without intravitreal bevacizumab injection (n = 19) and quiescent PDR without intravitreal bevacizumab injection (n = 20), respectively. In contrast, the levels in active PDR with intravitreal bevacizumab injection (n = 15) were 1562 ± 2167 mIU/ml (Figure 3 Bottom). This indicates that the retinopathy activities were very high in the active PDR patients with intravitreal bevacizumab injection. We evaluated correlations among succinate, VEGF, and erythropoietin, and determined there was a significant correlation between the vitreous concentrations of succinate and the VEGF in the 32 eyes of the PDR patients without intravitreal bevacizumab injection (Spearman correlation coefficient, $r_s = 0.380$, $P = 0.0318$). We found no significant relationships between the vitreous concentrations of succinate and erythropoietin in the 29 eyes of the

PDR patients without intravitreal bevacizumab injection (Spearman correlation coefficient, $r_s = 0.045$). However, the relationship between the vitreous concentration of VEGF and erythropoietin in the 29 eyes of the PDR patients without intravitreal bevacizumab injection was statistically significant (Spearman correlation coefficient, $r_s = 0.518$, $P < 0.01$).

Analysis of the correlation between the vitreous succinate and the systemic or ocular factors in PDR patients without intravitreal bevacizumab injection

In the PDR patients, there was no correlation found between either the succinate levels and age ($P=0.69$, $r=-0.06$ linear regression analysis) or the succinate levels and hemoglobin A1c ($P=0.39$, $r=-0.14$ linear regression analysis). The succinate levels of the vitreous fluid were 2.35 ± 2.02 in females ($n = 15$) and 2.11 ± 2.32 in males ($n = 28$) with PDR ($P=0.73$ *t* test). The level in the PDR patients with phakia ($n = 33$) was 2.34 ± 2.43 , while it was 1.69 ± 1.04 in the pseudophakia patients ($n = 10$) ($P=0.23$ *t* test), respectively. The succinate levels of the vitreous fluid in the PDR patients with ($n = 30$) and without ($n = 12$) hypertension were 2.22 ± 2.17 and 2.29 ± 2.40 μM ($P=0.93$ *t* test). In PDR patients with ($n = 7$) and without ($n = 33$) ischemic disease (cardiovascular disease or cerebral infarction), succinate levels of the vitreous fluid were 3.06 ± 2.94 and 2.01 ± 2.03 μM ($P=0.36$ *t* test), while in PDR patients with ($n = 4$) and without ($n = 38$) malignancy, succinate levels of the vitreous fluid were 2.87 ± 0.63 and 2.17 ± 2.31 μM ($P=0.17$ *t* test), respectively. No statistically significant correlations were observed for these independent factors (age, gender, form of crystalline lens, glycosylated hemoglobin and systemic factors).

DISCUSSION

The present findings demonstrated that as compared to the ERM patients, there were significantly higher succinate levels in the vitreous fluid of the PDR patients without intravitreal bevacizumab injection. The concentrations of vitreous succinate were significantly correlated with the vitreous VEGF. There were no significant differences found for the aqueous humor or serum succinate levels between the ERM patients and the PDR patients without intravitreal bevacizumab injection. Serum succinate concentrations were lower than those noted in the vitreous fluid and aqueous humor. Folbergrova and Hoyer have reported that during conditions linked with insufficient oxygen supply to the rat cerebral cortex, succinate accumulates as an end product of anaerobic glucose catabolism.^{21, 22} In addition, accumulation of succinate also occurs extracellularly in the peripheral tissues during specific pathophysiological states when the energy and oxygen supply/demand are unbalanced.²⁹ Toma et al. have also demonstrated there is succinate accumulation in diabetic kidney tissues and in the urine.³⁰ Their results suggested that hyperglycemia is associated with further, remarkable reductions in renal oxygen tension and mitochondrial respiration.³¹ Thus, not only ischemia but also hyperglycemia might be indirectly responsible for the increased succinate concentrations. We found the succinate concentrations in PDR patients to be the highest in the vitreous fluid, slightly increased in the aqueous humor, and lowest in the serum. Theoretically, succinate in the blood does not necessarily reach the vitreous, but instead accumulates in tissues where the oxygen supply is insufficient. As such, this would mean that in PDR patients, succinate might accumulate in the retina, and not in either the corneal endothelium or the iris.

Based on a previously reported classification method, we used the patient's clinical records to divide the PDR into active PDR without intravitreal bevacizumab injection or quiescent PDR without intravitreal bevacizumab injection.³ The average VEGF and erythropoietin values found for the PDR, active PDR without intravitreal bevacizumab injection and quiescent PDR without intravitreal bevacizumab injection in the current study were similar to those that have been previously reported.¹⁶ Thus, this suggests that our classification system was satisfactory. In our study, the mean vitreous succinate levels were significantly elevated in active PDR without intravitreal bevacizumab injection when compared to both quiescent PDR without intravitreal bevacizumab injection and active PDR with intravitreal bevacizumab injection. Since the succinate levels with active PDR without intravitreal bevacizumab injection were significantly higher as compared to quiescent PDR without intravitreal bevacizumab injection, we theorized that there might be a correlation between the succinate level and the activity of PDR. Surprisingly, succinate levels in active PDR with intravitreal bevacizumab injection were low, even though the retinopathy activities were very high in all of the patients with active PDR with intravitreal bevacizumab injection. Thus, although it has been reported that succinate promotes expression of VEGF, the current findings suggest that VEGF might also control succinate levels in the vitreous fluid.²³ This study was intentionally designed so that the average age of the active PDR patients with

intravitreal bevacizumab injection would be younger than that of either the active or quiescent PDR patients without intravitreal bevacizumab injection. This made it possible to examine the correlation between the succinate level and age in the PDR patients without intravitreal bevacizumab injection. However, we found that there was no relationship between succinate levels and age. In addition, we also did not find any factors (age, gender, form of crystalline lens, glycosylated hemoglobin and systemic factors) in this study that appeared to affect the succinate levels.

Watanabe et al.¹⁶ reported that erythropoietin is a potent ischemia-induced angiogenic factor that acts independently of VEGF during retinal angiogenesis in PDR. In addition, this previous study also showed that erythropoietin was more closely associated with proliferative diabetic retinopathy than VEGF. Similarly, there was also a significant positive correlation in our cases between the vitreous concentration of VEGF and erythropoietin in the PDR patients without intravitreal bevacizumab injection. Since immunoreactivity of VEGF was inhibited after the intravitreal bevacizumab injection, it was not possible for VEGF to be a marker of the retinopathy activity. In contrast, we do believe that erythropoietin could very well be a marker for retinopathy activity after intravitreal bevacizumab injection. The average erythropoietin vitreous fluid level in active PDR with intravitreal bevacizumab injection was found to be quite a bit higher than that which was observed for the active PDR without intravitreal bevacizumab injection in the current study. Therefore, we can speculate that retinopathy activity was quite high in the active PDR with intravitreal bevacizumab injection group, even though the succinate level was significantly lower than that seen in the active PDR without intravitreal bevacizumab injection group. Based on the overall findings, it would also be expected that the succinate level should fall after intravitreal bevacizumab injection.

Like VEGF, succinate might function in proliferative diabetic retinopathy as an ischemia-induced angiogenic factor during retinal angiogenesis.²³ This is supported by our findings, which demonstrated that the succinate levels also fell when the VEGF was inhibited by intravitreal bevacizumab injection. Since succinate has been reported to induce VEGF expression,²³ overall, our findings might very well indicate the existence of a positive feedback mechanism between succinate and VEGF. To definitively clarify this speculation, further studies will need to be undertaken.

ACKNOWLEDGMENTS/DISCLOSURE

a. Funding/Support

This study was supported by Grants-in-Aid for Scientific Research from the Ministry of Education, Science, and Culture (21592234, 21592235), by the Japan National Society for the Prevention of Blindness, and by the Takeda Science Foundation.

b. Financial Disclosures: No conflicting relationship exists for any of the authors.

c. Author Contributions:

Design and conduct of the study: (MM, KS, TK).

Collection, management, analysis, and interpretation of the data: (MM, KS, TM, HK, ET, AF, TK).

Preparation, review, or approval of the manuscript: (MM, KS).

d. This study was prospectively approved by the Institutional Review Committee of Nagasaki University and was performed in accordance with the Declaration of Helsinki. Informed consent was obtained from all patients prior to their participation in the study.

e. Other Acknowledgments: none.

REFERENCES

1. Moss SE, Klein R, Klein BE. The 14-year incidence of visual loss in a diabetic population. *Ophthalmology* 1998;105(6):998-1003.
2. Fong DS, Ferris FL, 3rd, Davis MD, Chew EY. Causes of severe visual loss in the early treatment diabetic retinopathy study: ETDRS report no. 24. Early Treatment Diabetic Retinopathy Study Research Group. *Am J Ophthalmol* 1999;127(2):137-41.
3. Aiello LP, Avery RL, Arrigg PG, et al. Vascular endothelial growth factor in ocular fluid of patients with diabetic retinopathy and other retinal disorders. *N Engl J Med* 1994;331(22):1480-1487.
4. Aiello LP. Vascular endothelial growth factor and the eye: biochemical mechanisms of action and implications for novel therapies. *Ophthalmic Res* 1997;29(5):354-362.
5. Hurwitz H, Fehrenbacher L, Novotny W, et al. Bevacizumab plus irinotecan, fluorouracil, and leucovorin for metastatic colorectal cancer. *N Engl J Med* 2004;350(23):2335-2342.
6. Avery RL, Pieramici DJ, Rabena MD, Castellarin AA, Nasir MA, Giust MJ. Intravitreal bevacizumab (Avastin) for neovascular age-related macular degeneration. *Ophthalmology* 2006;113(3):363-372 e5.
7. Michels S, Rosenfeld PJ, Puliafito CA, Marcus EN, Venkatraman AS. Systemic bevacizumab (Avastin) therapy for neovascular age-related macular degeneration twelve-week results of an uncontrolled open-label clinical study. *Ophthalmology* 2005;112(6):1035-1047.
8. Minnella AM, Savastano CM, Ziccardi L, Scupola A, Falsini B, Balestrazzi E. Intravitreal bevacizumab (Avastin) in proliferative diabetic retinopathy. *Acta Ophthalmol* 2008;86(6):683-687.
9. Avery RL, Pearlman J, Pieramici DJ, et al. Intravitreal bevacizumab (Avastin) in the treatment of proliferative diabetic retinopathy. *Ophthalmology* 2006;113(10):1695 e1-15.
10. Spaide RF, Fisher YL. Intravitreal bevacizumab (Avastin) treatment of proliferative diabetic retinopathy complicated by vitreous hemorrhage. *Retina* 2006;26(3):275-278.
11. Chen E, Park CH. Use of intravitreal bevacizumab as a preoperative adjunct for tractional retinal detachment repair in severe proliferative diabetic retinopathy. *Retina* 2006;26(6):699-700.
12. di Lauro R, De Ruggiero P, di Lauro MT, Romano MR. Intravitreal bevacizumab for surgical treatment of severe proliferative diabetic retinopathy. *Graefes Arch Clin Exp Ophthalmol* 2010;248(6):785-791.
13. Rizzo S, Genovesi-Ebert F, Di Bartolo E, Vento A, Miniaci S, Williams G. Injection of intravitreal bevacizumab (Avastin) as a preoperative adjunct before vitrectomy surgery in the treatment of severe proliferative diabetic retinopathy (PDR). *Graefes Arch Clin Exp Ophthalmol* 2008;246(6):837-842.
14. Watanabe D, Suzuma K, Suzuma I, et al. Vitreous levels of angiopoietin 2

Matsumoto et al. Succinate increases in vitreous fluid of active PDR patients.

- and vascular endothelial growth factor in patients with proliferative diabetic retinopathy. *Am J Ophthalmol* 2005;139(3):476-481.
15. Smith LE, Kopchick JJ, Chen W, et al. Essential role of growth hormone in ischemia-induced retinal neovascularization. *Science* 1997;276(5319):1706-1709.
 16. Watanabe D, Suzuma K, Matsui S, et al. Erythropoietin as a retinal angiogenic factor in proliferative diabetic retinopathy. *N Engl J Med* 2005;353(8):782-792.
 17. Arjamaa O, Nikinmaa M. Oxygen-dependent diseases in the retina: role of hypoxia-inducible factors. *Exp Eye Res* 2006;83(3):473-483.
 18. Enge M, Bjarnegard M, Gerhardt H, et al. Endothelium-specific platelet-derived growth factor-B ablation mimics diabetic retinopathy. *EMBO J* 2002;21(16):4307-4316.
 19. D'Amore PA. Mechanisms of retinal and choroidal neovascularization. *Invest Ophthalmol Vis Sci* 1994;35(12):3974-3979.
 20. Cai W, Rook SL, Jiang ZY, Takahara N, Aiello LP. Mechanisms of hepatocyte growth factor-induced retinal endothelial cell migration and growth. *Invest Ophthalmol Vis Sci* 2000;41(7):1885-1893.
 21. Folbergrova J, Ljunggren B, Norberg K, Siesjo BK. Influence of complete ischemia on glycolytic metabolites, citric acid cycle intermediates, and associated amino acids in the rat cerebral cortex. *Brain Res* 1974;80(2):265-279.
 22. Hoyer S, Krier C. Ischemia and aging brain. Studies on glucose and energy metabolism in rat cerebral cortex. *Neurobiol Aging* 1986;7(1):23-29.
 23. Sapieha P, Sirinyan M, Hamel D, et al. The succinate receptor GPR91 in neurons has a major role in retinal angiogenesis. *Nat Med* 2008;14(10):1067-1076.
 24. He W, Miao FJ, Lin DC, et al. Citric acid cycle intermediates as ligands for orphan G-protein-coupled receptors. *Nature* 2004;429(6988):188-193.
 25. Gamoh K, Saitoh H, Wada H. Improved liquid chromatography/mass spectrometric analysis of low molecular weight carboxylic acids by ion exclusion separation with electrospray ionization. *Rapid Commun Mass Spectrom* 2003;17(7):685-689.
 26. Bylund D, Norstrom SH, Essen SA, Lundstrom US. Analysis of low molecular mass organic acids in natural waters by ion exclusion chromatography tandem mass spectrometry. *J Chromatogr A* 2007;1176(1-2):89-93.
 27. Forooghian F, Kertes PJ, Eng KT, Agron E, Chew EY. Alterations in the intraocular cytokine milieu after intravitreal bevacizumab. *Invest Ophthalmol Vis Sci* 2010;51(5):2388-2392.
 28. Matsuyama K, Ogata N, Matsuoka M, Wada M, Takahashi K, Nishimura T. Plasma levels of vascular endothelial growth factor and pigment epithelium-derived factor before and after intravitreal injection of bevacizumab. *Br J Ophthalmol* 2010;94(9):1215-1218.
 29. Hebert SC. Physiology: orphan detectors of metabolism. *Nature* 2004;429(6988):143-145.
 30. Toma I, Kang JJ, Sipos A, et al. Succinate receptor GPR91 provides a direct link between high glucose levels and renin release in murine and rabbit kidney. *J*

Matsumoto et al. Succinate increases in vitreous fluid of active PDR patients.

Clin Invest 2008;118(7):2526-2534.

31. Palm F. Intrarenal oxygen in diabetes and a possible link to diabetic nephropathy. Clin Exp Pharmacol Physiol 2006;33(10):997-1001.

Figure legends

FIGURE 1. Mean succinate levels in the vitreous fluid, aqueous humor and serum of patients with ERM and PDR (active PDR and quiescent PDR) without intravitreal bevacizumab injection.

The mean succinate levels in the vitreous fluid were 1.27 ± 0.86 and 2.20 ± 2.20 μM in the 20 ERM patients ($n = 21$) and in the 39 PDR patients without intravitreal bevacizumab injection ($n = 43$), respectively. The mean vitreous succinate level was significantly elevated in PDR patients without intravitreal bevacizumab injection as compared to the ERM group (\times $P=0.03$, t test) (Top).

The mean succinate levels in the aqueous humor were 1.94 ± 1.85 and 2.02 ± 1.63 μM in the ERM patients ($n = 17$) and in the PDR patients without intravitreal bevacizumab injection ($n = 31$), respectively. There were no significant differences noted among the groups (Middle).

The mean succinate levels in the serum were 1.37 ± 0.73 and 1.15 ± 0.54 μM in the ERM patients ($n = 10$) and in the PDR patients without intravitreal bevacizumab injection ($n = 15$), respectively. There were no significant differences noted among the groups (Bottom).

Matsumoto et al. Succinate increases in vitreous fluid of active PDR patients.

FIGURE 1.

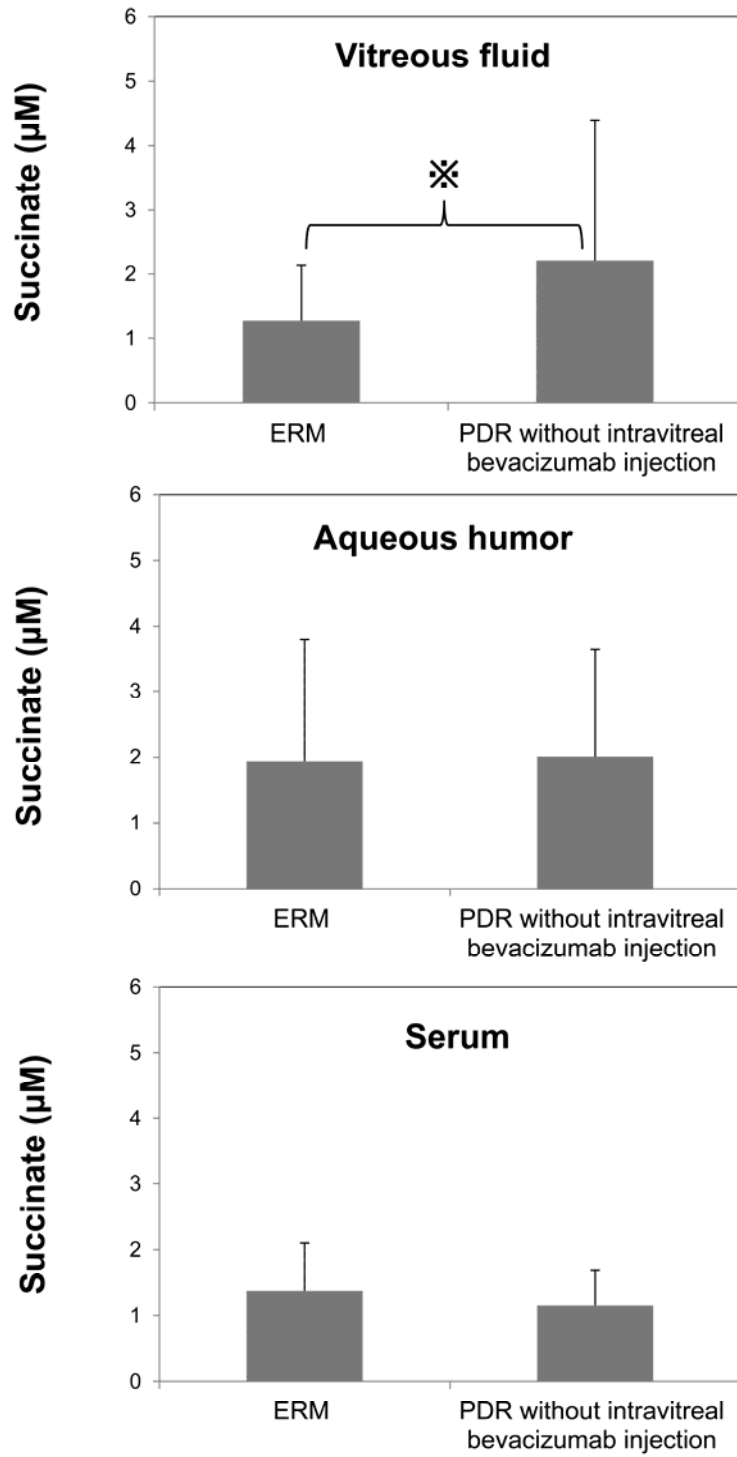


FIGURE 2. Mean succinate levels in the vitreous fluid, aqueous humor and serum of the active PDR patients without intravitreal bevacizumab injection, quiescent PDR patients without intravitreal bevacizumab injection and active PDR patients with intravitreal bevacizumab injection.

The mean succinate levels in the vitreous fluid were $3.32 \pm 2.43 \mu\text{M}$ in the 21 active PDR patients without intravitreal bevacizumab injection ($n = 22$), $1.02 \pm 1.05 \mu\text{M}$ in the 18 quiescent PDR patients without intravitreal bevacizumab injection ($n = 21$) and $1.20 \pm 1.47 \mu\text{M}$ in the 34 active PDR patients with intravitreal bevacizumab injection ($n = 38$). The mean vitreous succinate level was significantly elevated in the active PDR without intravitreal bevacizumab injection group when compared to both quiescent PDR without intravitreal bevacizumab injection ($\times\times P < 0.01$, Dunn's test) and active PDR with intravitreal bevacizumab injection ($\times\times P < 0.01$, Dunn's test) (Top). The mean succinate levels in the aqueous humor were 2.10 ± 1.73 , 2.08 ± 1.51 and $1.00 \pm 0.93 \mu\text{M}$ in active PDR without intravitreal bevacizumab injection ($n = 13$), quiescent PDR without intravitreal bevacizumab injection ($n = 15$) and active PDR with intravitreal bevacizumab injection ($n = 31$), respectively. The aqueous humor succinate level in active PDR without intravitreal bevacizumab injection tended to be higher than that seen in active PDR with intravitreal bevacizumab injection, although this difference was not statistically significant (Middle).

The mean succinate levels in serum were 1.30 ± 0.59 , 0.93 ± 0.42 and $1.10 \pm 1.02 \mu\text{M}$ in active PDR without intravitreal bevacizumab injection ($n = 9$), quiescent PDR without intravitreal bevacizumab injection ($n = 6$) and active PDR with intravitreal bevacizumab injection ($n = 20$), respectively. There were no significant differences found among these groups (Bottom).

FIGURE 2.

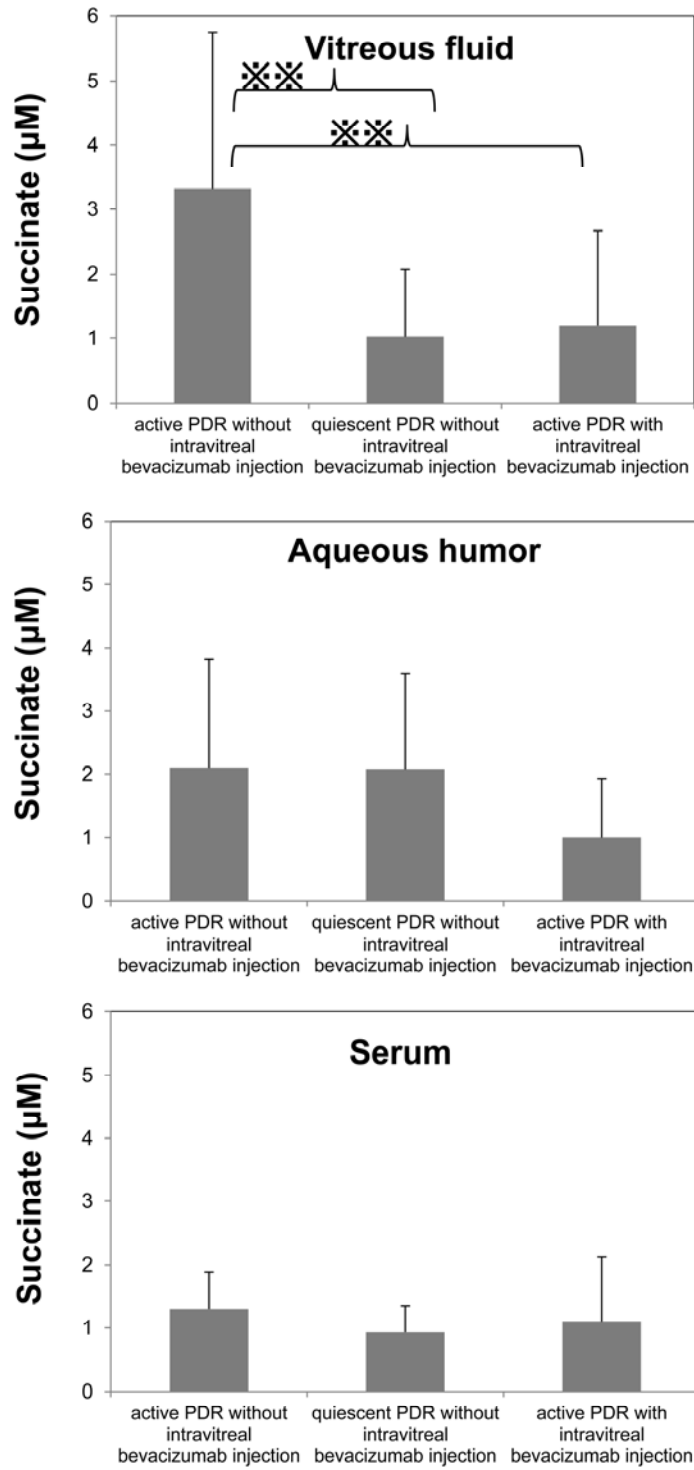


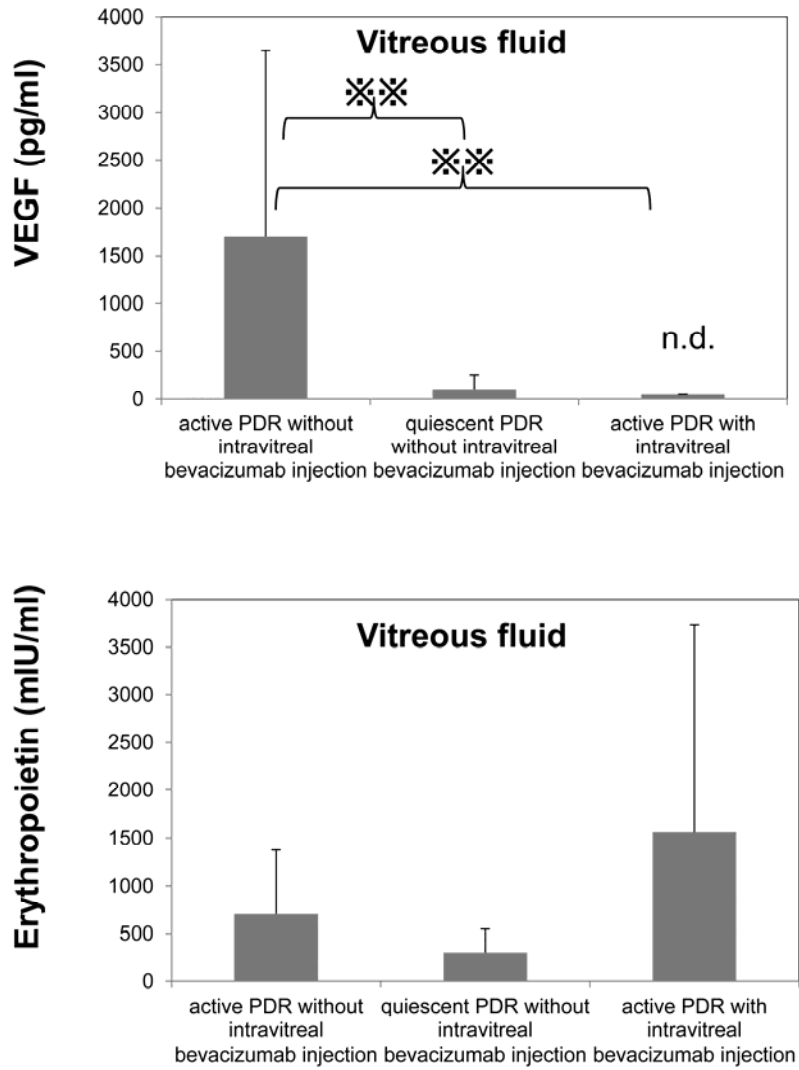
FIGURE 3. Concentrations of VEGF and erythropoietin in vitreous fluid from patients with active PDR without intravitreal bevacizumab injection, quiescent PDR without intravitreal bevacizumab injection and active PDR with intravitreal bevacizumab injection.

While the VEGF vitreous levels were 1695 ± 1955 pg/ml in the active PDR patients without intravitreal bevacizumab injection ($n = 22$) and 110 ± 149 pg/ml in the patients with quiescent PDR ($n = 20$), levels were below the limits of detection in all of the active PDR patients with intravitreal bevacizumab injection ($n = 10$). The mean vitreous VEGF level was significantly elevated in active PDR without intravitreal bevacizumab injection when compared to both quiescent PDR without intravitreal bevacizumab injection ($P < 0.01$, Dunn's test) and active PDR with intravitreal bevacizumab injection ($P < 0.01$, Dunn's test) (Top).

The mean erythropoietin vitreous levels were 703 ± 669 , 305 ± 244 and 1562 ± 2167 mIU/ml in active PDR without intravitreal bevacizumab injection ($n = 19$), quiescent PDR without intravitreal bevacizumab injection ($n = 20$) and active PDR with intravitreal bevacizumab injection, respectively, (Bottom).

Matsumoto et al. Succinate increases in vitreous fluid of active PDR patients.

FIGURE 3.



Title: Succinate increases in the vitreous fluid of patients with active proliferative diabetic retinopathy

Manuscript number: AJO-11-624

Table of Contents Statement

Mean vitreous succinate levels with proliferative diabetic retinopathy were significantly higher than those in epiretinal membrane. In proliferative diabetic retinopathy, significant differences were found both between active retinopathy without intravitreal bevacizumab injection and quiescent retinopathy, and between active retinopathy without intravitreal bevacizumab injection and active retinopathy with intravitreal bevacizumab injection. Succinate may be an angiogenic factor. Vascular endothelial growth factor inhibition decreases succinate. Thus, vascular endothelial growth factor may regulate succinate.

71 words /75 words