

Title: HSP47 in lung fibroblasts is a predictor of survival in fibrotic nonspecific interstitial pneumonia

Running title: HSP47 in fibrotic NSIP

**Abstract (223/250 words)**

**Background:** The histopathologic pattern is currently the most important prognostic marker for idiopathic interstitial pneumonia (IIP). However, more highly sensitive markers are now required. Heat shock protein (HSP) 47, a collagen-specific molecular chaperone, is involved in the processing and/or secretion of procollagens, and it has been demonstrated that HSP47 expression is significantly higher in the lung specimens of idiopathic UIP than in UIP associated with collagen vascular diseases (CVD). However, its expression in nonspecific interstitial pneumonia (NSIP), the other common pathological pattern of IIP, has not been well investigated. Therefore, the association between lung fibroblast HSP47 expression and prognosis in fibrotic NSIP was evaluated.

**Methods:** Surgical lung biopsy specimens of 63 patients [idiopathic fibrotic NSIP = 19, fibrotic NSIP associated with CVD = 9, idiopathic UIP = 26, and UIP associated with CVD = 9] were reviewed, and a score for lung fibroblast HSP47 expression was assigned. These patients' clinical features and survival were also analyzed.

**Results:** There was no significant difference in HSP47 expression between idiopathic fibrotic NSIP and fibrotic NSIP associated with CVD. The idiopathic fibrotic NSIP patients with higher HSP47 expression levels in their lung specimens had a poorer prognosis than patients with lower HSP47 expression levels.

**Conclusions:** The present results suggest that lung fibroblast HSP47 expression may be a useful new prognostic marker for idiopathic fibrotic nonspecific interstitial pneumonia.

## **Introduction**

Idiopathic interstitial pneumonia (IIP) is currently classified into seven clinico-radiologic-pathologic entities, which differ not only in pathology but also in their clinical features.<sup>1</sup> Of these, the majority of IIP cases are nonspecific interstitial pneumonia (NSIP) and usual interstitial pneumonia (UIP). Idiopathic NSIP (I-NSIP) has been reported to have a more favorable prognosis and a better response to steroids than idiopathic pulmonary fibrosis (idiopathic UIP; I-UIP),<sup>2-5</sup> suggesting that the pathogenesis of I-NSIP is different from that of I-UIP. In addition, whether I-NSIP is a distinct entity remains controversial because the reported survival rates of I-NSIP patients are variable,<sup>2, 4-8</sup> and NSIP has a close relationship with collagen vascular disease (CVD).<sup>7, 9</sup> Though the most common pathological patterns in interstitial pneumonia associated with CVD (CVD-IP) are also NSIP and UIP, patients with CVD-IP have been reported to have a better prognosis than patients with IIP.<sup>4, 10</sup> In this context, Flaherty et al<sup>10</sup> reported that patients with CVD-associated UIP (CVD-UIP) have fewer fibroblastic foci in the lung than those with I-UIP. However, the phenotypic difference in lung cells between these diseases and its association with the prognosis are poorly understood.

Heat shock protein 47 (HSP47), localized in the endoplasmic reticulum, is involved in the synthesis/assembly of various collagens as a collagen-specific molecular chaperone. HSP47 expression is regulated in parallel with collagen expression, and HSP47 overexpression leads to production of excess extracellular matrix, which then results in various fibrotic diseases.<sup>11-13</sup> We have previously reported that HSP47 was strongly expressed in the lung cells of patients with I-UIP,<sup>14</sup> and that the HSP47 expression level in lung cells was significantly higher in I-UIP than in CVD-UIP.<sup>13</sup> These findings suggest that

I-UIP and CVD-UIP have different fibrotic pathways, and that HSP47 expression may be a good predictor of prognosis in patients with fibrotic IP.

Therefore, in this study, the expression of HSP47 in lung fibroblasts was examined in fibrotic IP, including fibrotic I-NSIP (I-fNSIP), fibrotic CVD-NSIP (CVD-fNSIP), I-UIP and CVD-UIP, to evaluate the usefulness of HSP47 as a prognostic marker.

## **Materials and Methods**

### ***Study populations***

The subjects of this study were patients who attended the Nagasaki University Hospital between 1991 and 2007. The study protocol was approved by the human ethics review committees of Nagasaki University School of Medicine, and written, informed consent was obtained from each patient. The subjects included 63 patients (45 with IIP and 18 with CVD-IP) diagnosed based on surgical lung biopsy as fNSIP pattern (19 with I-fNSIP, 9 with CVD-fNSIP) or UIP pattern (26 with I-UIP, and 9 with CVD-UIP) according to the consensus criteria of the American Thoracic Society/European Respiratory Society.<sup>1</sup> None of the patients were pathologically diagnosed as having cellular-NSIP. The associated diagnoses in the CVD-fNSIP patients were rheumatoid arthritis (n=1), mixed connective tissue disease (MCTD; n = 1), systemic sclerosis (SSc; n = 2), dermatomyositis (DM; n = 4), and DM + Sjögren syndrome (SjS; n=1). The associated diagnoses in the CVD-UIP patients were MCTD (n = 1), SjS (n = 3), SSc (n = 3), DM + SjS (n=1), and SSc + SjS (n=1). The mean follow-up period after the surgical lung biopsy was  $69.6 \pm 5.8$  (range: 1-195) months. None of the patients had received steroids or other immunosuppressive therapies when the surgical lung biopsy was performed. Patients' data before surgical lung biopsy, including age, smoking history, results of pulmonary function tests, arterial blood gas analysis, and bronchoalveolar lavage fluid (BALF) findings, were collected from the hospital medical records (Table 1,2). Control lung tissues were obtained from normal areas of surgically resected lung specimens from patients with lung cancer (4 men and 6 women; median age, 59.7 years; mean  $\pm$  SEM age,  $67 \pm 2$  years).

### ***Antibodies***

The primary antibodies used for the immunohistochemical study included anti-HSP47 (Biotechnologies Corp., Victoria, Canada). Negative control studies were performed using irrelevant immunoglobulin G with the same subclass as the first antibodies instead of the primary antibodies.

### ***Immunohistochemistry***

Immunohistochemistry was performed with the conventional avidin-biotin-peroxidase histochemical technique using the Vecstain Elite ABC Kit (Vector Laboratories, Burlingame, CA, USA). Briefly, sequential paraffin sections (4 µm thick) were deparaffinized with toluene and rinsed thoroughly with ethanol. The sections were then soaked in 0.3% H<sub>2</sub>O<sub>2</sub> with absolute methanol for 20 minutes at room temperature to inactivate the endogenous peroxidase activity. They were incubated with blocking serum for 30 minutes, and then covered with primary antibodies at 4°C overnight. After washing in phosphate-buffered saline, the sections were processed further using the kits according to the instructions provided by the manufacturer, and then developed with 3,3'-diaminobenzidine and H<sub>2</sub>O<sub>2</sub>, followed by Mayer's hematoxylin staining method.

### ***Pathologic assessment***

The staining intensity and distribution of HSP47 in fibroblasts in active fibrotic areas (fibroblastic foci in UIP cases; alveolar septal interstitium expanded by fibrosis and intra-alveolar organizing fibrosis in fNSIP cases) were scored semi-quantitatively using a grading system of 0 to 3 (0 = negative; 1 = weak; 2 = moderate; 3 = strong). The

immunohistochemical score for each patient was calculated by averaging the score of each lobe. Histological sections were assessed independently, twice by each of two observers, and then analyzed statistically. Analysis of interobserver and intraobserver variability showed that the results were reproducible.

### *Statistical analysis*

All values are described as mean  $\pm$  standard error. Differences in categorical data between two groups were assessed by Fisher's exact probability test for data with two categories and by chi-square test for data with three or more categories. Differences in continuous data between two groups were assessed using the Wilcoxon rank-sum test, and differences in continuous data among three groups were assessed using the Kruskal-Wallis test. In addition, multivariate Cox regression analysis was used to examine the relationships between the presence/absence of idiopathic UIP and CVD-UIP and other variables. The overall survival experience for each group was estimated using Kaplan-Meier curves. The log-rank test was used to compare survival between two groups. Statistical significance was defined by a *p* value of less than 0.05. All data were analyzed using statistical software (Stat ViewJ-5.0; SAS Institute; Cary, NC, USA).

## Results

### *Patient Characteristics and Survival*

The I-fNSIP and CVD-fNSIP groups were both female-dominant and in their mid-fifties (Table 1). The percentage of neutrophils in BALF was slightly greater in CVD-fNSIP than in I-fNSIP. Figure 1 shows the comparison of the survival curves of the I-fNSIP, CVD-fNSIP, I-UIP, and CVD-UIP groups. The 5-year survival rates were: 78.2% in the I-fNSIP group; 77.8% in the CVD-fNSIP group; 51% in the I-UIP group; and 100% in the CVD-UIP group. Using the log-rank test, no significant difference in survival was found between the I-fNSIP and CVD-fNSIP groups ( $p = 0.903$ ); the I-UIP group had the worst prognosis, which was significantly different from that of the CVD-UIP group ( $p = 0.015$ ). The age of the patients was significantly different between the idiopathic UIP and CVD-UIP groups ( $p=0.0255$ ). After accounting for the age difference using multivariate Cox regression analysis, the prognoses of the I-UIP and CVD-UIP subgroups were still different, though the difference was not significant ( $p=0.07$ ). There was no association between survival and clinical features such as serum markers, results of pulmonary function tests, and BALF findings (data not shown).

### *Results of Pathologic Assessment and Their Association with Clinical Findings and Survival*

Representative examples of immunohistochemical staining for HSP47 in patients with I-fNSIP are shown in Figure 2. In fNSIP cases, unlike fibroblastic foci in UIP cases, lesions with active fibroblast proliferation were analyzed. The HSP47 scores in lung fibroblasts



were evaluated in all patients and controls (Figure 2). A negative control study using nonspecific immunoglobulin-G revealed no positive cells (data not shown).

HSP47 expression was significantly higher in all patient groups than in controls (vs. I-fNSIP,  $p = 0.0001$ ; vs. CVD-fNSIP,  $0.0017$ ; vs. I-UIP,  $p < 0.0001$ ; vs. CVD-UIP,  $p = 0.0065$ ) (Figure 3). Furthermore, the I-UIP group had a significantly higher expression of HSP47 than the CVD-UIP group ( $p = 0.0395$ ). No significant difference was found between the I-fNSIP and CVD-fNSIP groups ( $p = 0.335$ ). The associations between the HSP47 score and clinical features and laboratory data, including the pulmonary function test,  $\text{PaO}_2/\text{FiO}_2$  ratio and BALF findings, were also evaluated, but no associations were identified (data not shown). Figure 4 shows the survival curves of the I-fNSIP cases (A) and the I-UIP (B) groups, divided into two subgroups based on the average fibroblast HSP47 scores (1.19 and 1.36, respectively). In the I-fNSIP group, cases with HSP47 scores higher than the average value appeared to have a worse prognosis than those with HSP47 scores lower than the average value, though the  $p$  value was not calculable. In contrast, in the I-UIP group, there was no significant association between the HSP47 score and prognosis ( $p = 0.2632$ ). In the CVD-fNSIP and CVD-UIP groups, there was no significant association between the HSP47 score and prognosis (data not shown).

## Discussion

The histopathologic pattern of UIP is well-characterized, with the cardinal feature being the patchy distribution of temporally heterogeneous fibrosis, comprising areas of established fibrosis with adjacent foci of fibroblastic proliferation (so-called fibroblastic foci). Recent studies have emphasized the importance of the fibroblastic focus as a manifestation of ongoing lung injury in patients with established fibrosis.<sup>15-20</sup> A number of investigators have stressed the prognostic value of quantifying fibroblastic foci in patients with idiopathic interstitial pneumonia.<sup>19, 20</sup> Furthermore, a previous study showed that patients with CVD-UIP have fewer fibroblastic foci and better prognosis than patients with I-UIP.<sup>10</sup> In I-NSIP, which exhibits a more favorable response to corticosteroids and has a better prognosis than I-UIP,<sup>8, 21-24</sup> fibroblastic foci with dense fibrosis are inconspicuous or absent.<sup>1</sup> Thus, fibroblasts are believed to play an important role in the progression of chronic pulmonary fibrosis. However, previous studies did not fully elucidate the phenotypic differences in fibroblasts among I-UIP, CVD-UIP, I-NSIP, and CVD-NSIP.

In the present study, it was confirmed that expression of HSP47 in lung fibroblasts was higher in I-UIP patients than in CVD-UIP patients, as previously reported.<sup>13</sup> In this study, we reported the new finding that there was no significant difference in fibroblast HSP47 expression between patients with I-fNSIP and those with CVD-fNSIP. It is quite interesting that our findings suggest that I-UIP and CVD-UIP have different fibrotic pathways, while I-fNSIP and CVD-fNSIP might have similar fibrotic processes. This is consistent with the recent idea that I-NSIP and CVD-NSIP might be similar pathophysiological entities. Some authors have reported that the prognoses of I-NSIP and CVD-NSIP patients were similar,<sup>4</sup>

<sup>25</sup> and that it is very difficult to distinguish I-NSIP from NSIP associated with underlying diseases.<sup>26</sup> In the present study, we also demonstrated that the I-fNSIP and CVD-fNSIP groups had almost the same prognosis (5-year survival, 77.5% and 77.8%, respectively), and their lung fibroblast HSP47 expression was also similar. There is a clinical condition called undifferentiated connective tissue disease (UCTD) characterized by the presence of signs and symptoms suggestive of a systemic autoimmune disease without satisfying the criteria for connective tissue diseases.<sup>27</sup> It has been recently hypothesized that I-NSIP is an autoimmune disease that is the lung manifestation of UCTD,<sup>7</sup> or that NSIP might be the first clinical presentation of various CVDs.<sup>9</sup> Still, a recent report stated that I-NSIP was a distinct clinical entity with a very good prognosis.<sup>5</sup> Thus, the ultimate goal now is to determine what NSIP is.

Jegal et al demonstrated that decreased initial forced vital capacity and diffusing capacity of lung for carbon monoxide, increased age, male sex, a lower resting PaO<sub>2</sub>, and deteriorated forced vital capacity at 6 months, in addition to the pathologic pattern of UIP, were all associated with increased mortality among 179 fibrotic IP patients.<sup>3</sup> In addition to these, the present study showed that higher fibroblast HSP47 expression was significantly associated with poor mortality in I-fNSIP patients. As the expression and synthesis of HSP47 closely correlates with that of collagens in various cell lines and tissues of fibrosis models,<sup>13, 28-31</sup> higher HSP47 expression reflects advanced collagen synthesis and stronger fibrotic change in the involved lung, and this might correlate well with poor prognosis in these diseases. However, there was no association between fibroblast expression of HSP47 and prognosis in I-UIP patients. These findings imply that the association between HSP47 expression and prognosis differs somewhat between I-UIP and I-fNSIP. The NSIP pattern

encompasses a broad spectrum of histologic features with varying degrees of alveolar wall inflammation or fibrosis.<sup>1</sup> Of the types of IIP, the histologic features of NSIP do not fit the histologic pattern of UIP, organizing pneumonia, diffuse alveolar damage, desquamative interstitial pneumonia, respiratory bronchiolitis-associated interstitial lung disease, or lymphoid interstitial pneumonia. In contrast to UIP, it is uncertain whether NSIP is an independent clinical entity. In view of the variable pathology, response to treatment, and prognosis, further subclassification is warranted. The expression of HSP47 might be useful for further subclassification of NSIP. However, this study has limitations, in that it included only a small number of patients and was retrospective. Furthermore, the comparisons were not adjusted for other factors. Various selection biases (patient selection, selection of fragments in surgical lung biopsy, and selection of therapy for each patient) affect the results in this study. Thus, well-planned prospective studies using a large number of patients are required to determine the role of HSP47 as a prognostic factor in interstitial pneumonias.

In conclusion, we have shown that there was no significant difference in fibroblast HSP47 expression between patients with I-fNSIP and those with CVD-fNSIP. We also have shown that higher fibroblast HSP47 expression was significantly associated with poor mortality in I-fNSIP patients. Our findings imply that I-fNSIP and CVD-fNSIP might have similar fibrotic processes, and that HSP47 might be a prognostic marker for I-NSIP. Further studies involving a large number of patients are required to determine the prognostic and therapeutic values of HSP47 expression.

**Acknowledgements**

The authors would like to thank Mr. Atsushi Yokoyama for his excellent technical assistance, Dr. Masanori Kitaichi (Department of Laboratory Medicine and Pathology, NHO Kinki-Chuo Chest Medical Center) for his valuable advice regarding pathological diagnoses, and Dr. Mariko Mine (Division of Scientific Data Registry, Atomic Bomb Disease Institute, Nagasaki University Graduate School of Biomedical Sciences) for her valuable advice regarding the statistical analysis.

**Conflict of Interest**

There are no conflicts of interest.

## References

1. American Thoracic Society/European Respiratory Society International  
Multidisciplinary Consensus Classification of the Idiopathic Interstitial Pneumonias.  
This joint statement of the American Thoracic Society (ATS), and the European  
Respiratory Society (ERS) was adopted by the ATS board of directors, June 2001 and  
by the ERS Executive Committee, June 2001. *Am J Respir Crit Care Med*  
2002;165:277-304.
2. Latsi PI, du Bois RM, Nicholson AG, et al. Fibrotic idiopathic interstitial pneumonia:  
the prognostic value of longitudinal functional trends. *Am J Respir Crit Care Med*  
2003;168:531-7.
3. Jegal Y, Kim DS, Shim TS, et al. Physiology is a stronger predictor of survival than  
pathology in fibrotic interstitial pneumonia. *Am J Respir Crit Care Med*  
2005;171:639-44.
4. Park JH, Kim DS, Park IN, et al. Prognosis of fibrotic interstitial pneumonia: idiopathic  
versus collagen vascular disease-related subtypes. *Am J Respir Crit Care Med*  
2007;175:705-11.
5. Travis WD, Hunninghake G, King TE, Jr., et al. Idiopathic nonspecific interstitial  
pneumonia: report of an American Thoracic Society project. *Am J Respir Crit Care*  
*Med* 2008;177:1338-47.
6. Nagai S, Handa T, Tabuena R, Kitaichi M, and Izumi T. Nonspecific interstitial  
pneumonia: a real clinical entity? *Clin Chest Med* 2004;25:705-15.
7. Kinder BW, Collard HR, Koth L, et al. Idiopathic nonspecific interstitial pneumonia:

- lung manifestation of undifferentiated connective tissue disease? *Am J Respir Crit Care Med* 2007;176:691-7.
8. Nicholson AG, Colby TV, du Bois RM, Hansell DM, and Wells AU. The prognostic significance of the histologic pattern of interstitial pneumonia in patients presenting with the clinical entity of cryptogenic fibrosing alveolitis. *Am J Respir Crit Care Med* 2000;162:2213-7.
  9. Sato T, Fujita J, Yamadori I, et al. Non-specific interstitial pneumonia as the first clinical presentation of various collagen vascular disorders. *Rheumatol Int* 2006;26:551-5.
  10. Flaherty KR, Colby TV, Travis WD, et al. Fibroblastic foci in usual interstitial pneumonia: idiopathic versus collagen vascular disease. *Am J Respir Crit Care Med* 2003;167:1410-5.
  11. Shiohita K, Miyazaki M, Ozono Y, et al. Expression of heat shock proteins 47 and 70 in the peritoneum of patients on continuous ambulatory peritoneal dialysis. *Kidney Int* 2000;57:619-31.
  12. Nagata K. [Therapeutic strategy for fibrotic diseases by regulating the expression of collagen-specific molecular chaperone HSP47]. *Nippon Yakurigaku Zasshi* 2003;121:4-14.
  13. Kakugawa T, Mukae H, Hayashi T, et al. Expression of HSP47 in usual interstitial pneumonia and nonspecific interstitial pneumonia. *Respir Res* 2005;6:57.
  14. Iwashita T, Kadota J, Naito S, et al. Involvement of collagen-binding heat shock protein 47 and procollagen type I synthesis in idiopathic pulmonary fibrosis: contribution of type II pneumocytes to fibrosis. *Hum Pathol* 2000;31:1498-505.

15. Kuhn C, and McDonald JA. The roles of the myofibroblast in idiopathic pulmonary fibrosis. Ultrastructural and immunohistochemical features of sites of active extracellular matrix synthesis. *Am J Pathol* 1991;138:1257-65.
16. Selman M, King TE, and Pardo A. Idiopathic pulmonary fibrosis: prevailing and evolving hypotheses about its pathogenesis and implications for therapy. *Ann Intern Med* 2001;134:136-51.
17. Katzenstein AL, and Myers JL. Idiopathic pulmonary fibrosis: clinical relevance of pathologic classification. *Am J Respir Crit Care Med* 1998;157:1301-15.
18. Cooper JA, Jr. Pulmonary fibrosis: pathways are slowly coming into light. *Am J Respir Cell Mol Biol* 2000;22:520-3.
19. King TE, Jr., Schwarz MI, Brown K, et al. Idiopathic pulmonary fibrosis: relationship between histopathologic features and mortality. *Am J Respir Crit Care Med* 2001;164:1025-32.
20. Nicholson AG, Fulford LG, Colby TV, et al. The relationship between individual histologic features and disease progression in idiopathic pulmonary fibrosis. *Am J Respir Crit Care Med* 2002;166:173-7.
21. Bjraker JA, Ryu JH, Edwin MK, et al. Prognostic significance of histopathologic subsets in idiopathic pulmonary fibrosis. *Am J Respir Crit Care Med* 1998;157:199-203.
22. Travis WD, Matsui K, Moss J, and Ferrans VJ. Idiopathic nonspecific interstitial pneumonia: prognostic significance of cellular and fibrosing patterns: survival comparison with usual interstitial pneumonia and desquamative interstitial pneumonia. *Am J Surg Pathol* 2000;24:19-33.



23. Daniil ZD, Gilchrist FC, Nicholson AG, et al. A histologic pattern of nonspecific interstitial pneumonia is associated with a better prognosis than usual interstitial pneumonia in patients with cryptogenic fibrosing alveolitis. *Am J Respir Crit Care Med* 1999;160:899-905.
24. Flaherty KR, Toews GB, Travis WD, et al. Clinical significance of histological classification of idiopathic interstitial pneumonia. *Eur Respir J* 2002;19:275-83.
25. Nakamura Y, Chida K, Suda T, et al. Nonspecific interstitial pneumonia in collagen vascular diseases: comparison of the clinical characteristics and prognostic significance with usual interstitial pneumonia. *Sarcoidosis Vasc Diffuse Lung Dis* 2003;20:235-41.
26. Fujita J, Ohtsuki Y, Yoshinouchi T, et al. Idiopathic non-specific interstitial pneumonia: as an "autoimmune interstitial pneumonia". *Respir Med* 2005;99:234-40.
27. Mosca M, Tani C, Neri C, Baldini C, and Bombardieri S. Undifferentiated connective tissue diseases (UCTD). *Autoimmun Rev* 2006;6:1-4.
28. Masuda H, Fukumoto M, Hirayoshi K, and Nagata K. Coexpression of the collagen-binding stress protein HSP47 gene and the alpha 1(I) and alpha 1(III) collagen genes in carbon tetrachloride-induced rat liver fibrosis. *J Clin Invest* 1994;94:2481-8.
29. Pan H, and Halper J. Regulation of heat shock protein 47 and type I procollagen expression in avian tendon cells. *Cell Tissue Res* 2003;311:373-82.
30. Yoshioka S, Mukae H, Ishii H, et al. Alpha-defensin enhances expression of HSP47 and collagen-1 in human lung fibroblasts. *Life Sci* 2007;80:1839-45.
31. Nakayama S, Mukae H, Sakamoto N, et al. Pirfenidone inhibits the expression of HSP47 in TGF-beta1-stimulated human lung fibroblasts. *Life Sci* 2008;82:210-7.

## **Figure Legends**

### **Figure 1**

Comparison of the survival curves of all subject groups.

### **Figure 2**

Immunohistochemical staining for HSP47 of surgical lung biopsy specimens taken from patients with idiopathic fibrotic NSIP. Fibroblast HSP47 score: a = 0 (negative), b = 1 (weak), c = 2 (moderate), d = 3 (strong). Scale bar = 500  $\mu$ m.

### **Figure 3**

Box-and-whisker plots of the HSP47 scores in lung fibroblasts in patients with idiopathic-fNSIP, CVD-fNSIP, idiopathic-UIP, and CVD-UIP.

\* $p < 0.01$ , compared with control. The boxes represent the 25<sup>th</sup> to 75<sup>th</sup> percentiles, the solid lines within the boxes show the median values, the whiskers are the 10<sup>th</sup> and 90<sup>th</sup> percentiles. CVD = collagen vascular disease; HSP47 = heat shock protein 47; fNSIP = fibrotic nonspecific interstitial pneumonia; UIP = usual interstitial pneumonia.

### **Figure 4**

The survival curves of the idiopathic-fibrotic NSIP (A) and idiopathic-UIP (B) groups, divided into two subgroups based on the average fibroblast HSP47 score (1.19 and 1.36, respectively).

**Key Words**

Collagen vascular disease

Fibrotic interstitial pneumonia

Fibrotic nonspecific interstitial pneumonia

Heat shock protein 47

Usual interstitial pneumonia

### **Abbreviation List**

**BALF:** Bronchoalveolar lavage fluid

**CVD:** collagen vascular disease

**DM:** dermatomyositis

**I-fNSIP:** idiopathic fibrotic nonspecific interstitial pneumonia

**HSP:** heat shock protein

**IIP:** idiopathic interstitial pneumonia

**IPF:** idiopathic pulmonary fibrosis

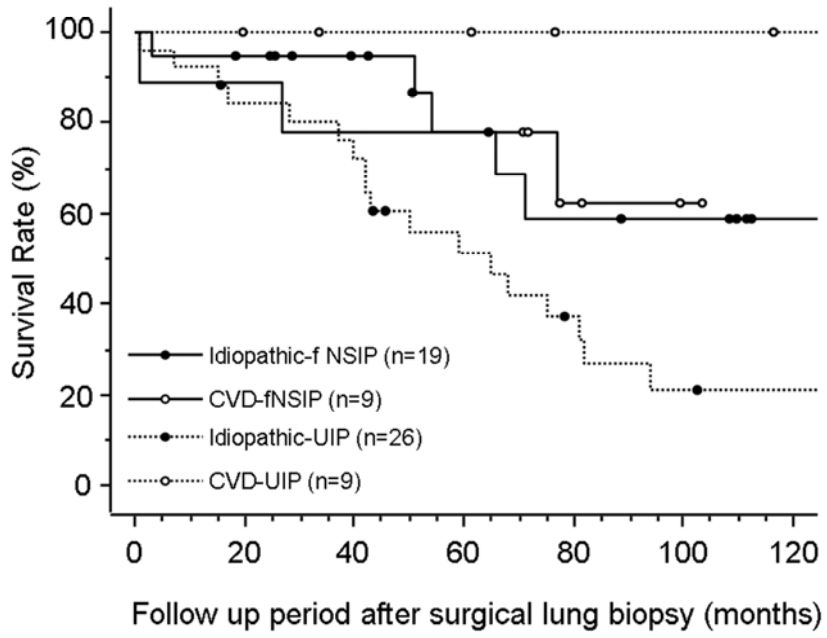
**MCTD:** mixed connective tissue diseases

**SjS:** Sjögren syndrome

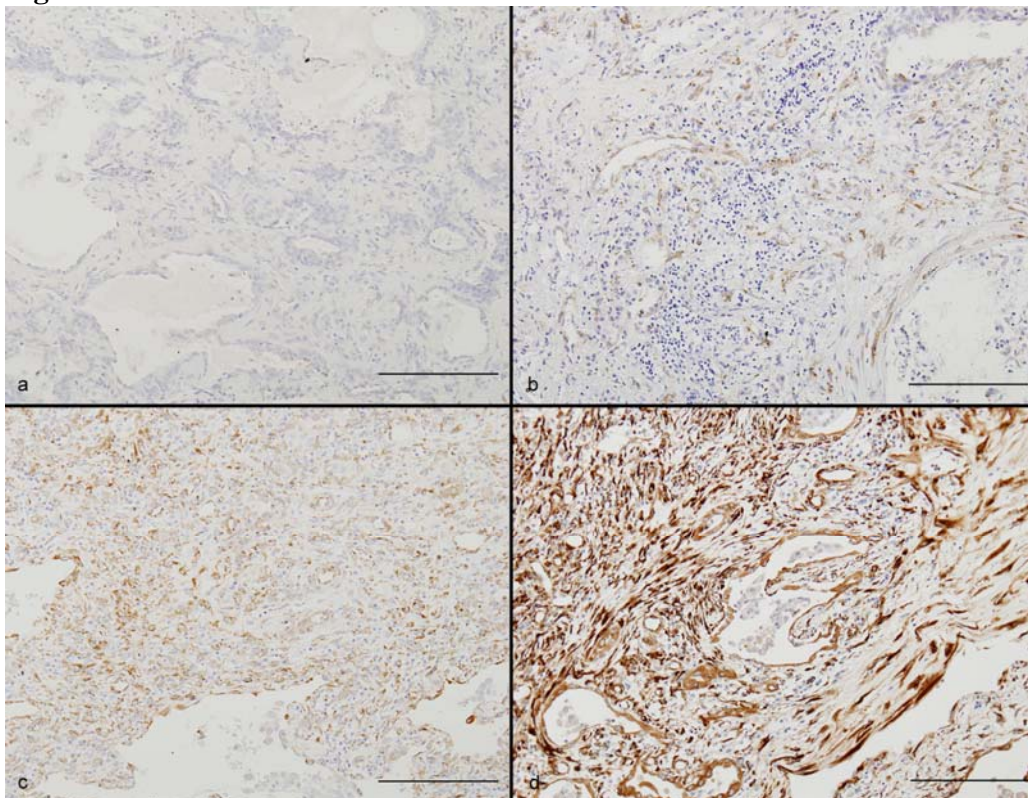
**SSc:** systemic sclerosis

**I-UIP:** idiopathic usual interstitial pneumonia

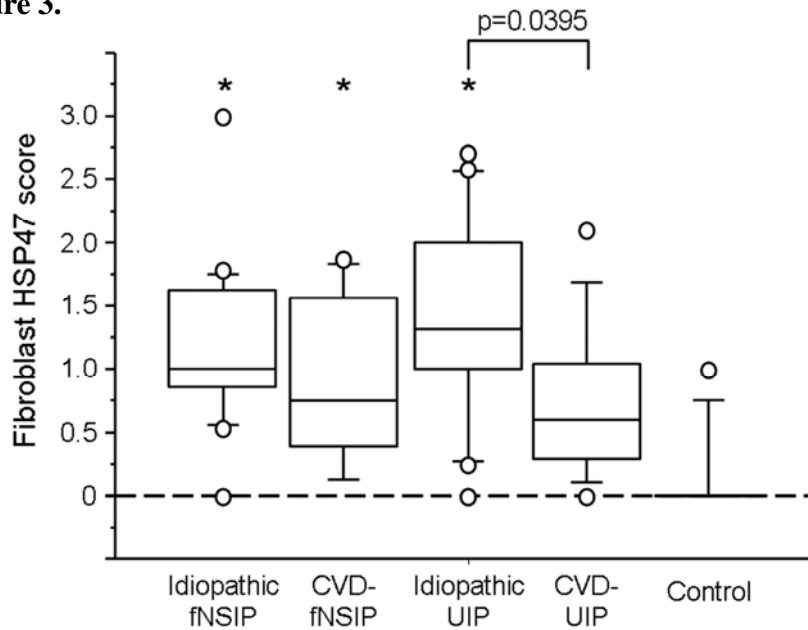
**Figure 1.**



**Figure 2.**



**Figure 3.**



**Figure 4.**

