

AFRICAN ENDEMIC-TYPE KAPOSÍ'S SARCOMA — A HISTOPATHOLOGIC STUDY AND FLOW CYTOMETRIC DNA ANALYSIS OF NINE CASES —

HIDEAKI ETO^{1,*}, KAN TORIYAMA¹, HIDEYO ITAKURA¹,
YUTAKA TAGAWA² AND NOAH O. KAMIDIGO³

Received February 5 1992/Accepted March 14 1992

Abstract: Flow cytometric DNA analysis using formalin-fixed, paraffin-embedded tissues were performed on nine cases of African endemic-type Kaposi's sarcoma (KS). Histologically, these cases were classified into the following three types; granulation tissue-like (one case), angioma/angiosarcoma-like (four cases) and spindle cell (four cases). Although these three types showed a variety of cellularity and cellular atypism, there were no fundamental differences in the view point of proliferation of spindle cell. Mitotic figures were not prominent. All cases were exclusively diploid and lacked an aneuploid population by flow cytometric measurement of DNA content. These results suggest that African endemic-type KS is a less aggressive disease rather than a malignant neoplasm.

INTRODUCTION

Kaposi's sarcoma (KS) was first described by Kaposi (1872) as an "Idiopathic multiple pigmented sarcoma of the skin". Since then, many cases of KS have been reported in European, American and African countries. Recently, it has been observed frequently in patients with acquired immune deficiency syndrome (AIDS).

KS is broadly classified into four categories; classical (European) type, African endemic-type, AIDS-related type and the type associated with immunosuppressive therapy. The clinical manifestations of these types are not necessarily same (Safai, 1985; Itakura *et al.*, 1986). Furthermore, African endemic-type KS is divided into cutaneous form and lymph node form by the affected site (Toriyama *et al.*, 1987a, b). Generally, cutaneous KS is long standing, spontaneously regressive, and not fatal. On the other hand, lymph node KS mainly occurs in children, and shows an aggressive clinical course similar to that of adult AIDS patients (Olweny *et al.*, 1976; Bayley, 1983). However, it has been reported that twenty-seven years was the longest duration of lymph node KS following initial diagnosis in childhood (Dutz and Stout, 1960). The true nature of KS including histogenesis has been widely discussed, but still remains obscure.

Flow cytometric measurement of DNA content has been increasingly used as an objec-

-
- 1 Department of Pathology, Institute of Tropical Medicine, Nagasaki University, 12-4 Sakamoto-machi, Nagasaki 852, Japan (*correspondent author)
 - 2 First Department of Surgery, Nagasaki University School of Medicine, 7-1 Sakamoto-machi, Nagasaki 852, Japan
 - 3 Histology Department, Rift Valley Provincial Hospital, P.O.Box 71, Nakuru, Kenya

tive determinant of biological behavior and prognosis in certain solid neoplasms. Abnormal DNA ploidy appears to indicate poor prognosis in various malignant tumors (Hedley *et al.*, 1985; Merkel *et al.*, 1987; Kiyabu *et al.*, 1988; Stanley *et al.*, 1988). However, there have been few flow cytometric studies of KS. We have performed flow cytometric DNA analysis of paraffin-embedded tissues of African endemic-type KS, and discussed the relationship between histological findings and DNA ploidy.

MATERIALS AND METHODS

Materials:

Nine cases of KS obtained from 1986 to 1989 in Provincial General Hospitals in Nakuru and Kisumu, the Republic of Kenya, were examined. Clinical data and relevant information were recorded as accurately as possible.

Histopathologic studies:

For light microscopic examination, each specimen was prepared with hematoxylin-eosin stain (H.E.), periodic acid-Schiff reaction, Azan-Mallory's stain and silver impregnation for reticulin fibers. Histological growth pattern, cellularity, cellular atypism and mitotic rate (per 10 high power fields; $\times 400$) were determined.

Flow Cytometry:

The technique of Schutte (1985) for DNA analysis was employed using the formalin-fixed, paraffin-embedded tissues. In brief, single cell suspension was obtained by mechanical and enzymatic treatment of three or four 50 μm paraffin sections of each specimen, and stained with propidium iodide. Cellular DNA content was measured by a FACScan equipped with an argon laser. The excitation wavelength was 488 nm. The number of cells in each measurement was at least 2×10^4 . The coefficient of variation (CV) of the diploid peak ranged from 4.0 to 8.7. To confirm the presence of the lesion in sections used for DNA analysis, we cut further 4 μm sections adjacent to the analyzed sections from each specimen. They were stained with hematoxylin-eosin and examined to reconfirm the histological diagnosis and features.

RESULTS

The clinical manifestation, histologic features and DNA ploidy in the nine cases were summarized in Table 1. The age of these patients ranged from 18 to 56 years (mean 40 years). All patients were male. Eight of the nine cases occurred in the skin of the lower extremities. One case occurred in the lymph nodes of the upper arm.

According to the predominant histological features, three main types of growth were recognized. One case was classified as the granulation tissue-like type. This was characterized by an angioproliferative process with an inflammatory cell infiltration, but was less cellular than the other two types (Fig. 1). Four cases were angioma/angiosarcoma-like type. The lesions were composed predominantly of well-formed vascular spaces, with slit-like or anastomosing vasculature similar to that seen in angiosarcoma, but with minimal cellular atypism (Fig. 2). Four cases were spindle cell type. This type showed a high cellularity, but its cellular atypism and mitotic figures were not prominent (Fig. 3). Transitional zones and intermingling of these three types were also frequently observed in the same case. Mitotic

Table 1 Clinical manifestation, histologic features and DNA ploidy of African endemic-type Kaposi's sarcoma

Case	Age(yr)	Sex	Site of location	Histological type	Cellularity	Cellular atypism	Mitotic rate (per 10HPFs)	DNA ploidy
1	55	M	Skin (leg)	S	+++	++	4	D
2	32	M	Skin (limb)	S	+++	+	2	D
3	U	M	Skin (leg)	A	++	+	1	D
4	39	M	Skin (leg)	A	++	+	3	D
5	53	M	Skin (limb)	S	+++	+	5	D
6	56	M	Skin (foot)	A	++	+	1	D
7	18	M	Skin (knee)	A	++	++	0	D
8	38	M	Skin (leg)	G	+	+	0	D
9	30	M	Lymph node (upper arm)	S	+++	++	8	D

U:unknown; G:granulation tissue-like type; A:angioma/angiosarcoma-like type; S:spindle cell type; HPF:high power field; D:diploid

rate ranged from 0 to 8 per 10 high-power fields ($\times 400$).

All cases were diploid by flow cytometric measurement of DNA content.

DISCUSSION

Many studies have been performed about the histogenesis of KS, such as vascular endothelial cell (Hashimoto *et al.*, 1987; Scully *et al.*, 1988), lymphatic endothelial cell (Beckstead *et al.*, 1985; Dictor and Anderson, 1988) and mesenchymal cell (Komuro and Toriyama, 1991). Some immune factors with angiogenic activity, such as thymosin, interferon, lymphokines and prostaglandin, are thought to be crucial to the development of KS (Levy

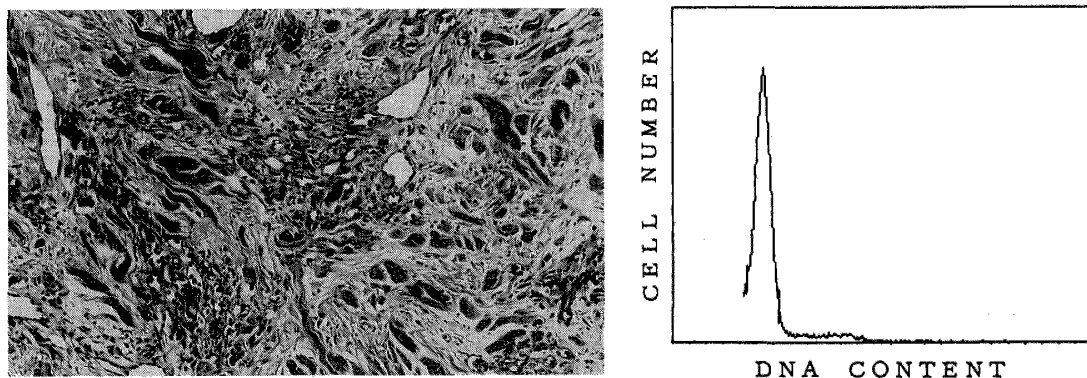


Figure 1 (left) Case 8 (granulation tissue-like type). The lesion is characterized by an angioproliferative process with an inflammatory cell infiltration (H.E., $\times 100$). (right) DNA histogram showing diploidy (CV 8.2).

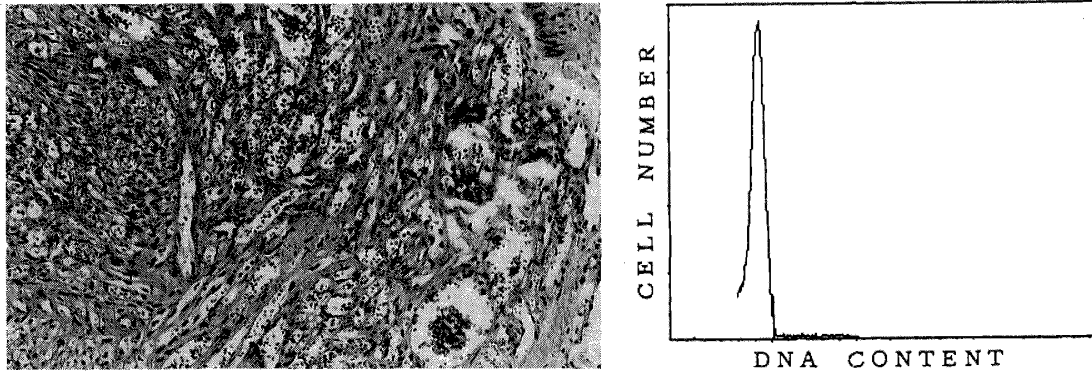


Figure 2 (left) Case 6(angioma/angiosarcoma-like type). The lesion is composed predominantly of anastomosing vascular channels and well-formed vessels (H.E., $\times 100$). (right) DNA histogram showing diploidy (CV 7.7).

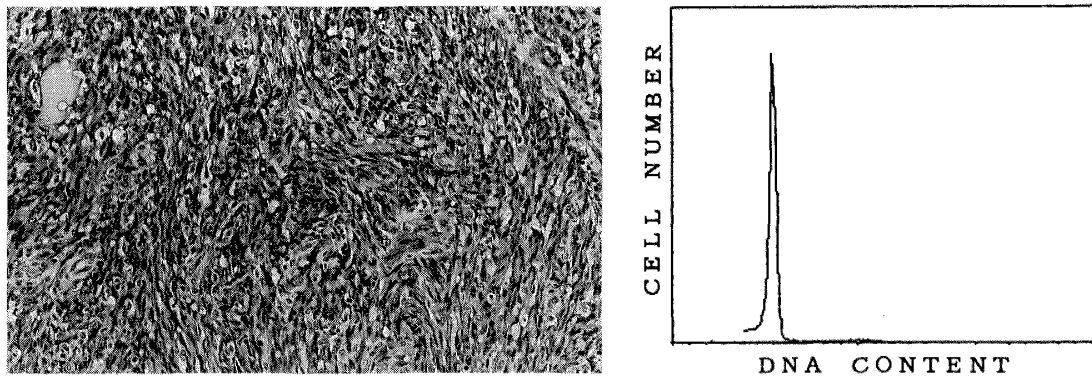


Figure 3 (left) Case 9(spindle cell type). The lesion is formed by interlacing bundles of spindle shaped cells (H.E., $\times 100$). (right) DNA histogram showing diploidy (CV 4.0).

and Ziegler, 1983). However, the true nature of KS, whether hyperplasia or neoplasia, remains unknown (Costa and Rabson, 1983; Brooks, 1986; Mirra, 1986).

African endemic-type KS is usually divided into cutaneous form and lymph node form by the affected site (Toriyama *et al.*, 1987a, b). Generally, cutaneous KS usually occurs in lower extremities of adults, and is long standing, growing slowly and occasionally regressive (Itakura *et al.*, 1986). On the other hand, lymph node KS mainly occurs in children without cutaneous lesions, and shows an aggressive clinical course with generalized lesions often involving the visceral organs similar to that of adult AIDS patients (Olweny *et al.*, 1976; Bayley, 1984). However, it has been reported that twenty-seven years was the longest duration of lymph node KS following initial diagnosis in childhood (Dutz and Stout, 1960).

In this study, African endemic-type KS was histologically classified into the following three types; granulation-tissue like type, angioma/angiosarcoma like type and spindle cell type. Transitional zones and intermingling of these three types were also frequently observed

in the same case. Although these three types showed a variety of cellularity and cellular atypism, there were no fundamental differences in the view point of proliferation of spindle cell. Mitotic figures were not prominent.

Recently, DNA ploidy analysis by flow cytometry has shown that DNA aneuploidy is common in several malignant tumors and is a useful prognostic indicator (Hedley *et al.*, 1985; Merkel *et al.*, 1987; Kiyabu *et al.*, 1988; Stanly *et al.*, 1988). However, there has been no flow cytometric studies of African endemic-type Kaposi's sarcoma. In our study, all cases of African endemic-type KS were exclusively diploid and lacked an aneuploid population by flow cytometric measurement of DNA content. Histological appearance and DNA ploidy of lymph node KS were identical with cutaneous KS. These results are consistent with the reported findings in AIDS-related type KS cases (Fukunaga and Silverberg, 1990). Although there are no sufficient follow-up studies, our results suggest that African endemic-type KS is a less aggressive disease rather than a malignant neoplasm.

REFERENCES

- 1) Bayley, A.C. (1984): Aggressive Kaposi's sarcoma in Zambia, 1983, *Lancet*, 1, 1318-1320
- 2) Beckstead, J.H., Wood, G.S. and Fletcher, F. (1985): Evidence for the origin of Kaposi's sarcoma from lymphatic endothelium, *Am. J. Pathol.*, 119, 294-300
- 3) Brooks, J.J. (1986): Kaposi's sarcoma: A reversible hyperplasia, *Lancet*, 2, 1309-1310
- 4) Costa, J. and Rabson, A.S. (1983): Generalized Kaposi's sarcoma is not a neoplasm, *Lancet*, 1, 58
- 5) Dictor, M. and Anderson, C. (1988): Lymphaticovenous differentiation in Kaposi's sarcoma: Cellular phenotypes by stage, *Am. J. Pathol.*, 130, 411-417
- 6) Dutz, W. and Stout, A.P. (1960): Kaposi's sarcoma in infants and children, *Cancer*, 13, 684-694
- 7) Fukunaga, M. and Silverberg, S.G. (1990): Kaposi's sarcoma in patients with acquired immune deficiency syndrome: A flow cytometric DNA analysis of 26 lesions in 21 patients, *Cancer*, 66, 74-77
- 8) Hashimoto, H., Muller, H., Falk, S. and Stutte, H.J. (1987): Histogenesis of Kaposi's sarcoma associated with AIDS: A histologic, immunohistochemical and enzyme histochemical study, *Pathol. Res. Pract.*, 182, 658-668
- 9) Hedley, D.W., Freidlander, M.L. and Taylor, I.W. (1985): Application of DNA flow cytometry of paraffin-embedded archival material for the study of aneuploidy and its clinical significance, *Cytometry*, 6, 26-30
- 10) Itakura, H., Toriyama, K. and Uzuta, F. (1986): Kaposi's sarcoma, pathology and local epidemiology in Kenya, *Trop. Med.*, 28 (suppl.), 3-8
- 11) Kaposi, M. (1872): Idiopathisches multiples Pigmentsarkom der Haut, *Arch. Derm. Syph.*, 4, 265-273
- 12) Kiyabu, M.T., Bishop, P.C., Parker, J.W., Turner, R.R. and Fitzgibbon, P.L. (1988): Smooth muscle tumors of the gastrointestinal tract: flow cytometric quantitation of DNA and nuclear antigen content and correlation with histologic grade, *Am. J. Surg. Pathol.*, 12, 954-960
- 13) Komuro, S. and Toriyama, K. (1991): Geopathology of endemic pediatric lymph node Kaposi's sarcoma in western Kenya, *Jpn. J. Trop. Med. Hyg.*, 19, 251-263
- 14) Levy, J.A. and Ziegler, J.L. (1983): Acquired immunodeficiency syndrome is an opportunistic infection and Kaposi's sarcoma results from secondary immune stimulation, *Lancet*, 1, 78-80
- 15) Merkel, D.E., Dressler, L.G. and Mcguire, W.L. (1987): Flow cytometry, cellular DNA content, and prognosis in human malignancy, *J. Clin. Oncol.*, 5, 1690-1703

- 16) Mirra, J.M. (1986): Kaposi's "Sarcoma": Is it a sarcoma at all?, *Trop. Med.*, 28 (suppl.), 49-62
- 17) Olweny, C.L.M., Kaddumukasa, A., Atine, I., Ower, R., Magrath, I. and Ziegler, J.L. (1976): Childhood Kaposi's sarcoma: Clinical features and therapy, *Br. J. Cancer.*, 33, 555-560
- 18) Safai, B. (1985): Kaposi's sarcoma and other neoplasms in Acquired Immunodeficiency Syndrome: *Advances in Host Defense Mechanisms*, 5, 59-73, Raven Press, New York
- 19) Schutte, B., Reynder, M.M.J., Bosman, F.T. and Blijam, G.H. (1985): Flow cytometric determination of DNA ploidy level in nuclei isolated from paraffin-embedded tissue, *Cytometry*, 6, 26-30
- 20) Scully, P.A., Steinman, H.K., Kennedy, C., Trueblood, K., Frisman, D.M. and Voland, J.R. (1988): AIDS-related Kaposi's sarcoma displays differential expression of endothelial surface antigens, *Am. J. Pathol.*, 130, 244-251
- 21) Stanley, J.R., Wooldridge, T.N. and Linder, J. (1988): Flow cytometric DNA analysis of malignant fibrous histiocytoma and related fibrohistiocytic tumors, *Hum. Pathol.*, 19, 74-77
- 22) Toriyama, K., Uzuta, F. and Itakura, H. (1987a): Geopathological study on endemic Kaposi's sarcoma in western Kenya, *Trop. Med.*, 29(2), 87-100
- 23) Toriyama, K., Uzuta, F. and Itakura, H. (1987b): Kaposi's sarcoma of lymph node(s) in western Kenya, *Trop. Med.*, 29(2), 101-106

アフリカ風土病型カポシ肉腫
— 9例における病理組織学的検討ならびにフローサイトメトリー法
による核DNA量解析 —

江藤 秀顕¹・鳥山 寛¹・板倉 英吾¹・
田川 泰²・Noah O. KAMIDIGO³

カポシ肉腫 (Kaposi's sarcoma, KS) は一般には、欧米古典型、アフリカ風土病型、AIDS関連型、その他の免疫不全型の4型に大別され、さらにアフリカ風土病型KSは、発生部位により皮膚型とリンパ節型に分けられている。それぞれの型において若干の病態的な差異が認められているが、その組織発生を含め本態は未だ不明のことが多い。最近ではフローサイトメトリー (FCM) 法による核DNA量解析が腫瘍、あるいは腫瘍様病変の悪性度評価に、広く用いられている。今回9例のアフリカ風土病型KSにおいて、病理組織学的検討、ならびにホルマリン固定、パラフィン包埋ブロックを用いたFCM法による、核DNA量解析を行った。組織学的には次の3型に分けられた。すなわち肉芽組織類似型 (1例)、血管腫あるいは血管肉腫類似型 (4例) と紡錘形細胞型 (4例) である。これら3型においては、細胞密度や細胞異型に程度の差はあるものの、紡錘形細胞の増殖という点からは、基本的な差は見られなかった。核分裂像も目立たなかった。FCM法による核DNA量では、全例がdiploidを示しており、aneuploid例は見られなかった。これらの結果より、アフリカ風土病型KSは悪性腫瘍というより、むしろ less aggressive な病変であると思われた。

1 長崎大学熱帯医学研究所病理学部門 (〒852 長崎市坂本町12-4)
2 長崎大学医学部第一外科学教室
3 リフトバレー州立病院, ケニア