

Ectopic Calcinosi s of the Mitral Valve in a Patient Undergoing Long-Term Hemodialysis

Key words: ectopic calcinosis, hyperparathyroidism, hemodialysis

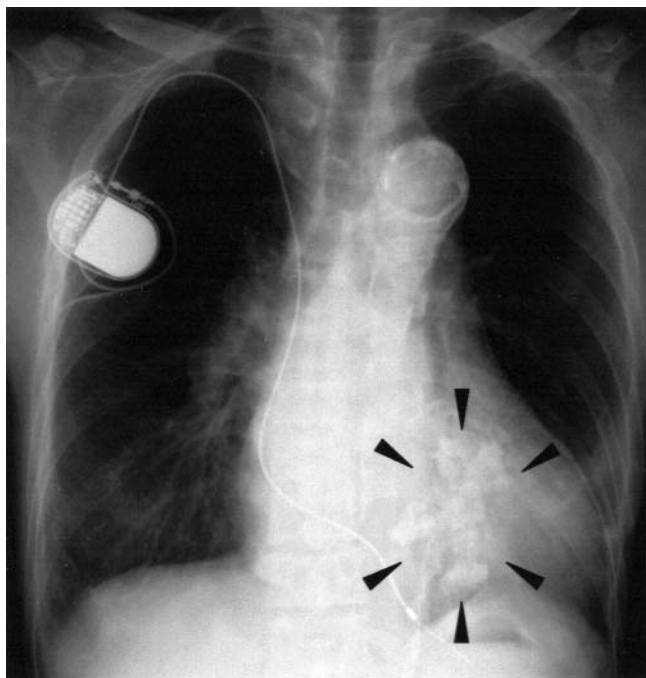


Figure 1.

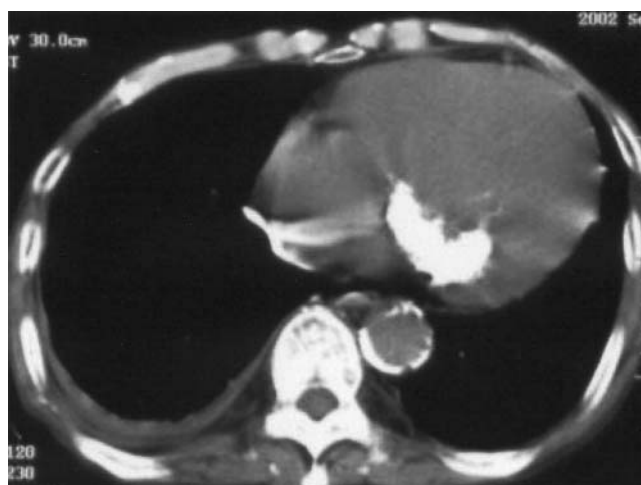


Figure 2.

A 52-year-old man who was receiving chronic hemodialysis for 11 years was referred to our hospital because of pleural tuberculosis. On admission he had severe secondary hyperparathyroidism (2HPT) and his serum level of intact parathyroid hormone was 1,489 pg/ml. His bone mineral density was low, and he had significant ectopic calcinosis. A chest radiograph (arrowheads in Fig. 1) and computed tomography of the chest (Fig. 2) revealed remarkable calcification of mitral valve.

Ectopic calcinosis is the complication of long-term dialysis due to 2HPT, which is a new disease in end-stage renal failure after dialysis was developed. His pleural tuberculosis was improved with tuberculocides but 2HPT was not improved with vitamin D analogs, therefore parathyroidectomy is now planned.

His abdominal radiograph was published in *New Engl J Med* 349: e12, 2003.

Yoshiaki NISHIOKA, Masanobu MIYAZAKI, Yumiko BANDO, Akira FURUSU, Tomoya NISHINO, Takashi HARADA* and Shigeru KOHNO

The Second Department of Internal Medicine and *Division of Renal Care Unit, Nagasaki University, Nagasaki

Received for publication November 6, 2003; Accepted for publication February 6, 2004

Reprint requests should be addressed to Dr. Yoshiaki Nishioka, the Second Department of Internal Medicine, Nagasaki University, 1-7-1 Sakamoto, Nagasaki 852-8501