

# Risk of Development of Abdominal Aortic Aneurysm and Dissection of Thoracic Aorta in a Postpartum Woman with Marfan's Syndrome

Aki Tomihara<sup>1</sup>, Naoto Ashizawa<sup>2</sup>, Kuniko Abe<sup>1</sup>, Naoe Kinoshita<sup>1</sup>, Keisuke Chihaya<sup>1</sup>,  
Tsuyoshi Yonekura<sup>2</sup>, Satoki Fukae<sup>2</sup>, Kazuto Ashizawa<sup>3</sup>, Kiyoyuki Eishi<sup>4</sup>,  
Tomayoshi Hayashi<sup>1</sup> and Katsusuke Yano<sup>2</sup>

---

## Abstract

---

A 24-year-old pregnant woman with Marfan's syndrome delivered by cesarean section during the 38th week of gestation. Although aortic root dilatation did not increase during pregnancy, three months after delivery, the patient noticed a pulsatile abdominal mass. Aortic aneurysm was diagnosed and surgical replacement of the infrarenal abdominal aorta to the common iliac arteries and reconstruction of the inferior mesenteric artery were performed. Moreover, the patient subsequently developed a Stanford type B thoracic aortic dissection, even after more than four months of  $\beta$ -blockade.

**Key words:** Marfan's syndrome, postpartum, abdominal aortic aneurysm, descending thoracic aortic dissection

(DOI: [10.2169/internalmedicine.45.1880](https://doi.org/10.2169/internalmedicine.45.1880))

---

## Introduction

---

Marfan's syndrome is an autosomal dominant disorder of the connective tissue, caused by mutations of the gene coding fibrillin on chromosome 15 (1, 2). Prevalence of this disease is estimated to range from 1 in 10,000 to 1 in 20,000 (1-4). The condition is characterized by musculoskeletal, cardiovascular, and ocular manifestations (1, 2, 4, 5). Cardiovascular disorders in this condition include mitral valve prolapse, mitral regurgitation, and aortic root dilatation with aortic valve incompetence (1, 2, 5). Aortic root dilatation and Stanford type A aortic dissection are the major causes of morbidity and mortality (5, 6).

Pregnancy imposes substantial cardiovascular stresses such as pressure and volume overload (3-7). Therefore, pregnancy in Marfan's syndrome increases the risk of aortic root dilatation and aortic dissection and seriously threatens

the life of the patient (3-7). We report the case of a young pregnant woman with Marfan's syndrome and mild dilatation of the aortic root, who developed postpartum abdominal aortic aneurysm followed by thoracic aortic dissection.

---

## Case Report

---

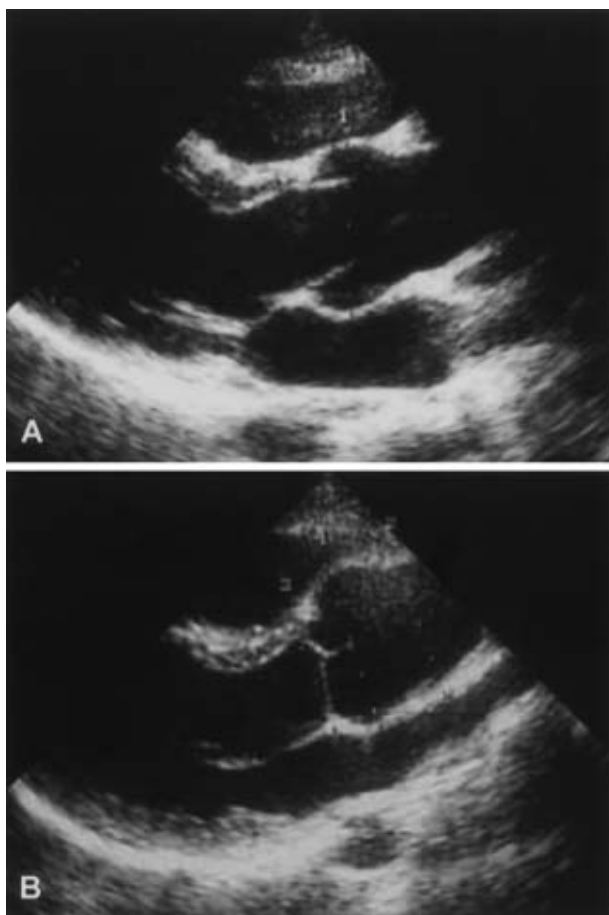
The patient was a 24-year-old Japanese woman. Her father had Marfan's syndrome and had undergone surgery for thoracic, abdominal, and subclavian artery aneurysms. The patient had not demonstrated any abnormalities at annual school checkups and her condition had therefore gone undiagnosed. However, her younger sister had a cardiovascular examination at the age of 14 and was found to have severe scoliosis and was diagnosed as having Marfan's syndrome; the patient (who was aged 22 at the time) was accordingly advised to undergo a complete physical examination. This revealed a high arched palate and arm span exceeding

---

<sup>1</sup> Department of Pathology, Nagasaki University Hospital, Nagasaki, <sup>2</sup> Division of Cardiovascular Medicine, Graduate School of Biomedical Sciences, Nagasaki University, Nagasaki, <sup>3</sup> Department of Radiology, Nagasaki University Hospital, Nagasaki and <sup>4</sup> Division of Cardiovascular Surgery, Graduate School of Biomedical Sciences, Nagasaki University, Nagasaki

Received for publication May 8, 2006; Accepted for publication August 15, 2006

Correspondence to Dr. Naoto Ashizawa, Division of Cardiovascular Medicine, Graduate School of Biomedical Sciences, Nagasaki University, 1-7-1 Sakamoto, Nagasaki 852-8501



**Figure 1.** Comparison of the aortic root during and after pregnancy. Transthoracic echocardiography showed aortic root dilatation to 42 mm during pregnancy (A) and 41 mm in the postpartum period (B). No marked change was observed in the size and shape of the aortic root.

height. Echocardiography revealed mild mitral regurgitation with anterior mitral valve prolapse and mild aortic regurgitation with aortic root dilatation (42 mm), indicating Marfan's syndrome (Fig. 1).

At the age of 23, the patient became pregnant. The attending physician advised her to terminate the pregnancy on medical grounds, however, she and her family desperately wanted to have a baby. During her pregnancy, the aortic root diameter was measured frequently for primary protection with echocardiography. About one week before the delivery in mid-December 2004, her blood pressure was 104/68 mmHg. At the 38th week of gestation, the patient uneventfully delivered a healthy female infant by cesarean section. However, in late March 2005, the patient noticed a pulsating mass in her lower abdomen, and on July 21, 2005, the patient consulted our department complaining of lower abdominal pain.

On physical examination, she was 171.0 cm in height, and 52.9 kg in weight. Her arm span was 172.0 cm. Her blood pressure was 118/68 mmHg, pulse rate was regular and 84 beats/min. High arched palate was found and posi-

tive wrist and thumb signs demonstrated arachnodactyly. Dislocation of the lens was not evident. A systolic click and Levine I/VI systolic murmur was audible at the 4th left sternal border to the apex. A pulsating mass (5×5 cm) was palpable slightly to the left of the umbilicus.

Chest X-ray revealed mild scoliosis, but did not demonstrate either funnel chest or cardiomegaly. Electrocardiography showed a biphasic P wave and RSR' pattern in V1 but did not show left ventricular hypertrophy. Transthoracic echocardiography revealed anterior mitral valve prolapse, and aortic root diameter was 41 mm, almost the same as before delivery (Fig. 1). The abdominal echogram showed a remarkable increase of the abdominal aortic diameter from 4 cm at the 31st week of gestation to 8 cm (Fig. 2). The abdominal CT revealed an infrarenal spindle-shaped true abdominal aortic aneurysm with maximum dimensions of 79×76 mm. On August 1, 2005, the patient underwent surgical replacement the infrarenal abdominal aorta to the common iliac arteries with a 14×7 mm Y graft and reconstruction of inferior mesenteric artery. Histopathologically, the abdominal aorta demonstrated wide myxoid degeneration and Elastica van Gieson staining showed fragmentation of the media, reduction and disappearance of elastic fibers, and cystic medial degeneration. Intimal thickening was also observed (Fig. 3).

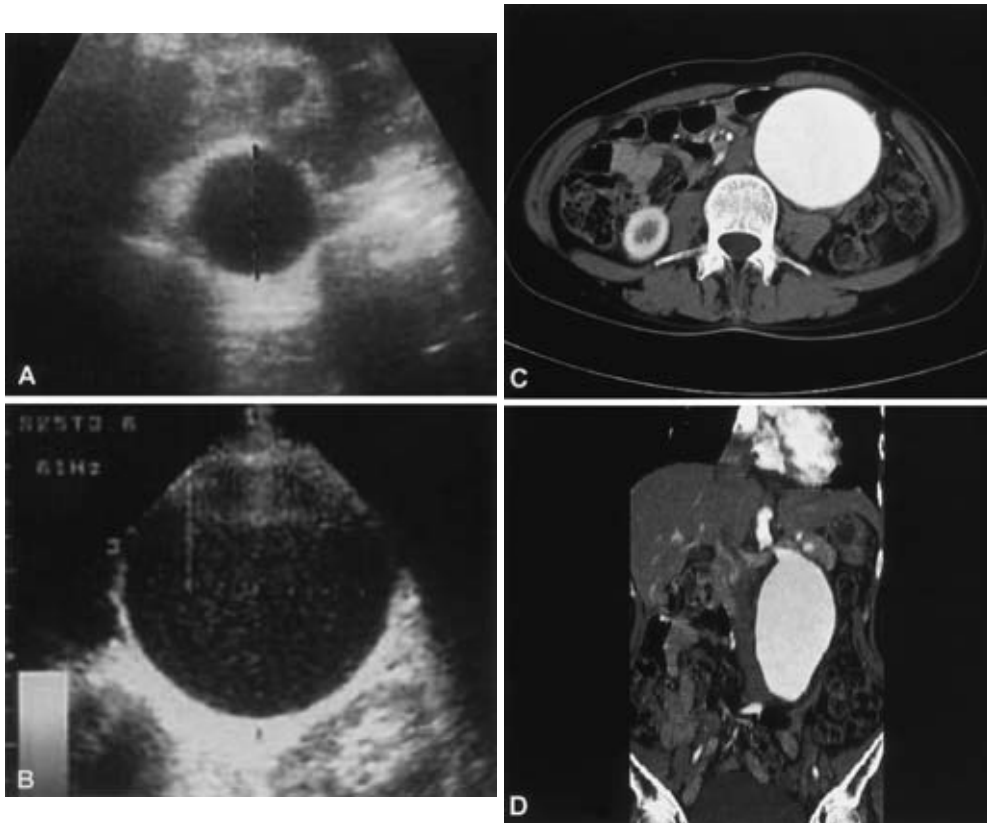
After ceasing lactation, the patient had been administered 25 mg/day of atenolol since August 13, 2005. Under medication with atenolol, her blood pressure was kept stable at about 92-104/58-62 mmHg. However, about one year after delivery (December 11, 2005), the patient complained of severe back pain and was diagnosed with acute thoracic aortic dissection (Stanford type B) (Fig. 4). Initial therapeutic goals were set to eliminate pain by administering intravenous morphine sulfate and reducing systolic blood pressure to 100 to 120 mmHg by continuous intravenous infusion of nicardipine. After reducing systolic blood pressure to optimal levels, we increased the dose of atenolol from 25 mg/day to 50 mg/day. The patient visits our outpatient clinic once a month and her blood pressure is well controlled around 88-90/58-68 mmHg. A thrombotic occlusion has so far not occurred.

---

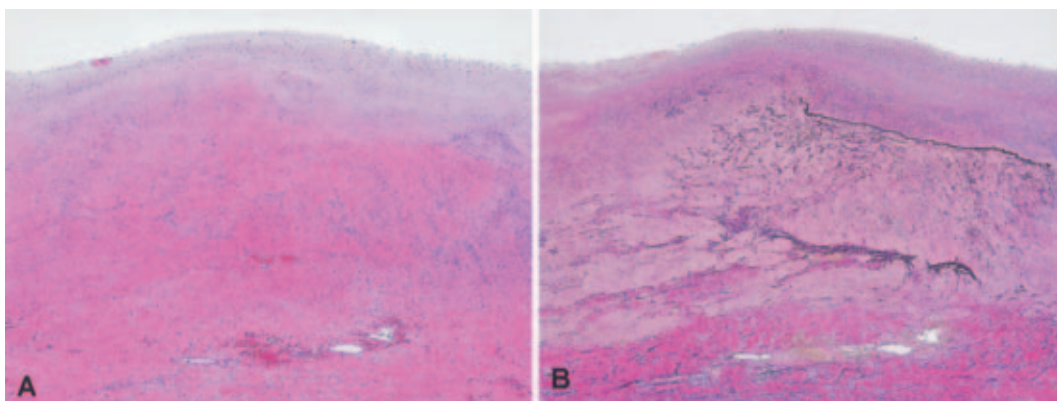
## Discussion

---

Patients with Marfan's syndrome present with variable cardiovascular features, such as mitral valve prolapse, mitral regurgitation, aortic root dilatation, and aortic valve incompetence (1, 2, 5). Pregnancy is known to be a crucial risk factor as it imposes substantial cardiovascular stress (4-7) and accelerates the development of pathologic changes in the arterial wall (6), leading to the possibility of dilatation, dissection, and rupture of the aorta with progression of pregnancy (4-7). Dissection and rupture of the aorta carry a high risk of maternal and fetal mortality (6); hence, women with Marfan's syndrome with dilatation of the aortic root



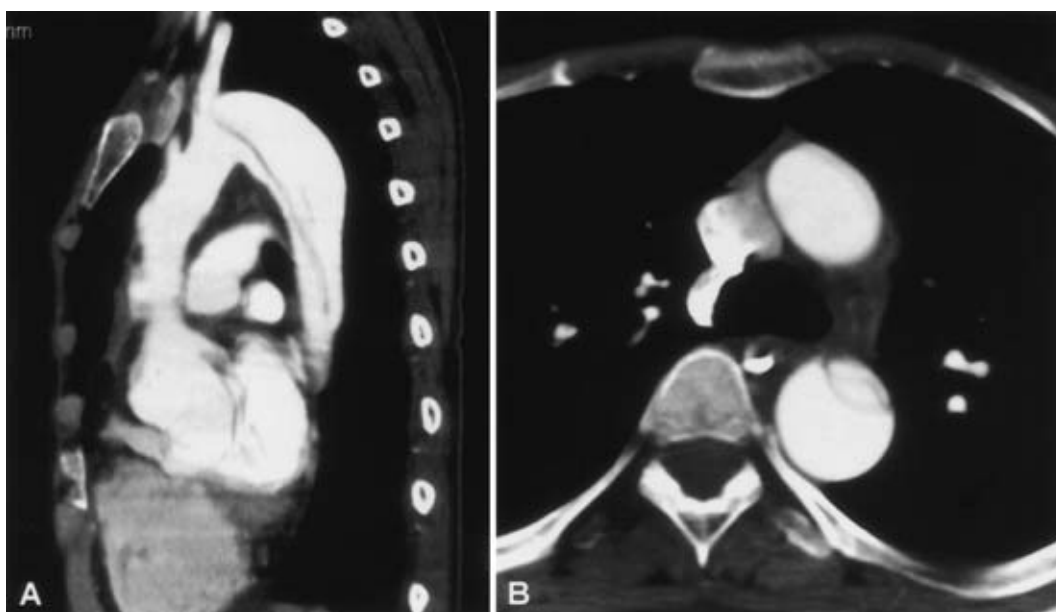
**Figure 2.** Echographic changes of the abdominal aorta. A) The diameter of the abdominal aorta was 4 cm during the 31st week of gestation. B) Eight months after delivery, the maximum diameter of the abdominal aorta increased to 8 cm, forming an infrarenal spindle-shaped true abdominal aortic aneurysm. C) Eight months after delivery, axial CT image shows the maximum diameter of the abdominal aorta increased to 79 × 76 mm. D) Multiplanar reformatted coronal image of CT reveals forming an infrarenal spindle-shaped true abdominal aortic aneurysm.



**Figure 3.** Histopathologic findings of the resected abdominal aortic aneurysm. A) The wall of the abdominal aorta showed intimal thickening and myxoid degeneration of the media (HE stain, ×25). B) The wall showed fragmentation of the media, reduction and disappearance of elastic fibers and cystic medial degeneration (Elastica van Gieson stain, ×25).

have previously been recommended to avoid pregnancy (8). Recently, however, new guidelines on pregnancy for women with Marfan's syndrome have been established, which indicate that women with an aortic root diameter of less than 40 mm rarely encounter serious problems (9-11). Other reports

have mentioned relatively minor risk when the aortic root diameter is less than 45 mm (3). Nonetheless, debate continues regarding the aortic root diameter above which pregnancy should be discouraged in women with Marfan's syndrome. In the present case, the patient's aortic root meas-



**Figure 4.** A) Multiplanar reformatted image of contrast-enhanced CT (left anterior oblique view) clearly showed aortic dissection (Stanford type B). The intimal flap originated just distal to the left subclavian artery and extended distally into the thoracic aorta at the level of the pulmonary trunk. B) Contrast-enhanced CT axial image of the chest at the level of the aorto-pulmonary window showed an intimal flap separating the true and false lumina of an aortic dissection of the descending thoracic aorta.

ured 42 mm at the beginning of pregnancy. Although we strongly recommended termination of pregnancy according to the existing guidelines (9-11), the patient and her family were eager to continue the pregnancy. Fortunately the patient did not develop enlargement of the aortic root and uneventfully delivered a female child by cesarean section.

The most serious pregnancy-related complication in Marfan's syndrome is aortic dissection, most of which involve the ascending aorta (3, 4, 6). The complication of Stanford type B dissection can also develop before and during delivery, however, it rare for this to develop after delivery (3, 4, 6, 12). It appears that the present patient developed a large true abdominal aortic aneurysm within 3 months of delivery; this type of complication has not previously been reported. Furthermore, she also developed Type B dissection in the thoracic aorta about one year after delivery. To the best of our knowledge, this is the first case in which both the development of true abdominal aortic aneurysm and thoracic aortic dissection occurred within one year after delivery.

It is reported that the gravid uterus causes significant compression of the aorta and iliac arteries, particularly in the supine position (13) and possibly increases the outflow resistance of the lower arterial tree, thereby concurrently increasing cardiac ejection of blood into the upper aorta (14). After delivery, compression of the abdominal aorta by the gravid uterus suddenly disappears, causing a sudden increase in blood flow in the abdominal aorta. In the present patient, this might have caused rapid expansion of the true abdominal aortic aneurysm. Besides this hemodynamic mechanism, hormonal changes might influence the strength of the vessel

wall. Peripartum hormonal changes are reported to cause fragmentation of the reticular fibers, reduction in the amount of acid mucopolysaccharides, and loss of the normal corrugation of elastic fibers (15). If these changes develop in a patient with Marfan's syndrome, in whom synthesis of microfibrils were impaired, dissection of the aorta could easily occur. In the light of the present case, it is necessary to follow up patients carefully with close examination of the descending aorta not only during pregnancy but also after delivery.

Since  $\beta$ -blockers reduce left ventricular ejection and lower the heart rate (16), they are recommended to slow aortic dilatation and reduce the risk of developing aortic complications in some patients with Marfan's syndrome (11, 16, 17). Controversy exists regarding the teratogenic effects of  $\beta$ -blockers in the peripartum period. Some studies show that  $\beta$ -blockers are not teratogenic (18), and others mention that even long-term treatment with  $\beta$ -blockers is safe (16, 19). According to these reports, the use of  $\beta$ -blockers is recommended during pregnancy in Marfan's syndrome (10, 11, 17, 20). However, studies have reported lower birth weight in association with exposure to atenolol during gestation (21) and the excretion of  $\beta$ -blockers in breast milk (22). Since the patient's blood pressure was low we were concerned about possible detrimental effects both on the patient and fetus, we were reluctant to use  $\beta$ -blockers during either pregnancy or lactation. Despite taking  $\beta$ -blockers for four months since discontinuing lactation, thoracic aortic dissection developed. In type B aortic dissection, the relation between the aortic dimensions and the size of the dissection is

not clear and prediction of such an event is very difficult in Marfan's syndrome. Moreover, aortic dissection can occur in pregnancy without pre-existing disease, probably due to hormonal changes or increased cardiovascular stress of pregnancy. Recently angiotensin converting enzyme (ACE) inhibitors have been introduced for the prevention of cardiovascular events in Marfan's syndrome by either reducing

smooth muscle cell apoptosis (23), or downregulation of TGF- $\beta$  signaling to the extracellular matrix (24). However, neither ACE inhibitors or angiotensin receptor blockers can be used during pregnancy owing to their teratogenicity. It is emphasized that the optimal management of Marfan's syndrome requires lifelong aortic surveillance and establishment of medical treatment during pregnancy.

## References

- Cotran RS, Kumar V, Collins T. Genetic disorders in: Robbins Pathologic Basis of Disease. 6th ed. Cotran RS, Kumar V, Collins T, Eds. Saunders, Philadelphia, 1999:148-149.
- Cotran RS, Kumar V, Collins T. Blood vessels. In: Robbins Pathologic Basis of Disease. 6th ed. Schoen FJ, Cotran RS, Eds. Saunders, Philadelphia, 1999: 528.
- Meijboom LJ, Vos FE, Timmermans J, Boers GH, Zwinderman AH, Mulder BJ. Pregnancy and aortic root growth in the Marfan syndrome: a prospective study. *Eur Heart J* **26**: 914-920, 2005.
- Rossiter JP, Repke JT, Morales AJ, Murphy EA, Pyeritz RE. A prospective longitudinal evaluation of pregnancy in the Marfan syndrome. *Am J Obstet Gynecol* **173**: 1599-1606, 1995.
- Lipscomb KJ, Smith JC, Clarke B, Donnai P, Harris R. Outcome of pregnancy in women with Marfan's syndrome. *Br J Obstet Gynaecol* **104**: 201-206, 1997.
- Immer FF, Bansi AG, Immer-Bansi AS, et al. Aortic dissection in pregnancy: analysis of risk factors and outcome. *Ann Thorac Surg* **76**: 309-314, 2003.
- Pyeritz RE. Maternal and fetal complications of pregnancy in the Marfan syndrome. *Am J Med* **71**: 784-790, 1981.
- Shabetai R. Cardiac disease. In: Maternal-fetal Medicine: Principles and Practice. 3rd ed. Creasy RK, Resnick R, Eds. Saunders, Philadelphia, 1994: 768-791.
- Task Force on the Management of Cardiovascular Diseases During Pregnancy of the European Society of Cardiology. Expert consensus document on management of cardiovascular diseases during pregnancy. *Eur Heart J* **24**: 761-781, 2003.
- Nakazawa M, Aomi S, Akagi T, et al. Guidelines for indication and management of pregnancy and delivery in women with heart disease (JCS 2005). *Circ J* **69** (Supply IV) : 1296-1297, 2005 (in Japanese).
- Therrien J, Gatzoulis M, Graham T, et al. Canadian cardiovascular society consensus conference 2001 update: Recommendations for the management of adults with congenital heart disease Part II. *Can J Cardiol* **17**: 1029-1050, 2001.
- Maruyama T, Totsuka N, Akahane K, et al. Two cases of Marfan syndrome complicated with aortic dissection during pregnancy. *Kokyu To Junkan* **41**: 85-88, 1993 (in Japanese, Abstract in English).
- Ohlson L. Effects of the pregnant uterus on the abdominal aorta and its branches. *Acta Radiol Diagn (Stockh)* **19**: 369-376, 1978.
- Wheat MW. Intensive drug therapy. in: Aortic dissection. Dorghazi S, Ed. McGraw-Hill, New York, 1983: 55-60.
- Manalo-Estrella P, Barker AE. Histopathologic findings in human aortic media associated with pregnancy. *Arch Pathol* **83**: 336-341, 1967.
- Shores J, Berger KR, Murphy EA, Pyeritz RE. Progression of aortic dilatation and the benefit of long-term  $\beta$ -adrenergic blockade in Marfan's syndrome. *N Engl J Med* **330**: 1335-1341, 1994.
- Milewicz DM, Dietz HC, Miller DC. Treatment of aortic disease in patients with Marfan syndrome. *Circulation* **111**: e150-157, 2005.
- Rubin PC. Current concepts: beta-blockers in pregnancy. *N Engl J Med* **305**: 1323-1326, 1981.
- Hogstedt S, Lindeberg S, Axelsson O, et al. A prospective controlled trial of metoprolol-hydralazine treatment in hypertension during pregnancy. *Acta Obstet Gynecol Scand* **64**: 505-510, 1985.
- Elkayam U, Ostrzeza E, Shotan A, Mehra A. Cardiovascular problems in pregnant women with the Marfan syndrome. *Ann Intern Med* **123**: 117-122, 1995.
- Lardoux H, Gerard J, Blazquez G, Chouty F, Flouvat B. Hypertension in pregnancy: evaluation of two beta blockers atenolol and labetalol. *Eur Heart J* **4**(Supply G): 35-40, 1983.
- Liedholm H, Melander A, Bitzen PO, et al. Accumulation of atenolol and metoprolol in human breast milk. *Eur J Clin Pharmacol* **20**: 229-231, 1981.
- Nagashima H, Sakomura Y, Aoka Y, et al. Angiotensin II type 2 receptor mediates vascular smooth muscle cell apoptosis in cystic medial degeneration associated with Marfan's syndrome. *Circulation* **104**(Supply I): 1282-1287, 2001.
- Habashi JP, Judge DP, Holm TM, et al. Losartan, an AT1 antagonist, prevents aortic aneurysm in a mouse model of Marfan syndrome. *Science* **312**: 117-121, 2006.