

**Surgical Technique**

**A Jejunal Wall-Covering Method following Central Pancreatectomy  
for Prevention of a Pancreatic Fistula: A Novel Technique**

**Tamotsu Kuroki, Yoshitsugu Tajima, Noritsugu Tsuneoka, Takehiro  
Mishima, Tomohiko Adachi, Amane Kitasato, and Takashi Kanematsu**

Department of Surgery, Nagasaki University, Graduate School of  
Biomedical Sciences, 1-7-1 Sakamoto, Nagasaki 852-8501, Japan.

Running title: Jejunal wall-covering method for the prevention  
of a pancreatic fistula.

Reprint requests to: T. Kuroki

FAX 81-95849-7319

e-mail tkuroki-gi@umin.ac.jp.

**ABSTRACT**

To preserve pancreatic endocrine and exocrine function, various types of pancreatic resection, including central pancreatectomy, have been introduced as less invasive surgeries. However, postoperative pancreatic leakage has been demonstrated to be the most frequent complication following pancreas-preserving surgery. Our new surgical technique, a jejunal wall-covering method, helps to prevent pancreatic leakage following central pancreatectomy.

Keywords: Jejunal wall-covering method, pancreatic fistula, central pancreatectomy.

## **INTRODUCTION**

Central pancreatectomy, proposed by Letton and Wilson [1] in 1959, has been used for the surgical treatment of traumatic transection of the pancreas. Subsequently, several reports have suggested that the central pancreatectomy has the advantage of being a less invasive surgery for treating benign and low-grade malignant pancreatic tumors [2, 3]. On the other hand, a pancreatic fistula has been the most frequent complication from this procedure and is still responsible for most mortalities that occur after pancreatic surgery [4]. Recently, we have reported a gastric wall-covering method, a new surgical technique in pancreatic surgery, for the prevention of a pancreatic fistula in which the pancreatic cut surface is covered completely with the gastric wall [5]. Herein, we describe a new surgical procedure for a jejunal wall-covering method to follow central pancreatectomy for the prevention of a pancreatic fistula at the proximal stump of the pancreas.

## **PATIENTS AND TECHNIQUE**

Between 1991 and 2005, 6 patients underwent a central pancreatectomy in our department. Among these patients, one showed a postoperative pancreatic fistula of a grade C, in terms of the degrees proposed by an international study group on pancreatic fistula (ISGPF) [6]. This patient developed a splenic arterial pseudoaneurysm, resulting in a lethal intra-abdominal hemorrhage. In an attempt to avoid the pancreatic fistula and subsequent dismal complications following central pancreatectomy in April, 2006, we introduced a new surgical procedure, a "jejunal wall-covering method". Three patients underwent the jejunal wall-covering method following a central pancreatectomy. Indications for this procedure included intraductal papillary-mucinous neoplasm (IPMN) (n=3) and solid-pseudopapillary tumor (n=1) on the body of the pancreas. All patients had a soft pancreas with non-fibrotic parenchyma. No patients showed any postoperative complications, including a pancreatic fistula.

*Surgical technique*

After an upper abdominal midline incision, the lesser sac was entered, and the pancreas was exposed. The splenic artery and vein were separated from the pancreas to secure a surgical margin. The central segment of the pancreatic parenchyma harboring the tumor was transected along the margins of the proximal and distal pancreas (Fig. 1A). The distal pancreas was reconstructed by an end-to-side pancreaticojejunostomy using a retrocolic Roux-en-Y jejunal loop. After the pancreaticojejunostomy, the jejunal wall-covering method was performed as follows. The main pancreatic duct of the proximal stump was isolated from the surrounding pancreatic parenchyma and was ligated securely. The bleeding points on the cut edge of the proximal pancreas were oversewn with interrupted mattress sutures using 4-0 absorbable monofilament sutures. Furthermore, the pancreatic cut surface was fixed to the jejunal wall at approximately 10 cm distal to the pancreaticojejunostomy. This surrounding anastomosis was constructed by interrupted suturing between the pancreatic parenchyma and the seromuscular layer of the jejunum with 4-0 absorbable monofilament sutures (Fig. 1B). As a consequence, the

stump of the pancreas was completely covered by the jejunal wall (Fig. 1C). This surrounding anastomosis was composed of 8-12 sutures. Furthermore, we made sure there was no torsion of the jejunal loop.

## **DISCUSSION**

Central pancreatectomy is a less invasive surgery for the benign and low-grade malignant pancreatic tumors that are localized in the neck and body of the pancreas [2, 3]. Compared with the conventional surgical procedures such as pancreaticoduodenectomy and distal pancreatectomy, central pancreatectomy has the advantage of preserving pancreatic endocrine and exocrine function. On the other hand, central pancreatectomy involves two pancreatic cut surfaces. Usually, the distal pancreatic stump is reconstructed by a Roux-en-Y jejunal loop, and the proximal stump is closed by means of sutures or a stapler. A pancreatic fistula is one of the most frequent complications after pancreatic resections, including central pancreatectomy [3]. In performing a central pancreatectomy, we believe that the key factor for the prevention of a pancreatic fistula is the management of the small branches of the pancreatic duct that communicate with the main duct on the proximal pancreatic cut surface [4]. The jejunal loop may be an ideal material for covering the proximal pancreatic stump in a central pancreatectomy that involves reconstruction of the distal

pancreas in the fashion of the retrocolic Roux-en-Y jejuno-pancreatic anastomosis because it lies adjacent to the proximal pancreatic stump. Therefore, no additional surgical manipulation is required. In addition, the jejunal wall is thick, wide and flat with abundant blood supply and is thus applicable for the covering method. Our technique is simple, technically feasible, secure, and useful for the prevention of a pancreatic fistula in patients undergoing central pancreatectomy.



**REFERENCES**

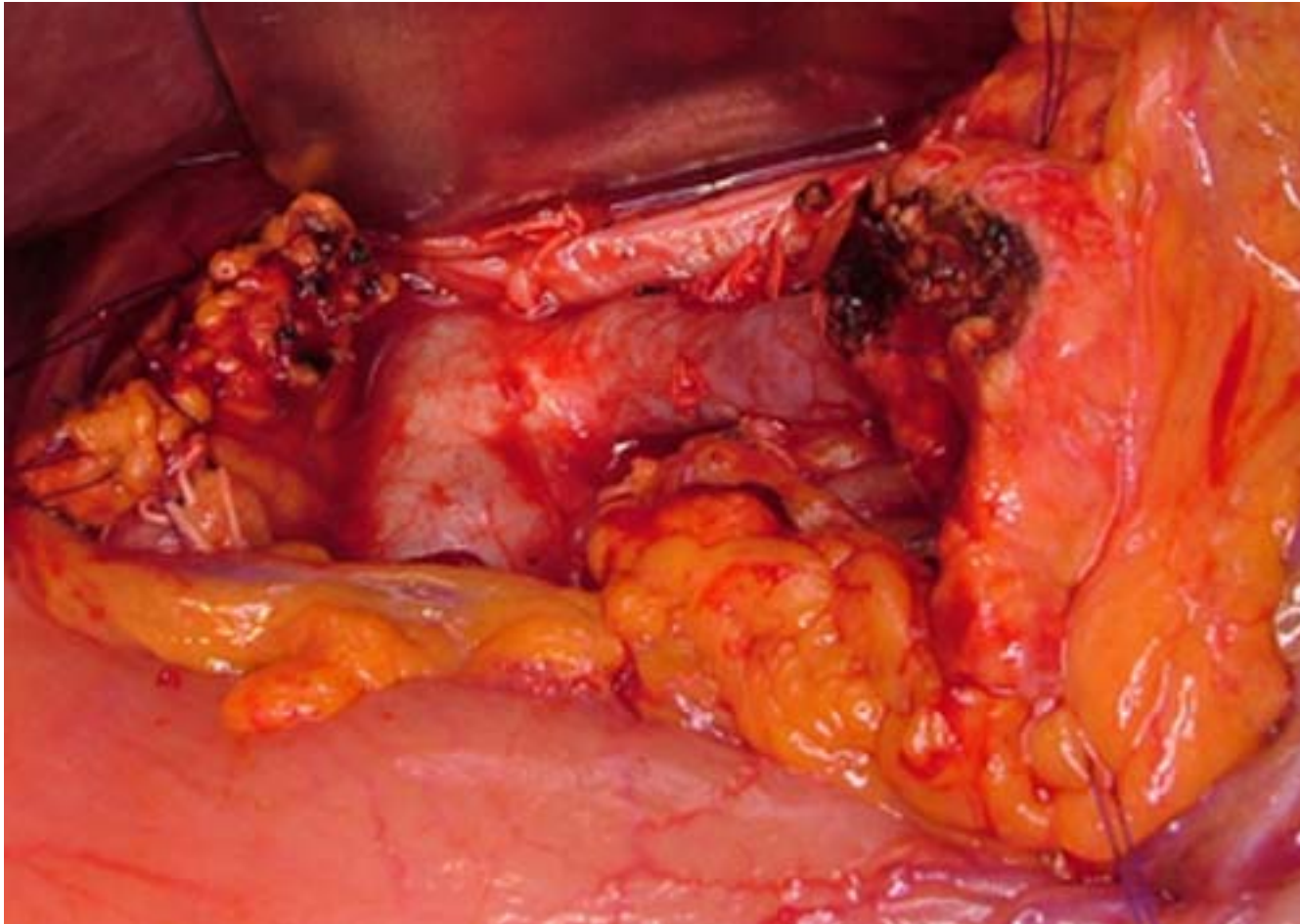
1. Letton AH, Wilson JP. Traumatic severance of pancreas treated by Roux-Y anastomosis. *Surg Gynecol Obstet* 1959;109:473-478.
2. Sperti C, Pasquali C, Ferronato A, Pedrazzoli S. Median pancreatectomy for tumors of the neck and body of the pancreas. *J Am Coll Surg* 2000;190:711-715.
3. Iacono C, Bortolasi L, Serio G. Is there a place for central pancreatectomy in pancreatic surgery? *J Gastrointest Surg* 1998;2:509-516.
4. Kuroki T, Tajima Y, Kanematsu T. Surgical management for the prevention of pancreatic fistula following distal pancreatectomy. *J Hepatobiliary Pancreat Surg* 2005;12:283-285.
5. Kuroki T, Tajima Y, Tsutsumi R, Mishima T, Kitazato A, Adachi T, Kanematsu T. Inferior branch preserving superior head resection of the pancreas with gastric wall covering method for intraductal papillary mucinous adenoma. *Am J Surg* 2006;191:823-826.
6. Bassi C, Dervenis C, Butturini G, Fingerhut A, Yeo C, Izbicki J, Neoptolemos J, Sarr M, Traverso W, Buchler M; International

Study Group on Pancreatic Fistula Definition. Postoperative pancreatic fistula: an international study group (ISGPF) definition. *Surgery*. 2005;138:8-13.

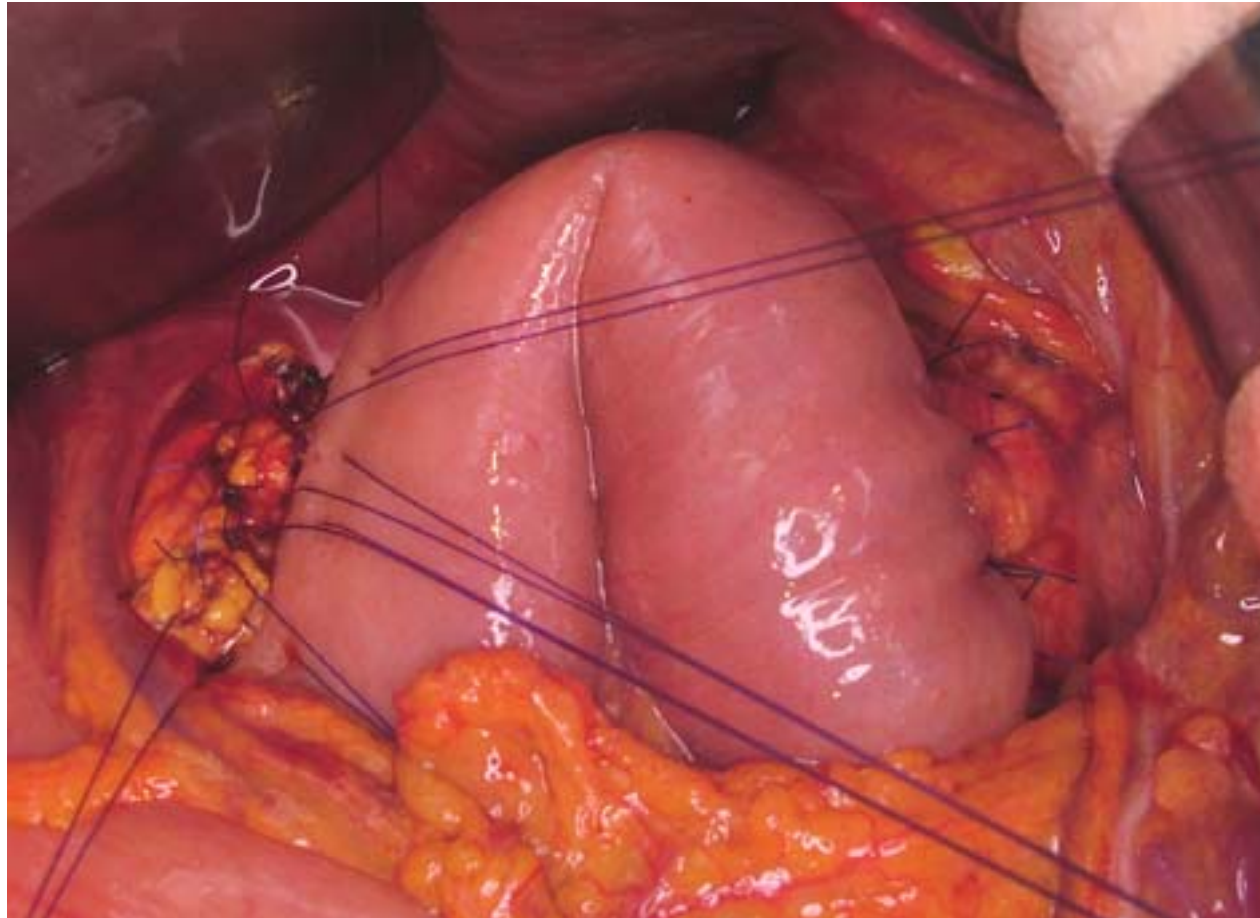
**FIGURE LEGENDS**

**Fig. 1.** The novel surgical procedure of the "jejunal wall-covering method" in a central pancreatectomy. **A** The central segment of the pancreatic parenchyma harboring the tumor is transected along the margins of the proximal and distal pancreas. **B** After performing an end-to-side pancreaticojejunostomy, the fixation between the proximal cut end of the pancreas and the seromuscular layer of the jejunum is constructed by suturing with 4-0 absorbable monofilament sutures. **C** The pancreatic proximal cut surface following the central pancreatectomy is completely covered by the jejunal wall of the Roux-en-Y jejunal loop.

**Fig.1.A**



**Fig.1.B**



**Fig.1.C**

