

High Frequency Jet Ventilation (HFJV) in Infants with Cyanotic Heart Disease during Open-Heart Surgery

Yoshio HAYANO, Takayuki NOGUCHI, Shunsuke ODA

Kazuo TANIGUCHI and Natsuo HONDA

Dept. of Anesthesiology, Medical College of Oita, Oita

Received for publication, June 30, 1986

ABSTRACT

As an anesthetic ventilation, high frequency jet ventilation (HFJV) was applied to open-heart surgery in infants with cyanotic heart disease. A total of four patients were anesthetized with this HFJV. Two of them had cyanotic heart disease and the remainder, acyanotic one. The results of blood gas analysis were stable in each patient, and PaO₂ was not decreased even in patients with cyanotic heart disease with low pulmonary blood flow who might be influenced markedly by changes in alveolar pressure. In addition, hemodynamics was stable, and for surgeons, HFJV provided good accessibility to the surgical field and surgical procedure was facilitated. Taken altogether, HFJV is considered a very useful method.

INTRODUCTION

When infants with cyanotic heart disease are anesthetized, arterial oxygen levels may be decreased, if intrathoracic pressure is elevated excessively during artificial ventilation. However, since artificial ventilation cannot be avoided during surgery, especially open heart surgery, in such patients, manual ventilation has so far been performed carefully. On the other hand, high-frequency ventilation has the advantage that the motion of the lungs is small and effective ventilation can be performed while intrathoracic pressure is kept low hemodynamics is kept stable. (1-8) In the present study, therefore, we applied this HFJV to cardiac surgery in four infants with cyanotic heart disease, etc. and obtained good

results. This report describes that HFJV is useful for respiratory management during anesthesia in patients with cyanotic heart disease.

MATERIALS AND METHODS

A total of four patients were included in the present study. As cyanotic heart disease cases with low pulmonary blood flow, a 11-month-old male with tetralogy of Fallot and a male aged one year and one month with pentalogy of Fallot plus PDA were studied. As acyanotic heart disease cases with high pulmonary blood flow, a female aged two years and eight months with VSD associated with marked pulmonary hypertension and a one-year-old female with PDA were studied. In each patient, formation of shunt, closure of VSD under an artificial heart-lung machine or ligation of PDA was performed surgically. Anesthesia was induced by intramuscular injection of ketamine in all patients and maintained with high-dose morphine in one and high-dose fentanyl in three. In all patients, manual ventilation was performed using Jackson-Ree's circuit during induction, while ventilation by HFJV was carried out using VS600 of IDC Co. after intubation. HFJV was used under the conditions of frequency, 150 to 200/min; driving pressure, 6 to 8 psi; and IT%, 30 to 50%. During anesthesia, each patient was given pancuronium and was monitored by ECG, arterial pressure and CVP, and arterial blood gas analysis was carried out appropriately.

RESULTS

In patients with cyanotic heart disease with low pulmonary blood flow, neither depressed PaO_2 nor elevated PaCO_2 was noted, (Fig. 1 and 2) and blood pressure was stable. In one patient with the most remarkable cyanosis who might be influenced to a large extent by changes in intrathoracic pressure, the blood pressure showed a marked change only when the lungs were expanded with a bag after shunt formation (Fig. 3). In two patients with acyanotic heart disease with high pulmonary blood flow, PaO_2 showed a tendency toward a slight depression, but PaCO_2 was not elevated (Fig. 4). During open-heart surgery, the lungs were expanded to a lesser extent and the motion of expansion and contraction was smaller for HFJV than for ordinary ventilators. Accordingly, it was easy for surgeons to observe a surgical field and carry out surgical manipulation. Further, neither blood pressure nor CVP showed any marked change.

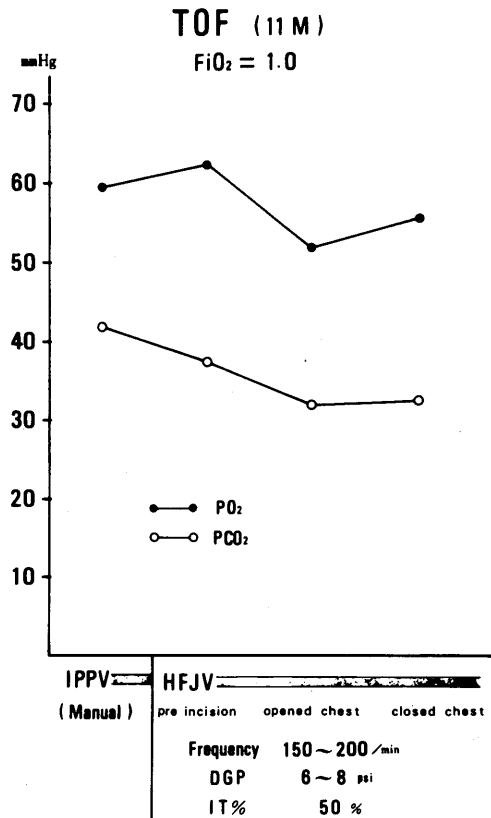


Fig. 1.

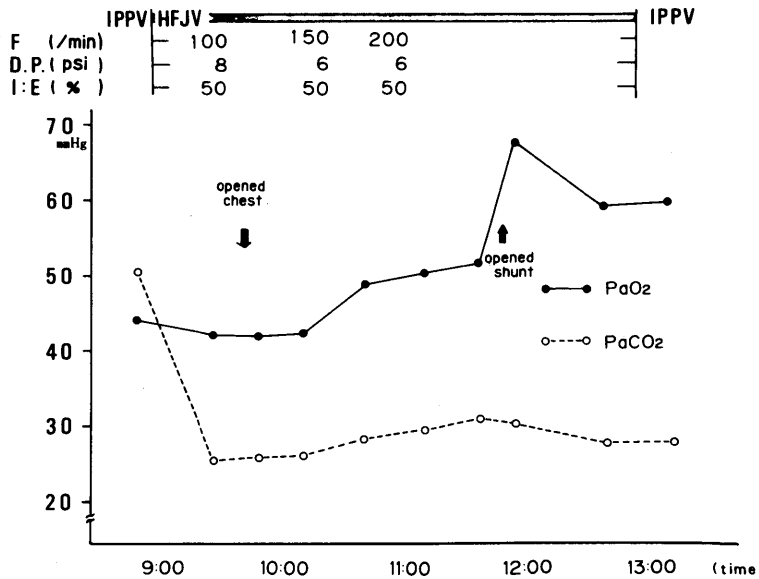


Fig. 2.

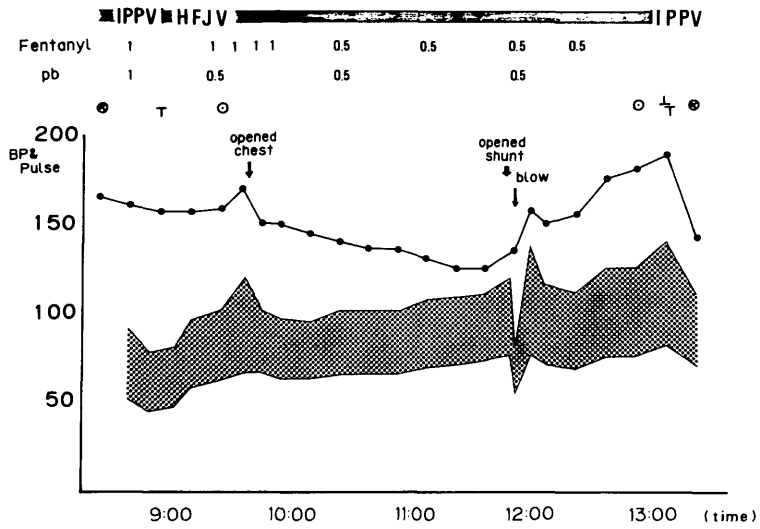


Fig. 3.

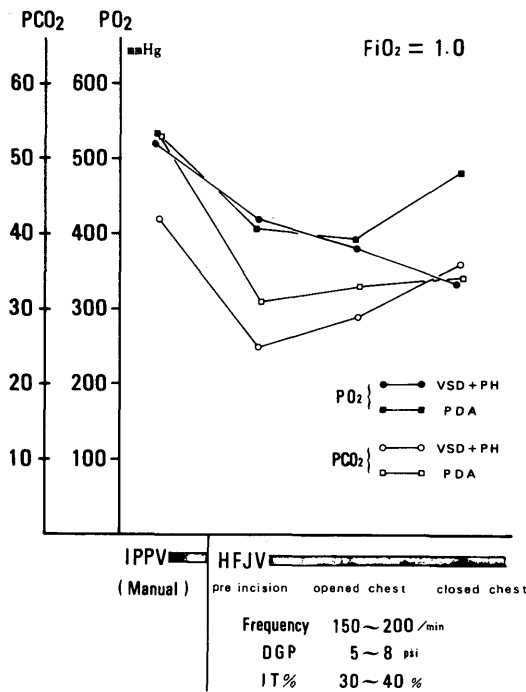


Fig. 4.

DISCUSSION

Only a few anesthetic ventilators are available for infants. (6) But, ventilation must be performed carefully, especially in cyanotic heart-disease patients with a right-to-left shunt, because elevated alveolar pressure due to artificial ventilation may elicit elevated pressure in the right cardiac system, resulting in changes in the circulatory system, increased shunts and abnormal arterial gases. Further, positive-pressure ventilation, which is essential for open-heart surgery, has so far been performed mainly by manual ventilation. On the other hand, HFJV has the advantages that satisfactory ventilation can be achieved regardless of small tidal volume, and movement of lungs can be fine while alveolar pressure is kept low and hemodynamics is stable. (1-5) This method seems especially useful for artificial ventilation in patients with cyanotic heart disease. It is also advantageous that the device required for this method is simple and compact. Further, it is extremely desirable for complicated surgery within a very small surgical field, (6) such as vascular anastomosis, that the lungs are expended to a lesser extent, and therefore, their motion is minimized during ventilation. In the present study, these advantages of HFJV could be utilized sufficiently and satisfactory results could be obtained for ventilation. HFJV could be used effectively under the condition of frequency, 150 to 200/min; driving pressure, 6 to 8 psi; and IT%, 30 to 50%. However, since the compliance of the lungs and thorax and diameter of endotracheal tubes may vary with each patient, it seems necessary to carefully determine the conditions of HFJV. Further, HFJV must always be used in an open system to prevent an elevation in alveolar pressure and occurrence of barotrauma, and, during ventilation with HFJV, careful observation by direct arterial pressure is considered absolutely necessary, since alveolar pressure may be elevated depending upon the operation of HFJV. In the present study, VS600 of IDC Co. was used as HFJV, and the driving pressure used was its lowest effective pressure. It seems necessary to develop equipment with a more delicate driving-pressure range. When HFJV was used under the same conditions in patients with acyanotic heart disease with high pulmonary blood flow, PaO_2 was slightly decreased, presumably because ventilation was slightly decreased due to excess pulmonary blood flow. However, since PaO_2 was sufficiently high before operation and the degree of its depression was too small to present any particular problem. Further, surgical procedure was facilitated with this ventilator. Taken altogether, HFJV was considered very useful.

It is necessary to carry out further studies on HFJV, because it is considered a very useful ventilation, though the present study had to be conducted on a few cases.

REFERENCE

- 1) DAVEY, A. J. *et al.*: *Anaesthesia* 37 : 670-674, (1982).
- 2) HAYANO, Y. *et al.*: *J. Jap. Soc. Clin. Anesthesia* 4 : 79-83 (1984) (Japanese).
- 3) HILDERBRAND, P. J.: *Anaesthesia* 39 : 1091-1095 (1984).
- 4) INOUE, T. *et al.*: *Jap. J. Anesthesiol.* 30 : 1225-1233 (1981) (Japanese).
- 5) MALINA, J. R.: *Anesthesia and Analgesia* 60 : 324-330 (1981).
- 6) MURAT, I.: *Ann. Fr. Anesth. Rean.* 2 : 270-272 (1983)
- 7) SUWA, K.: *Kokyu to Junkan* 29 : 589-594 (1981) (Japanese).
- 8) SUWA, K.: *Kokyu to Junkan* 29 : 829-834 (1981) (Japanese).