

Case Report

Successful Repeated Transcatheter Arterial Embolization (TAE) for Multiple Liver Metastases from Breast Cancer

Shigetoshi MATSUI¹⁾, Susumu EGUCHI¹⁾, Takashi AZUMA¹⁾, Masaaki HIDAHA¹⁾, Satoshi YAMAGUCHI¹⁾, Shiro OBATA²⁾, Takashi KANEMATSU³⁾

1) Department of Surgery, Nagasaki Prefectural Shimabara Onsen Hospital

2) Department of Radiology, Nagasaki Prefectural Shimabara Onsen Hospital

3) Second Department Surgery, Nagasaki University School of Medicine

A 46-year-old female was successfully treated with repeated transcatheter arterial embolization (TAE) for multiple liver metastases from breast cancer. TAE using mitomycin C and epirubicin hydrochloride with lipiodol emulsion and gelatin sponge particles has been administered to the patient eight times over 4 years. She has also received systemic chemotherapy. She has survived for 6 years and 3 months after the detection of liver metastases.

ACTA MEDICA NAGASAKIENSIA 46 : 81-83, 2001

Key Words: breast cancer, liver metastasis, arterial embolization

Introduction

Hepatic metastases has been the most life-threatening recurrent disease in breast cancers¹. Systemic chemotherapy or regional therapy, i. e., hepatic arterial infusion chemotherapy and/or hepatic resection, have been tried for liver metastases²⁻⁷. However, no definite results of these trials have been reported. We herein review a case with multiple liver metastases from breast cancer successfully treated with systemic and regional chemotherapies.

Case report

A 46-year-old female underwent a standard radical mastectomy for left breast cancer on September, 1989.

Address Correspondence: Shigetoshi Matsuo, M.D.
Department of Surgery, Nagasaki Prefectural Shimabara Onsen Hospital, 7895 Shimokawajiri, Shimabara, Nagasaki 855-0861, Japan
TEL: +81-957-63-1145 FAX: +81-957-63-4864

Histological examination revealed an invasive ductal carcinoma, while a hormonal evaluation of tumor tissues showed that estrogen and progesterone receptors were both positive. An excision of the chest wall with linac irradiation, a right mastectomy, and repeated skin excisions caused by local recurrences and metastases from the left breast cancer were consecutively performed during the period of March 1993 and July 1994. On September 1994, computed tomography (CT) initially showed multiple liver metastases, measuring 3.5 cm (S4) and 2 cm (S3) in diameter (Fig.1), with an elevation of serum CA 15-3 levels (240 U/ml, normal range:<27 U/ml) which is an indicator of distant metastases from breast cancer. Enhanced CT showed ring-enhancement and partly iso to low density in the late phase (Fig.2). Owing to the treatment with tamoxifen, 5-fluorouracil (5-FU) and cyclophosphamide, the size of liver tumors have not changed and serum levels of CA 15-3 ranged from 26 to 84 U/ml for one year and five months. CT examination showed that




Figure 1. Plain CT showed low density masses in the liver. arrowheads: S3, arrows: S4

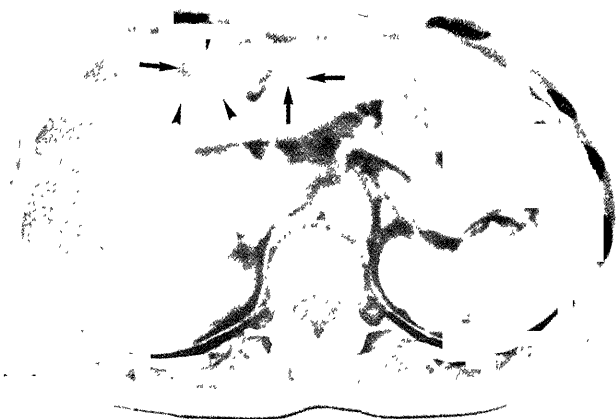


Figure 2. Enhanced CT showed ring-enhancement (arrow-heads), and iso to low enhancement (arrows) in the late phase.



Figure 4. Enhanced CT revealed strong lipiodol-deposits in the liver tumor after the first TAE.




Figure 3. Selective hepatic angiography revealed diffuse hypervascular tumor staining.

metastatic liver tumor of the S4 segment had gradually increased in size, measuring about 4.5 cm in diameter on December 1995. Angiography revealed diffuse hypervascularity (Fig.3). The first transcatheter arterial embolization (TAE) using 10 mg of mitomycin C, 30 mg of epirubicin hydrochloride with lipiodol emulsion and gelatin sponge particles was performed on February, 1996 (Fig.4). The S4 lesion obviously decreased in size; however, complete remission was not revealed by CT examination on May 1996. We evaluated that TAE was effective and that another TAE was necessitated for this patient. The second TAE was performed on June 1996. Finally, eight courses of TAE with the same regimen and the same doses was completed by February 2000. She also received a systemic treatment with aromatase inhibitor, 5-FU, and medroxyprogesteron which had begun on October 1998. The size of liver tumors showed a partial

remission or no change, and serum levels of CA 15-3 ranged from 28 to 115 U/ml, by the 4th TAE on August 1997. Although the hyperbilirubinemia and the elevation of serum levels of CA 15-3 (195 U/ml) and carcinoembryonic antigen (289 ng/ml, normal range: <5 ng/ml) were present before the 5th TAE on September 1998, the bilirubin level was within the normal limits after the 5th TAE. Metastatic tumors developed in another segment of the liver after this time. She died on December 2000 due to the hepatic failure because of multiple liver metastases and another recurrences such as in the pleura, the mediastinum, and the pericardium. She had survived for 58 months after the first TAE and 6 years and 3 months after the detection of liver metastases.

Discussion

The results of systemic chemotherapy for hepatic metastases from breast cancer have been disappointing, showing a short response time in spite of high response rates^{2,4}. Therefore, regional treatments have been proposed for improvement of survival. Hepatic arterial infusion chemotherapy (AI) has been performed for liver metastases from breast cancer, and the median survival is reported to be 11 to 25.3 months^{3-5,7}. In our experience, AI has been performed in 2 patients and TAE in 3 patients. A patient with liver metastases solely who was treated with AI has survived for two years after its detection. Repeated TAE was performed only in this case, but there have been no reports of TAE therapy for liver metastases from breast cancer. The present patient has survived for 6 years and 3 months after the detection of liver

metastases, and 58 months after the first TAE, in spite of the presence of extrahepatic metastases. Among patients who received AI chemotherapy only about a half of them responded and the survival rates of the responders were clearly superior to those of nonresponders, and 50% of the responders were alive at 18 months versus none of the nonresponders⁵. On the other hand, hepatic resection is considered to be the best treatment for liver metastasis, if feasible. The median survival of hepatic resection for these conditions in breast cancer, described in a few limited reports, ranges from 28 to 37 months⁴⁻⁶. Stehlin et al⁵ emphasized that a patient who had undergone hepatic resection plus infusion survived the longest. It is, however, still unclear whether hepatic resection is beneficial for liver metastases from breast cancer, because those patients also have extrahepatic metastases.

In conclusion, transcatheter arterial embolization may be an effective treatment for hypervascular metastatic liver tumors from breast cancer, which are localized solely or in a lobe of the liver.

References

- 1) Hagemester FBJr, Buzdar AU, Luna MA, Blumenschein GR. Causes of death in breast cancer. A clinicopathologic study. *Cancer* 46:162-167,1980.
- 2) Kemeny N. The systemic chemotherapy of hepatic metastases. *Semin Oncol* 10:148-158,1983.
- 3) Fraschini G, Fleishman G, Charnsangavej C. Continuous 5-day infusion of vinblastine for percutaneous hepatic arterial chemotherapy for metastatic breast cancer. *Cancer Treatment Report* 71:1001-1005,1987.
- 4) Schneebaum S, Walker MJ, Young D, Farrar WB, Minton JP. The regional treatment of liver metastases from breast cancer. *J Surg Oncol* 55:26-31,1994.
- 5) Stehlin JS, de Ipolyi PD, Greeff PJ, McGaff CJ, Davis BR, McNary L. Treatment of cancer of the liver. Twenty years' experience with infusion and resection in 414 patients. *Ann Surg* 208:23-35,1988.
- 6) Elias D, Lasser P, Spielmann M, May-Levin F, EL Malt O, Thomas H, Mouriesse H. Surgical and chemotherapeutic treatment of hepatic metastases from carcinoma of the breast. *Surg Gynecol Obstet* 172:461-464,1991.
- 7) Ikeda T, Adachi I, Takashima S, Ogita M, Aoyama H, Sano M, Ando J, Tabei T, Tominaga T, Enomoto K, Kanda K, Fukutomi T, Shimoyama M for the JCOG Breast Cancer Study Group. A phase I/II study of continuous intra-arterial chemotherapy using an implantable reservoir for the treatment of liver metastases from breast cancer: A Japan clinical oncology group (JCOG) study 9113. *Jpn J Clin Oncol* 29:23-27,1999.