

## A Case of Tensor Fasciae Suralis Muscle

Ryosuke MIYAUCHI, Kazushige KURIHARA and  
Gen TACHIBANA

*Department of Anatomy, Medical College  
of Oita, Oita, Japan*

Received for publication, June 30, 1985

An anomalous muscle was found on the dorsum of the right lower limb of a 67-year-old Japanese male. It originated by two heads from the semitendinosus and long head of the biceps femoris and ran distally to insert into the deep surface of the sural fascia.

The origin, insertion and location of the muscle were compared with those of the various supernumerary muscles hitherto published. The muscle is consequently regarded as being the tensor fasciae suralis. This is the fifth case in Japan.

Key words: tensor fasciae suralis muscle, biceps femoris muscle, semitendinosus muscle, sural fascia

### INTRODUCTION

In the course of anatomical dissection for students of the Medical College of Oita during 1983 school year, the present authors happened to encounter an anomalous muscle on the dorsum of the right lower limb of a male cadaver (Cadaver number 95, age 67 years old at time of death due to gastric cancer). Since such a case is very rare, the findings obtained will be reported here along with an attempt to discuss the identification of the present case.

### FINDINGS (FIGURES) AND DISCUSSION

The anomalous muscle was located immediately under the fascia of the back of the right lower limb. It had two heads, a medial and a lateral head. Approximately in the middle of the thigh, the former arose from the lateral aspect of the semitendinosus by means of a slender cylindrical tendon while the latter from the medial aspect of the long head of the biceps femoris. After running distally, both of these tendons united to form a single tendon which joined to a fusiform muscular belly in the proximity of the upper angle of the popliteal fossa. The belly passed downward and at the lower edge of the same

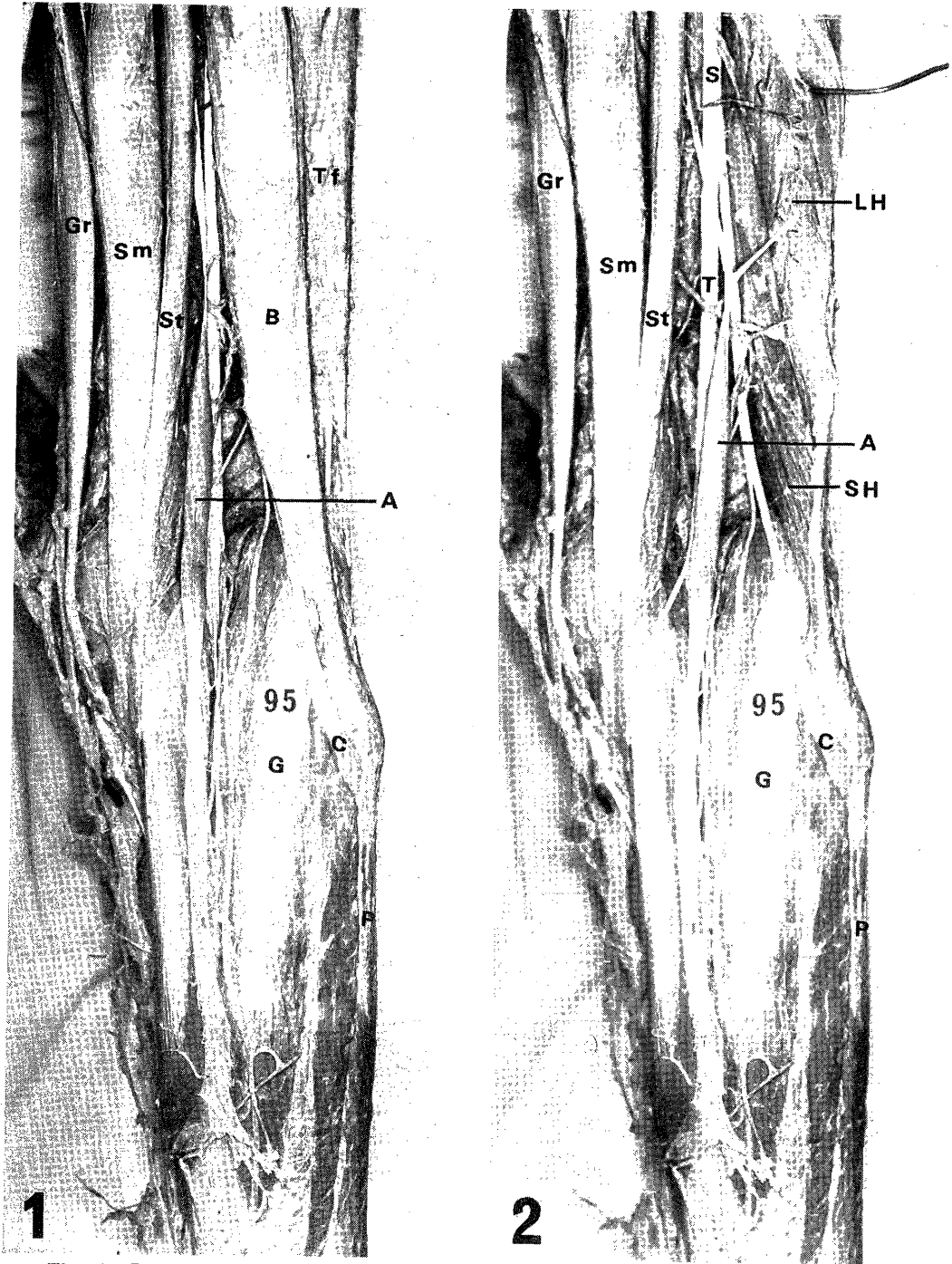


Fig. 1. Posterior view of the right leg. Fig. 2. The biceps femoris muscle has been reflected lateralwards so as to expose two heads of the anomalous muscle.

A: anomalous muscle, B: biceps femoris muscle, C: common peroneal nerve, G: gastrocnemius muscle, Gr: gracilis muscle, LH: long head of the biceps femoris muscle, P: peroneus longus muscle, S: sciatic nerve, SH: short head of the biceps femoris muscle, Sm: semimembranosus muscle, St: semitendinosus muscle, T: tibial nerve, Tf: tensor fasciae latae muscle

fossa became the belt-shaped aponeurosis that spread out slightly in a fan-shape to insert into the deep surface of the sural fascia halfway down the leg.

The muscle was 33.5cm in full length, 9.5cm in the length of muscular belly, and 0.8cm at its maximum width.

The upper portion of the muscle was situated between the biceps femoris and semitendinosus; the lower portion in back of the gastrocnemius; the popliteal vessels and tibial nerve in the anterior of the muscle. Nerve supply was unknown.

The authors' findings, as compared with the supernumerary muscles in the lower limb hitherto published with special reference to the origin, insertion, and location of the anomalous muscle, resemble the case first reported by KELCH (1813). He discovered a muscle which originated from the tibial aspect of the long head of the biceps femoris and inserted into the tendo calcaneus and termed it tensor fasciae suralis. Varying shapes of muscles have been reported since then under this same term; a muscle arising from the long head of the biceps femoris and inserting into the tendo calcaneus (HALLIBURTON 1881 and TURNER 1884-5), a muscle arising from the same head and inserting into the sural fascia (GRUBER 1897 and SCHAEFFER 1913), a muscle arising from the semitendinosus and inserting into the same fascia (GRUBER 1870, KAWAI 1935, and MOGI 1940), and a muscle arising by two heads from the semitendinosus and long head of the biceps femoris and inserting into the sural fascia (NONAKA *et al.* 1954). According to these reports, a muscle which originates from both of the semitendinosus and the long head of the biceps femoris or from either of the above-mentioned and inserts into the sural fascia or the tendo calcaneus can be termed the tensor fasciae suralis. Consequently, the muscle found by the present authors should be regarded as tensor fasciae suralis, this case extremely resembling that of NONAKA *et al.* in the muscle shape.

The muscle reported here is the fifth of this kind in Japan.

TURNER (1872) found a muscle which arose from the long head of the biceps femoris and linea aspera and inserted into the deep surface of the fascia at the upper angle of the popliteal fossa. He termed it tensor fasciae poplitealis. However, considering that the fascia on the same fossa is part of sural fascia, his muscle, in the authors' opinion, should be regarded as belonging to the group of tensor fasciae suralis.

In addition, NONAKA *et al.* regarded a muscle reported by KLAATSCH (1911) as a member of the group of tensor fasciae suralis. Since his muscle originated from the short head of the biceps femoris and inserted into the sural fascia, it is reasonably considered to have been derived from the same head of the biceps femoris from the standpoint of its origin. Moreover, since the tensor fasciae suralis is innervated by the tibial nerve (SCHAEFFER, KAWAI, MOGI and NONAKA *et al.*) while the short head of the biceps femoris by the common peroneal nerve (OUTI 1951), the muscle reported by KLAATSCH may not be a tensor fasciae suralis but one belonging to tenuissimus which occurs in the limb of mammals except in man, as he himself proposed.

## REFERENCES

- 1) GRUBER, W.: Ueber einen vom Musculus Semitendinosus abgegangenen Musculus tensor fasciae suralis. *Mélanges biol. Acad. imp. d. se. de St. Petersburg*, 8: 437-440, 1870.
- 2) GRUBER, W.: Ueber die ungewöhnlichen Musculi tensores fasciae suralis beim Menschen. *Mélanges biol. Acad. imp. d. se. de St. Petersburg*, 10: 199-200, 1879.
- 3) HALLIBURTON, W. D.: Remarkable abnormality of the musculus biceps flexor cruris. *Jour. Anat. and Physiol.*, 15: 296-299, 1881.
- 4) KAWAI, M.: Über drei Muskelanomalien. *Acta Anat. Nippon.*, 8: 270-275, 1935 (in Japanese).
- 5) KELCH, W. G.: Abweichung des Biceps Femoris. *Beiträge z. pathol. Anatomie*, 8, art. 36: 42, 1813 (cited from Schaeffer).
- 6) KLAATSCH, H.: Ueber eine dem Tenuissimus ähnliche Variation am Biceps femoris des Menschen. *Anat. Anz.*, 38: 305-310, 1911.
- 7) MOGI, E.: Muskelvarietäten der unteren Extremitäten bei den japanischen Zwillingsfehen. *Okajimas Folia Anat. Jpn.*, 19: 93-95, 1940.
- 8) NONAKA, T. and ISHII, S.: A case of M. tensor fasciae suralis. *Jour. of Correctional Med.*, 2: 25-27, 1954 (in Japanese).
- 9) OUTI, H.: Pri maloftaj muskolaj variacioj aperintaj multope en ambau malsupraj membroj. *Acta Anat. Nippon.*, 26: 46-54, 1951 (in Japanese).
- 10) SCHAEFFER, J. P.: On two muscle anomalies of the lower extremity. *Anat. Record*, 7: 1-7, 1918.
- 11) TURNER, W.: Muscular system. *Jour. Anat. & Physiol.*, 6 (2nd series, vol. 5): 441, 1872.
- 12) TURNER, W.: Absence of extensor carpi ulnaris and presense of an accessory sural muscle. *Jour. Anat. & Physiol.*, 19: 333-334, 1884-5.