

Carcinoembryonic Antigen (CEA) in Portal Blood in Colorectal Cancer Patients Correlation of Immunohistochemical Staining

Takatoshi SHIMOYAMA, Yutaka FUKUDA, Ryohji TAKAHIRA,
Akio KAWAGUCHI, Hironobu TOHCHIKA, Haruhiko NAKAO,
Hiroyuki KUSANO, Teruhisa SHIMIZU, Tohru NAKAGOE, Tatsuo HIRANO,
Tsutomu SAKAI, Toshio MIURA, Masao TOMITA

*The First Department of Surgery
Nagasaki University School of Medicine*

Received for publication, June 28, 1988

ABSTRACT : The Carcinoembryonic antigen (CEA) levels in portal blood in 87 colorectal patients were studied in correlation with the immunoreactivity of tumor CEA stained by immunoperoxidase method in order to examine how serum CEA increases. Portal blood CEA increased by operative maneuver. Portal blood CEA was correlated with the Duke's staging, and revealed higher positive rates than CEA in peripheral blood in each stage. The amount of CEA in well differentiated and moderately differentiated adenocarcinoma was higher than that of poorly differentiated adenocarcinoma. However, moderately differentiated adenocarcinoma revealed the highest level of portal blood CEA ($p < 0.05$). Significant increase of portal CEA was observed when CEA was found in cytoplasm and stroma immunohistochemically besides in strongly positive stain, and when cancer was proved pathologically to invade over the intestinal wall. This study suggests that how CEA is transported from the tumor to the portal vein which is the most important decisive factor of the CEA level in peripheral blood.

INTRODUCTION

The carcinoembryonic antigen (CEA) of colorectal cancer is the most valuable tumor marker and its assay is now widely used. However, about half of the patients with colorectal cancer do not indicate elevated CEA levels in peripheral blood. Consequently it is necessary to find out how CEA is transferred from cancer tissue producing CEA into circulating blood, as the level of CEA in peripheral blood does not fully reflect the cancer tissue. Most researches about the mechanism of raised blood CEA levels have been concerned with the assessment of raised CEA in peripheral blood, using the histopatho-

logical findings of the tumor, the staining and the localization of CEA by immunohistochemical method,^{1~5)} and the measurement of CEA in extracts of tumor,^{6~8)} but a few has studied portal CEA.⁸⁾ In the present study, we measured portal CEA levels from the blood of the drainage vein which was drawn during the surgical operations of the patients with colorectal cancer, and studied the relationship between portal CEA and CEA in tumor by immunohistochemical staining.

MATERIALS AND METHODS

Patients

Eighty-seven patients who underwent resec-

tion for primary colorectal cancer at the First Department of Surgery, Nagasaki University Hospital between January 1978 and December 1986 were examined. There were 59 males and 28 females, and the mean age was 60.9 years. Those who were affected with multiple cancer and/or double cancer were excluded.

Blood-collecting from the Portal Vein

A catheter was inserted into the main trunk of the drainage veins from the primary tumor, and collected the blood sample from the marginal vein close to the tumor. To avoid the influence of the surgical maneuver, blood collecting in 87 patients was done immediately after laparotomy. On the other hand, to know the alterations of the portal CEA levels caused by the surgical maneuver, portal blood sample of 20 patients was also collected at the time of resection of the colon and rectum.

CEA Radioimmunoassay

The radioimmunoassay for CEA were performed by the Sandwich method using Dinabot-RIA Kit, The cut-off level was 2.5 ng/ml.

Immunohistochemical Staining of CEA

Immunohistochemical staining was performed using the indirect method of Sternberger.⁹⁾ IgG fractions from rabbit's anti-CEA and swine anti-rabbit IgG and the peroxidase-antiperoxidase (PAP) complex were obtained from Dakopatts, Copenhagen, Denmark. All incubation steps of the staining procedure were performed at room temperature. Sections were incubated with rabbit's antiserum CEA at the primary antibody. Fractions of swine anti-rabbit IgG were used to link the rabbit horseradish peroxidase anti-peroxidase complex to the primary antibody. For the chromogen, 3-3' diaminobenzine tetrahydrochloride was used. A positive immunoperoxidase reaction consists of brown linear staining of the apical surface and intraglandular deposits. The specificity and accuracy of the immunoreaction was checked by negative control using sections incubated with rabbit's non-immune serum instead of the primary antibody.

The procedure of extraction of tissues was as previously reported.¹⁰⁾

Histopathological Study

The section for histological study of the tumor was obtained from the neighboring tissue to the tumor which was gathered on the measurement of CEA levels and the central part of the tumor, and they were fixed in 10% formaldehyde and embedded in paraffin and stained by hematoxylin and eosin. Dukes' staging classification was employed as a measure of the clinical staging of the colon and rectum.

Statistics

All data were stored on a computer. The tissue CEA levels, CEA staining, portal CEA levels and peripheral CEA levels were analyzed and the chi-square (X²) test and Student's test was performed.

RESULTS

Alteration of Portal CEA Levels during the Operation

To know the alterations of the portal CEA levels caused by the surgical maneuvers, the CEA levels of the portal blood collected on laparotomy and those on resection of the

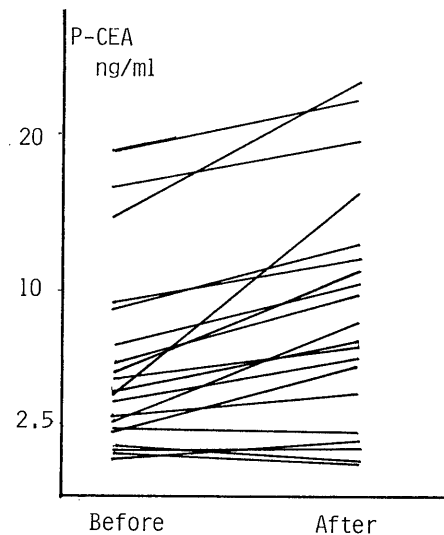


Fig. 1. Alterations of the portal CEA levels by the surgical maneuvers.

Before : portal blood CEA collected immediately after laparotomy.

After : portal blood CEA collected after surgical operation.

tumor in 20 patients were examined. The mean of the CEA levels on laparotomy was 6.20 ± 5.27 g/ml, and that on resection was 9.35 ± 7.79 ng/ml, which significantly differed ($p < 0.01$). (Fig.1)

Dukes' Staging and Portal CEA Levels

Table 1 shows the relationship between Dukes' staging and portal and peripheral CEA levels. The positive rate of serial CEA in peripheral blood was: Dukes' A; 25%, Dukes' B: 45%, Dukes' C: 65.1%, Dukes' D: 93.8%. The positive rate in the portal blood was Dukes' staging ($p < 0.05$). The positive rate in the portal blood was also correlated with Dukes' staging, and was higher than that in peripheral blood on any stages. The mean value of serial CEA in peripheral blood and in the portal blood on Dukes' D stage was significantly higher than those on Dukes' A and Dukes' B ($p < 0.05$), and Dukes' C ($p < 0.01$).

Cancer Invasion in Colorectal Wall and Portal and Peripheral CEA Levels

Seventy-one patients excluding 16 patients with Dukes' D were included for this study (Table 2). The mean values of portal and peripheral CEA showed significant elevation in those with infiltration of cancer cells extending through the proper muscle layer (pm). The positive rate of portal CEA in those with subserosal or serosal invasion was higher than that of peripheral CEA.

Tumor Differentiation and Portal CEA

The mean values of portal CEA of moderately differentiated adenocarcinoma was significantly higher than that of well differentiated adenocarcinoma ($p < 0.05$). However, there was no significant correlation between cell differentiation of adenocarcinoma and peripheral blood CEA. Two out of five patients with poorly differentiated adenocarcinoma or mucinous carcinoma were positive of portal CEA, but the mean values of CEA were lower than that of moderately differentiated adenocarcinoma (Table 3).

Table 1. Dukes' classification, portal CEA and peripheral CEA

Dukes' Stage	No. of Patients	No. > 2.5 ng/ml (%)		Mean values (ng/ml)	
		Portal	Peripheral	Portal	Peripheral
A	8	3 (37.5)	2 (25.0)	2.7 ± 2.2	2.6 ± 1.9
B	20	13 (65.0)	9 (45.0)	6.0 ± 7.5	4.2 ± 4.9
C	43	35 (81.4)	28 (65.1)	9.9 ± 12.1	8.3 ± 12.1
D	16	16 (100)	15 (93.8)	$45.2 \pm 64.7^*$	$23.0 \pm 30.7^*$
Total	87	67 (77.0)	54 (62.1)	13.9 ± 32.3	8.0 ± 10.2

* Significant difference between Dukes' A and B ($p < 0.05$) and C ($p < 0.01$) by the Student's test

Table 2. Cancer invasion in colonic wall and portal and peripheral CEA

Depth of cancer invasion	No. of patients	Portal CEA		Peripheral CEA	
		Mean \pm SD (ng/ml)	Positive rate (%)	Mean \pm SD (ng/ml)	Positive rate (%)
pm	9	3.2 ± 2.4	33.3	3.1 ± 2.3	42.9
ss	41	10.2 ± 16.3	48.8	8.2 ± 19.2	47.1
s	12	33.6 ± 71.1	75.0	8.7 ± 8.9	68.2
si	9	12.2 ± 13.1	77.8	12.3 ± 14.7	57.9

pm : proper muscle layer ss : subserosal layer s : serosal layer

* Significant difference in cancer invasion extending through pm ($p < 0.01$) by the Student's test

Table 3. Tumor differentiation, portal CEA and peripheral CEA

Cell differentiation	No. of Patients	No. > 2.5 ng/ml (%)		Mean values (ng/ml)	
		Portal	Peripheral	Portal	Peripheral
Well	20	9 (45)	6 (30)	3.9±4.3	2.5±2.3
Moderately	41	28 (68.3)	21 (51.2)	9.7±8.1*	3.4±2.5
Poorly	5	2 (40)	1 (20)	3.2±2.6	2.3±2.9
Mucinous	5	2 (40)	2 (40)	5.8±3.1	4.3±3.6

* Significant difference between well and moderately differentiated adenocarcinomas ($p < 0.05$), 71 cases excluding 16 cases with Duke's D

Immunohistochemical Staining and Histo-pathology

All of 87 colorectal carcinoma were stained for CEA. However, each cell type of tumor was different in the localization and the intensity of CEA in cytoplasm, malignant glands, and stroma. CEA was found mainly in the apical border of the malignant glands, and positive staining was also seen in the luminal secretions, in well differentiated adenocarcinoma (Fig. 2a). In moderately differentiated adenocarcinoma, cytoplasm of neoplastic cells as well as apical border were stained for CEA (Fig. 2b), and moreover some portion of stroma beyond basolateral surface were also stained (Fig. 2c). Poorly differentiated adenocarcinoma were weakly stained for CEA. A positive stain for CEA was mostly seen in the portion with gland formation. On the other hand, the portion without gland formation did not stain at all or just weakly stained in cytoplasm. In mucinous carcinoma, CEA was localized in free neoplastic cells, but was stained weakly in

mucin or stroma. Apical surface of normal colonic epithelial cells adjacent to malignant tissue were stained slightly for CEA. Control section was not stained.

Immunohistochemical Grading of CEA Tissue Stain

To know intensity and localization of CEA in tumor reflect tumor CEA levels and plasma CEA levels, 87 tumor classified into three grades. Grade-I; CEA was localized mainly in apical border, but CEA stain in cytoplasm was weak and found in under 50% of the tumor. Grade-II; strong CEA stain was observed not only in apical border but also in cytoplasm. Over 50% of the tumor were stained. Grade-III; stroma surrounding malignant glands were stained as well as the portion of grade II.

Immunohistochemical Stain and Tumor CEA Levels

Table 4 shows the relationship between the immunohistochemical grading and tumor CEA

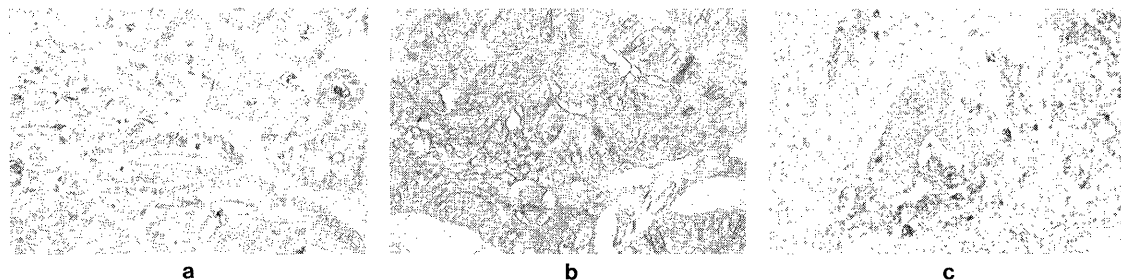


Fig. 2. Immunohistochemical staining of colon cancer

Well differentiated adenocarcinoma; CEA mainly distributes in the apical border of the neoplastic cells, Cytoplasm weakly stains for CEA (Fig. 2a × 150). Moderately differentiated adenocarcinoma; apical border and basolateral surface stain, and cytoplasm stains strongly (Fig. 2b × 250). CEA distributes diffusely in some parts of stroma of the basolateral surface (Fig. 2c × 250).

Table 4. Immunohistochemical grading and tumor differentiation

Grade	I	II	III	Total
well	1(6.7)	11(73.3)	3(20)	15(100)
moderately	2(3.5)	25(43.9)	30(52.6)	57(100)
poorly	3(50)	2(33.3)	1(16.7)	6(100)
mucinous	3(100)			3(100)

() : %

levels. Tumor CEA levels of grade III ($p < 0.05$) were significantly higher than those of grade I and grade II ($p < 0.1$).

Immunohistochemical Grading and Portal and Peripheral CEA Levels

CEA levels in peripheral blood tend to be higher in grade III, but did not indicate significant correlation with any grades. Portal CEA levels correlated with grades, and the levels in grade III were significantly higher ($p < 0.01$) (Table 5).

DISCUSSION

In the present study, we found that portal CEA levels were higher than peripheral CEA levels and elevated after surgical maneuver. This fact suggests that most of CEA flows from tumor tissues into the peripheral blood vessel via the portal vein. Portal CEA levels correlated with Dukes' grading and reflected the progression of the cancer better than peripheral CEA levels. Portal CEA levels were especially high in the case of tumors with invasion over the intestinal walls, and correlated with the differentiation of tumor.

Several factors contributing to elevated peripheral CEA levels have been pointed out: 1) CEA productivity of tumor 2) release of CEA

Table 5. Immunohistochemical grading and cancerous tissue CEA

Grade	No. of patients	Cancerous tissue (ng%)
I	12	3863
II	41	5888
III	34	10471*

* Significant difference ($p < 0.05$) by the Student's t test

from tumor into the blood stream^{7,11}) 3) clearance of circulating CEA¹²) 4) reabsorption of CEA excreted in the intestine.¹³) Among these factors, CEA productivity is the most essential.

There are many immunohistochemical studies which attempted to evaluate elevated plasma CEA levels based on the intensity of stain for CEA or the localization of CEA. However, it is difficult to grade tumor tissue by immunohistochemical staining because of heterogeneous staining patterns, which represent the interrelation of several clones of tumor. Previous researches which attempted to evaluate tumor CEA levels could be divided into those focused on the intensity of stain for CEA³) and those focused on the localization of CEA.^{2,4,5}) Hamada et al. classified into three grades of apical, cytoplasmic and stromal based on the localization of CEA in tumor.⁷) In our study, as in the Wiggers and his colleagues' study,⁵) we could not strictly differentiate between the apical type from the cytoplasmic type. Consequently we categorized grades based on both the localization and the stain, and observed a high correlation between grades and tumor CEA levels, the higher the grade the higher the CEA levels. This suggests that the immunohistochemical stain for CEA may be as a quantitative indicator as well as qualitative.

Table 6. Immunohistochemical grading and portal and peripheral CEA

Grade	No. of Patients	No. > 2.5 ng/ml (%)		Mean CEA values (ng/ml)	
		Portal	Peripheral	Portal	Peripheral
I	7	3 (42.9)	3 (42.9)	4.7 ± 3.9	4.4 ± 3.2
II	34	24 (70.5)	18 (52.9)	5.7 ± 4.5	4.6 ± 5.6
III	30	25 (83.3)	18 (60.0)	8.0 ± 8.9*	6.5 ± 9.5

* Significant difference between grade II and III ($p < 0.05$) by the Student's t test

The study which investigated the relationship between tumor CEA levels evaluated per unit weight and peripheral CEA levels reported no significant correlation between them,⁶⁾ we did not observe any correlation between the amount of CEA per unit weight of tumor tissue and peripheral CEA levels either.¹⁰⁾

Many studies which investigated the localization of CEA in tumor and the staining immunohistochemically in relation to peripheral CEA reported no correlation.^{2,3)} In our study, we observed a significant increase of portal CEA levels in grade III, though we did not observe correlation between grading and peripheral CEA levels.

In terms of tumor differentiation, moderately differentiated adenocarcinoma showed significantly higher portal CEA levels than well differentiated ones. This is assumed to reflect the phenomenon that moderately differentiated adenocarcinoma contains a large amount of CEA and has wide distribution of CEA shown by immunohistochemical staining. On the other hand, well differentiated adenocarcinoma revealed low portal CEA levels, though it contained a large amount of CEA. This can be explained by that most of the CEA in the tumor was excreted into the lumen of the intestine and only a little was released into the portal vein, because well differentiated adenocarcinoma was found to maintain polarity of the cell surface and the structure of normal colonic mucosal cells,^{14,15)} and because luminal excretions were stained for CEA by immunohistochemical staining. Poorly differentiated adenocarcinoma and mucinous carcinoma had weak stain for CEA and low portal CEA levels and those findings were compatible with the studies of Ahnen et al.,¹⁴⁾ and Goslin et al.¹⁶⁾

In conclusion, portal CEA levels correlated well with tumor CEA content, invasion of tumor, and immunohistochemical grading for CEA, but not with peripheral CEA levels. This difference might be caused mainly by the metabolism in the liver, since CEA flows from the portal vein into the systemic circulation through the liver. Shuster et al. carried out an experiment in which they injected labeled CEA gathered specifically in the liver and was degraded and excreted within one hour, with a half life

of a day long.¹²⁾ Generally CEA in neoplastic tissue is excreted into the lumen of the intestine.^{2,11)} As tumor grows, we suppose, basal membrane of the epithelium and the vascular system in stroma are lesioned, which causes inhibition of CEA excretion and the transfer of CEA into the portal vein. The findings of this study suggest that the mechanism of CEA transfer from tumor into the portal vein is the most important factor to evaluate the CEA values in peripheral blood vessels.

REFERENCES

- 1) GOLD, P. and FREEDMAN, S. O. : Specific carcinoembryonic antigens of the human digestive systems. *J. Exp. Med.*, 122 : 457-481, 1965.
- 2) PIHL, E., MCNANGTAN, J., MA, J., *et al.* : Immunohistological patterns of carcinoembryonic antigen in colorectal carcinoma. Correlation with staging and blood levels. *Pathology*, 12 : 7-13, 1980.
- 3) MIDIRI, G., ANANTI, C., BENEDETTI, M., *et al.* : CEA tissue staining in colorectal cancer patients. A way to improve the usefulness of serial serum CEA evaluation. *Cancer*, 55 : 2624-2629, 1985.
- 4) HAMADA, Y., YAMAMURA, M., HIOKI, K., *et al.* : Immunohistochemical study of carcinoembryonic antigen in patients with colorectal cancer. Correlation with plasma carcinoembryonic antigen levels. *Cancer*, 55 : 136-141, 1985.
- 5) WIGGERS, T., RENDS, J. W., VERSTIJNEN, C., *et al.* : Prognostic significance of CEA immunoreactivity patterns in large bowel carcinoma tissue. *Br. J. Cancer*, 54 : 409-414, 1986.
- 6) MIRTIN, F. and MIRTIN, M. S. : Radioimmunoassay of carcinoembryonic antigen in extracts of human colon and stomach. *Int. J. Cancer*, 9 : 641-647, 1972.
- 7) WAGENER, C., MULLER WALLRAF, R., NISSON, S., *et al.* : Localization and concentration of carcinoembryonic antigen (CEA) in gastrointestinal tumors correlation with CEA levels in plasma. *J. Natl. Cancer Inst.*, 62 : 539-541, 1981.
- 8) TABUCHI, Y., DEGUCHI, H., IMANISHI, K., *et al.* : Carcinoembryonic antigen (CEA) levels of peripheral and portal blood and tumor histopathology in colorectal cancers. *J. Jpn. Surg. Soc.*, 87 : 1540-1547, 1986.
- 9) STERNBERGER, L. A., HARDY, P. H., CUCULIS, J.

- J., *et al.*, : The unlabeled antibody enzyme method of immunohistochemistry : Preparation and properties of soluble antigen-antibody complex (horseradish peroxidase antihorseradish peroxidase) and its use in identification of spirochetes. *J. Histochem. Cytochem.*, 18 : 315-333, 1970.
- 10) SHIMOYAMA, T., FUKUDA, Y., ITOH, S., *et al.*, : Clinical evaluation of carcinoembryonic antigen (CEA) in colorectal cancer. *Acta Medica Nagasaki.*, 31 : 294-302, 1986.
 - 11) BIVINS, B. A., MEEKER, W. R. and GRIGGEN, W. O. : Carcinoembryonic antigen (CEA) levels and tumour histology in colon cancer. *J. Surg. Res.*, 18 : 257-261, 1975.
 - 12) SHUSTER, J., SILVERMAN, M. and GOLD, P. : Metabolism of human carcinoembryonic antigen in xenogeneic animals. *Cancer, Res.*, 33 : 65-68, 1973.
 - 13) RSSTUBBS, DMNADKARNI and HAMONSEY : Faecal carcinoembryonic antigen colorectal cancer patients. *Gut*, 27 : 901-905, 1986.
 - 14) AHNEN, D. J., NAKANE, P. K. and BROWN, W. R. : Ultrastructural localization of carcinoembryonic antigen in normal intestine and colon cancer. *Cancer*, 49 : 2077-2090, 1982.
 - 15) HUTTRIC, E., LAUMONIER, R., BURTON, P., *et al.*, : An optimal and ultrastructural study of the localization of carcinoembryonic antigen (CEA) in normal and cancerous human rectocolonic mucosa. *Laboratory Investigation*, 34 : 97-107, 1976.
 - 16) GOSLIN, R., O'BRIEN, M. J., STEELE, G., *et al.*, : Correlation of plasma CEA and CEA tissue staining in poorly differentiated colorectal cancer. *Am. J. Medicine*, 71 : 246-253, 1981.