

Surgery for Perforating Intestinal Behcet's Disease

Kiyohiko KAKU, Nobuharu OISHI and Masao Tomita*

*Oishi Hospital,
First Department of Surgery, Nagasaki University Hospital**

Received for publication, June 25, 1990

ABSTRACT: We reported the surgical experience with perforating intestinal Behcet's disease in a 36-year-old male and discussed mainly the operation method to avoid recurrence and postoperative complications.

INTRODUCTION

Intestinal Behcet's disease is an accessory symptom of Behcet's disease which formed deep ulceration in the ileocecum. It is not infrequent that emergency operation is needed for perforation and massive bleeding which tends to occur accidentally. Furthermore intestinal Behcet's disease is liable to take place a complication of anastomosis insufficiency and fistula formation as well as recurrence.

In this paper, surgical experience with perforation of Behcet's disease is reported with some discussion.

PATIENTS

A 36-year-old male was admitted because of severe abdominal pain. He pointed out relapsing inflammation of the eyes and diagnosed as Behcet's disease. He also complained of neural Behcet's disease which required psychologic care. He experienced preshock state with abdominal pain and fever 2 days prior to consultation with us. Free gas below the diaphragm was detected on x-ray film and peritonitis following perforation was diagnosed immediately before admission as shown in Fig. 1.

On admission, his conjunctiva was anemic associated with leucocytosis in blood examina-

tion. The BUN level was elevated at 40mg/dl. X-Ray film showed a presence of free gas below the diaphragm with neveau shadows in the intestine. Immediately after admission, laparot-

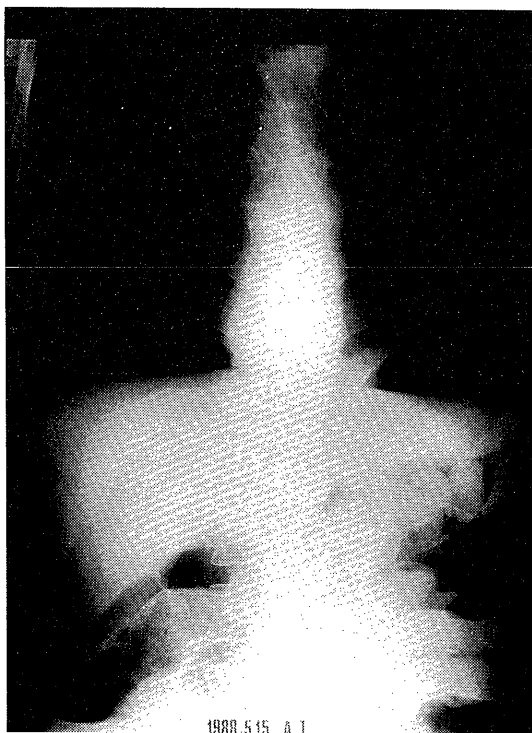


Fig 1. Preoperatively abdominal X-ray film, showing a presence of free gas in the left subphrenic space.

omy was made. The peritoneal cavity was filled with pus. Redness and swelling of the mesenterium were remarkable, reflecting a long time after perforation. It was found that the perforation sites existed in three points of the ileum which corresponded to the sites 14, 25 and 32cm proximal to the end of the ileum (**Fig. 2**). However, it was suggested that ulceration was

present in the further proximal ileum on palpation so that a 80cm long ileum was resected. The cut edges were free of ulceration, showing redness and edema on gross appearance.

Patient's condition in the postoperative course was emotionally apprehensive, and he suffered from hallucination and needed special psychiatric drugs. On the 25 day after operation, he was discharged without any surgical complication.

Surgical specimen showed 3 perforations of the ileum which were in the points 14, 25 and 32cm proximal to the end of the ileum respectively, and the mucosa around the perforation sites were reddish and edematous. The perforation sites situated on the side opposite to the attachment of the mesenterium, 4mm in diameter with a sharp margin of ulcer, a round-punched out figure.

On the other hand, the mucosa of the proximal ileum were less reddish and less edematous.

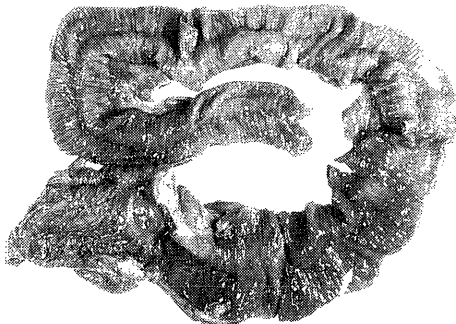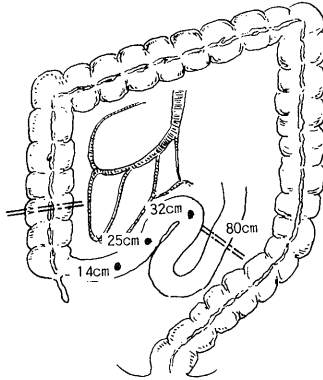


Fig 2. Schematic presentation of the perforating sites and surgical specimen, showing punched-out perforations.



Fig 3. Histologic finding, showing punched out-like perforation.

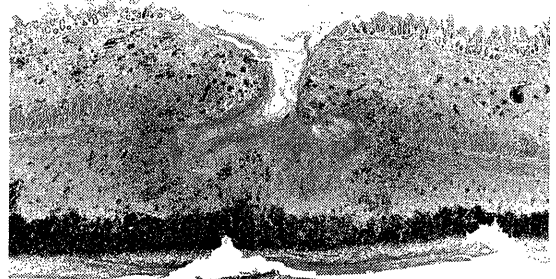


Fig 4. Histologic finding showing no presence of a finding of microangitis.

Needless to say, there was no other ulcer in the specimen.

Histologic finding in the ulcer showed punched-out ulcer without randwall. The inflammatory cell infiltration was manifest in the whole wall as shown in **Fig. 3**. Meanwhile, non-perforated ulcers showed U1-IV type. Deep ulcer and inflammatory cell infiltration were also seen, although there was no finding of micro-angitis as shown in **Fig. 4**.

DISCUSSION

It is well known that ulcers of intestinal Behcet's disease often affect the ileum, tend to be mutiple and deep, and consequently are prone to perforate¹⁾²⁾³⁾. Furthermore, postoperative complications such as anasotmosis insufficiency and fistula formation are common and there are not infrequently fatal. The frequency of ulcers in the digestive tract is reportred as 41% and 45% by Shimizu⁴⁾ and Mizuno⁵⁾. It is frequent that emergency operation is required, Shiratori¹⁾ reported that frequency of emergency operation needed was 62.5% out of 66 Behcet's disease patients.

As Behcet's disease has a high risk of hemorrhage from ulcers and perforation at ulcers. It is recommended that early operation should be mandatory to prevent fatal complications.

The present patient elapsed 14 years from onset and perforation occurred accidentally in the course of his disease.

As a rule, it is said that the stable and constant values of blood sedimentation. GRP WBC α - β globuline activity of complement. Cq in serum indicate the ideal timing of surgery in the course of Behcet's disease⁶⁾. It is characteristic of postoperative recurrence which occurs to 20-30% in frequency and is seen around anastomotic sites or in the proximal ileum.

Surgeon should pay attention to the determination of the resected line with an aid of Ba-enema, preoperative and intraoperative endoscopy and selective angiography.

At emergency operation, careful palpation and intraoperative endoscopy are required for accurate determination of the resection line.

With respect of the extension of resection,

Sarashina⁸⁾ reported that a 70-80cm long ileum should be resected to prevent recurrence and Shiratori¹⁾ emphasized that right hemicolectomy with a 100cm long ileal resection is necessary in the lesion of ileocecal region.

On the other hand, Nemoto⁹⁾ commented that wide resection is not valid to ensure radicality of the operation for avoiding recurrence because extensive vascular lesion extends even in no ulcer bearing intestines.

In our patients, recurrence has not occurred in one year following surgery, although a long term follow-up study is needed.

The timing of operation and determination of the resection line is a key point for the cure of intestinal Behcet's disease. When the symptom of the digestive tract without associated signs is preceded, it is difficult to diagnose in early stage even though complete or incomplete types of Behcet's disease are not necessarily so.

In conclusion, a surgeon should be aware of the presence of Behcet's diseases which accompanies ulceration in the ilececal region and successful surgical treatment should be expected with an aid of careful palpation and intraoperative endoscopic examination.

REFERENCES

- 1) Shiratori T, Inagi N: Review of perforating 66 intestinal Behzet disease. *Surgical Therapy* 38: 129, 1978.
- 2) Baba S: Clinical manifestation of intestinal Behcet's disease. *Stomach and Intestine* 14: 855, 1979.
- 3) Watanabe I: Pathohistologic study on intestinal Behcet's disease. *Stomach and Intestine* 14: 903, 1979.
- 4) Shimizu T: Intestinal damage in Behcet's disease-especially intestinal Behcet' disease. *Stomach and Intestine* 10: 1593, 1975.
- 5) Mizuno K: Evaluation in 11 cases of Behcet's disease-in view of diagnosis in the digestive tract Clin. *Radiology* 21: 1133, 1976.
- 6) Miura S: Therapy and Prognosis in the colon with Behcet's disease. *Surg. Therapy* 56: 306, 1987.
- 7) Terada K: Clinical evaluation in the 75 patients with intestinal Behcet's disease on the basis of reported cases in Japan. *Geka* 45: 1421, 1983.
- 8) Sarashina H: Three cases with intestinal

Behcet's disease in the terminal ileum. *Clin Radiology* 20:255, 1975.

- 9) Nemoto A: Perforating intestinal Behcet's disease, Clinical and immunochemical study. Progress in therapy of abdominal emergency 6: 641, 1986 (in Japanese)