

Case Report

Video-Assisted Thoracoscopic Diverticulectomy of the Midesophagus

Shigetoshi MATSUO,¹ Satoshi YAMAGUCHI,¹ Takashi AZUMA,¹ Sayaka HARUNO,¹ Shirou OBATA,² Takashi KANEMATSU³

¹Department of Surgery, Nagasaki Prefectural Shimabara Hospital, Nagasaki, Japan

²Department of Radiology, Nagasaki Prefectural Shimabara Hospital, Nagasaki, Japan

³Division of Surgery, Nagasaki University Graduate School of Biomedical Sciences, Nagasaki, Japan

Video-assisted thoracoscopic surgery (VATS) for a large, midesophageal diverticulum was successfully performed in a 77-year-old male who had dysphagia for one year. Postoperatively, the patient was well without any complications and was relieved of dysphagia. The VATS diverticulectomy was considered to be minimally invasive and constituted a good indication especially for patients of advanced age showing symptomatic esophageal diverticulum.

ACTA MEDICA NAGASAKIENSIA 50: 79 - 81, 2005

Keywords: Video-assisted thoracoscopic surgery; Diverticulum; Esophagus

Introduction

Esophageal diverticulum is a rare condition, especially in the midesophagus. In spite of the recent advances in thoracoscopic surgery, to our knowledge, only four case reports have been published in English¹⁻⁴ regarding the thoracoscopic esophageal diverticulectomy. We report a case of a large midesophageal diverticulum treated with video-assisted thoracoscopic surgery (VATS) and compare it with open surgery.

Case report

A 77-year-old man, complaining of progressive dysphagia for one year, was admitted to Nagasaki Prefectural Shimabara Hospital on April 22, 2003. His medical records were not remarkable. Esophagography revealed a midesophageal diverticulum of 5 cm in diameter (Figure 1). The barium meal which the patient swallowed first filled in the diverticulum and then flowed into the lower esophagus and stomach. Achalasia was not present. Esophagoscopy showed food remained in the diverticulum (Figure 2). A computed tomography revealed a diverticulum of the esophagus which was located between the heart and the aorta (Figure 3). Thus, his complaint was judged to have resulted from esophageal diverticulum. On April 25, 2003,

under general anesthesia using a double-lumen tube, the patient was turned to his left side and the right lung was completely collapsed.

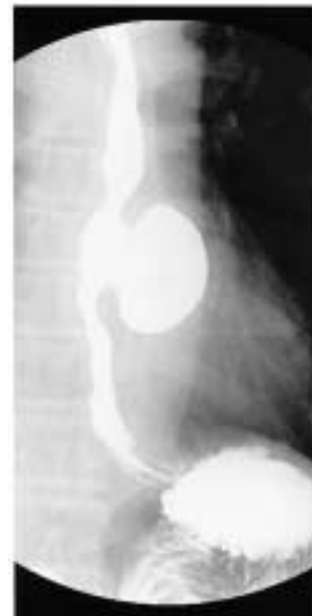

Figure 1. Esophagography revealed a left-sided midesophageal diverticulum of 5 cm in diameter with a broad neck. Achalasia was not present.

Address correspondence: Shigetoshi Matsuo, M.D., Department of Surgery, Nagasaki Prefectural Shimabara Hospital, 7895 Shimokawajiri, Shimabara, Nagasaki 855-0861 JAPAN

TEL: +81-(0)957-63-1145, FAX: +81-(0)957-63-4864, E-mail: shigetoshi-matsuo@pref.nagasaki.lg.jp

Received March 9, 2005; Accepted April 27, 2005

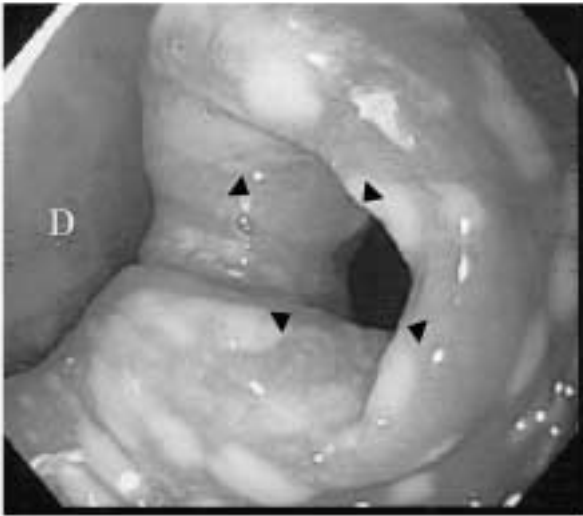


Figure 2. Esophagoscopy showing food remained in the diverticulum. D: diverticulum; arrow heads: esophageal canal.



Figure 4. Video-assisted thoracoscopic diverticulectomy was performed using an EndoGIA device. E: esophagus; D: diverticulum.

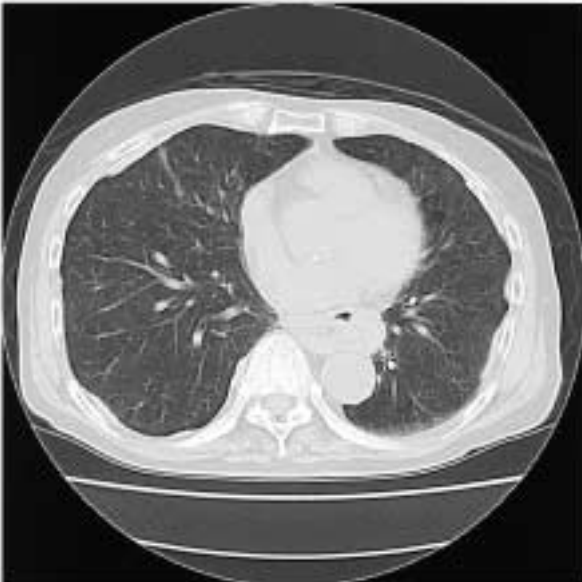

Figure 3. Computed tomography (CT) image showing a diverticulum of the esophagus located between the heart and the aorta.

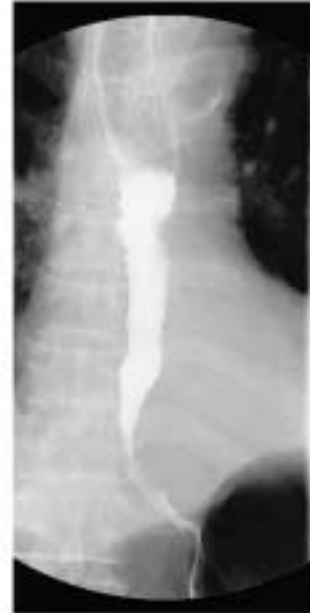

Figure 5. Postoperative esophagography showing a good flow into the stomach without stenosis.

A 10-mm trocar for the insertion of a tracoscope was made in the seventh intercostal space in the anterior axillary line, and a 5-mm trocar was made to allow for the entry of forceps in the eighth intercostal space in the posterior axillary line. A 7-cm mini-thoracotomy was made in the sixth intercostal space between these two trocars. The parietal pleura covering the diverticulum was incised, and the diverticulum was completely exposed and mobilized after exfoliation and pulled by the forceps. Two tapes were passed around the exposed proximal and distal esophagus of the diverticulum. An EndoGIA (United States Surgical Corporation, Norwalk, Connecticut) was inserted through the mini-thoracotomy, placed carefully across the neck of the diverticulum, and fired (Figure 4). Two cartridges

were used during the operation. A chest drain was inserted before closing the chest wall. The operating time was 180 minutes, and estimated blood loss was 200 mL.

The patient recovered well postoperatively without any complications. A nasogastric tube was removed on postoperative day 3 and a chest drain was removed on postoperative day 6. A Gastrografin® examination performed on postoperative day 6 revealed smooth passage without leakage and stenosis (Figure 5). Oral meals were started on postoperative day 7, and the patient was discharged home on postoperative day 19. The patient was asymptomatic two years after surgery.

Discussion

Having a wide indication for laparoscopic surgery, laparoscopic resection through abdominal approach has been performed for esophageal epiphrenic diverticulum.⁵⁻⁸ However, open thoracotomy or thoracoscopic surgery should be recommended for the midesophageal diverticulum. The present case was at an advanced age and was symptomatic, and the diverticulum was located in the midesophagus without motility disorders, so VATS was a procedure of choice for the diverticulectomy.

In esophageal surgery, surgeons first have to avoid stump leakage because it is a most life-threatening complication that can immediately lead to sepsis. As regards esophageal diverticulectomy with open thoracotomy, Benacci et al.⁹ reported that complications occurred in 11 of 33 patients with open thoracotomy (33.3%), including leakage in 6, pneumonia in 2, atrial fibrillation in 2 and sepsis in one, and the operative mortality rate was 9.1%. In contrast, Jordan et al.¹⁰ reported no operative mortality, except for a fistula at the suture line that closed spontaneously, probably originating from a minor leakage.

Only seven patients with esophageal diverticulum have been treated with thoracoscopic resection including our present case. These included six diverticula located in the midesophagus and one in the epiphrenic esophagus. The left-sided esophageal diverticulum was seen in 3 patients, the midline diverticulum in 3 and the right-sided diverticulum in one. Except one patient with the right-sided epiphrenic diverticulum, the right chest approach was performed in six patients. Two-ports procedure was needed when a mini-thoracotomy was involved, while four ports were mandatory without a mini-thoracotomy. Operation

time ranged from 110 to 180 minutes. Neither major complications nor mortality was related to the anastomotic leakage. Although the thoracoscopic surgery was reported to reduce postoperative pain, two patients having undergone a mini-thoracotomy needed intramuscular pethidine injection. Postoperative follow-up revealed a recurrent diverticulum in one patient 17 months after surgery.

In conclusion, VATS is considered to be an effective and safe procedure for the resection of the midesophageal diverticulum.

References

1. Stuart RC, Wymann A, Chan AW, Chung SC, Li AK. Thoracoscopic resection of esophageal diverticulum: a case report. *J R Coll Surg Edinb* 41: 118-119, 1996
2. Akashi A, Ohashi S, Oriyama T et al. Thoracoscopic treatment of esophago-bronchial fistula with esophageal diverticulum. *Surg Laparosc Endosc* 7: 491-494, 1997
3. Saw EC, McDonald TP, Kam NT. Video-assisted thoracoscopic resection of an epiphrenic diverticulum with esophagomyotomy and partial fundoplication. *Surg Laparosc Endosc* 8: 145-148, 1998
4. Beckerhinn P, Kriwanek S, Pramhas M, Armbruster C, Roka R. Video-assisted resection of pulsative midesophagus diverticula. *Surg Endosc* 15: 720-722, 2001
5. Myers BS, Dempsey DT. Laparoscopic resection of esophageal epiphrenic diverticulum. *J Laparoendosc Adv Surg Tech* 8: 201-207, 1998
6. Rosati R, Fumagalli U, Bona S, Bonavina L, Peracchia A. Diverticulotomy, myotomy, and fundoplication through laparoscopy; A new option to treat epiphrenic esophageal diverticula? *Ann Surg* 227: 174-178, 1998
7. Chami Z, Fabre JM, Navarro F, Domergue J. Abdominal laparoscopic approach for thoracic epiphrenic diverticulum. *Surg Endosc* 13: 164-165, 1999
8. Ipek T, Eyuboglu E. Laparoscopic resection of an esophageal epiphrenic diverticulum. *Acta Chir Belg* 102: 270-273, 2002
9. Benacci JC, Deschamps C, Trastek VF, Allen MS, Daly RC, Pairolero PC. Epiphrenic diverticulum: Results of surgical treatment. *Ann Thorac Surg* 55: 1109-1104, 1993
10. Jordan PH Jr, Kinner BM. New look at epiphrenic diverticula. *World J Surg* 23: 147-152, 1999