

## Case Report

### A case of osteomyelitis pubis in a high school soccer player

Takashi MIYAMOTO, Tatsuya FUKUSHIMA, Kenji TAGUCHI, Makoto OSAKI

Department of Orthopaedic Surgery, Nagasaki University Graduate School of Biomedical Sciences, Nagasaki, Japan

Osteomyelitis pubis in athletes is very rare. This pathology is often confused with osteitis pubis, and delays in treatment may lead to residual sequelae. We encountered a case of osteomyelitis pubis in a 16-year-old high school soccer player. Despite early diagnosis, starting treatment, and subsidence of infection, the patient was unable to return to competitive sports. We report this case and discuss the relevant literature.

ACTA MEDICA NAGASAKIENSIA 61: 33–35, 2017

**Key words:** Osteomyelitis pubis, athlete, Soccer player

#### [Case report]

16-year-old boy had been healthy since birth. He began to play soccer at 8 years old and never experienced any major injury. About 6 months prior to visit our hospital, he experienced pain in the left hip during practice of soccer, but symptoms improved after rest and he did not seek treatment. However, after a soccer match, he experienced a recurrence of left hip pain, unable to move his hip joint, and he had a fever of 38.2°C. He visited a local physician, coxarthrosis was suspected, and he was transferred to emergency department of our hospital.

Evaluation revealed tenderness from the left pubis across the hip joint, with pain on abduction of the hip. Plain pelvis radiography showed irregularity of the pubic symphysis (Fig. 1a), and magnetic resonance imaging (MRI) T2-weighted imaging (T2WI) showed abnormal signal intensities, suggesting inflammation from the pubic symphysis along the left inferior pubic margin (Fig. 1b). Blood testing indicated an elevated inflammatory response with a white blood cell (WBC) count of 20,600/ $\mu$ l and C-reactive protein (CRP) level of 10.1 mg/dl. The patient was initially di-

agnosed as osteitis pubis, admitted to the hospital for rest, and prescribed analgesics. Although pain improved, blood tests the next day still showed a WBC count of 15,100/ $\mu$ l and CRP of 24.2 mg/dl. In addition, he still had a temperature of 38.5°C, indicating no improvement of inflammation, so blood cultures were drawn. Gram staining revealed Gram-positive cocci, and osteomyelitis of the pubic symphysis (osteomyelitis pubis) was diagnosed. Cefazolin (CEZ) was administered at 2 g three times daily.

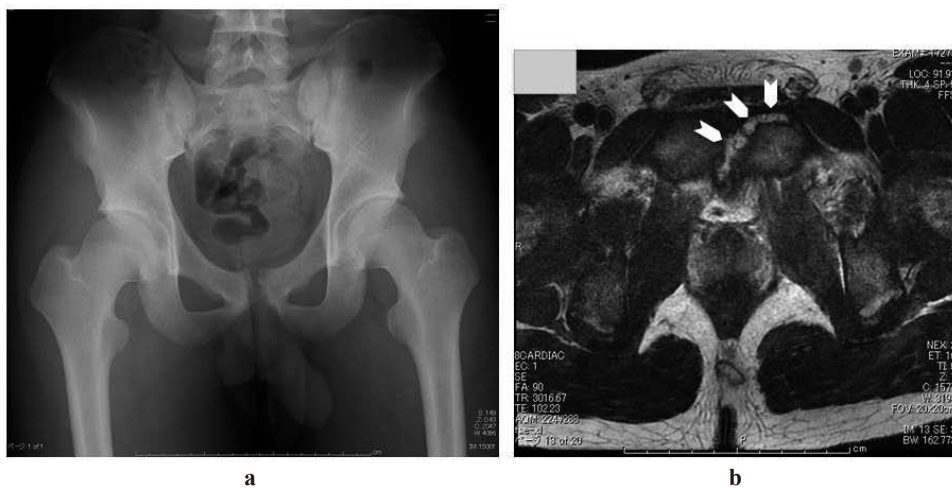The final blood culture results showed methicillin-sensitive *Staphylococcus aureus* (MSSA), so a decision was made to continue antibiotic therapy for 4 weeks. After treatment started, fever completely resolved within 1 week. In addition, pubic and hip pain rapidly resolved with rest and analgesics. Blood test values peaked on hospital day 2, and subsequently, both WBC count and CRP gradually decreased. On hospital day 16, the patient could walk without pain and was discharged (Fig. 2).

He completed treatment with CEZ 2 g three times daily for 4 weeks with his local physician. On day 28 after onset, WBC count and CRP had normalized, so the patient returned to daily activities. Blood tests confirmed that there was no

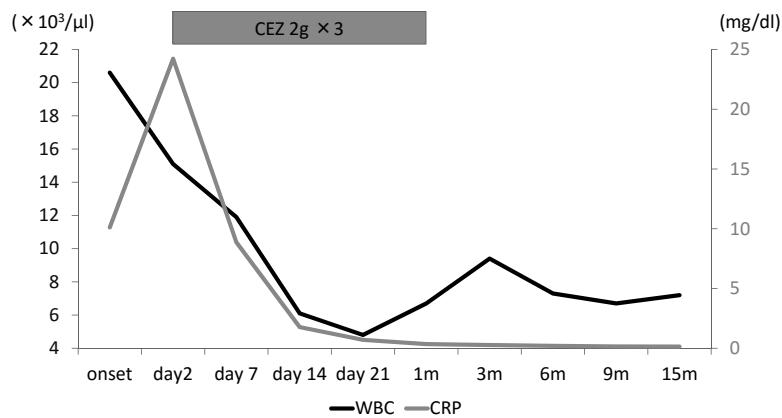
**Address correspondence:** Takashi Miyamoto, Department of Orthopaedic Surgery, Nagasaki University Graduate School of Biomedical Sciences 1-7-1 Sakamoto, Nagasaki 852-8501, Japan

Tel: +81-95-819-7321, Fax: +81-95-849-7325, E-mail: taka4@nagasaki-u.ac.jp

Received August 30, 2016; Accepted September 23, 2016

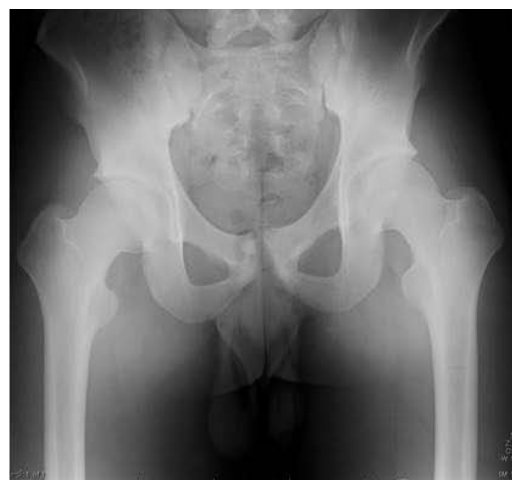

**Figure 1** a Plain pelvis radiography. Showing irregularity of the pubic symphysis.  
b MR image of the pubic symphysis on coronal section. T2WI showed abnormal signal intensities around the pubic symphysis.



**Figure 2**

exacerbation of inflammatory response, and he was permitted to start jogging 3 months after onset. At 6 months after onset, he was also permitted to return to competitive soccer, but he experienced groin pain every time he played and found it difficult to perform at his former competitive level. MRI was performed at 14 months after onset, and T2WI showed signal hyperintensity in the pubis only (Fig.3); however, blood test results remained normal, with a WBC count of  $7200/\mu\text{l}$  and CRP level of  $0.14\text{ mg/dl}$ . Clinically, the osteomyelitis had resolved, but the patient was in his last year of high school at the time, and since he was unable to play soccer at the level he desired, he decided not to return to competition. The patient is able to perform daily activities and light exercise without any complaints of pain.



**Figure 3** Plain pelvis radiography after 1 year and four months. Still showing irregularity of the pubic symphysis.

## [Discussion]

Osteomyelitis pubis is a very rare disease, and differential diagnosis from osteitis pubis is very important. Osteitis pubis is associated with local inflammation and often occurs after vaginal delivery or pelvic surgery<sup>1)</sup>. In recent years, osteitis pubis has also often been reported in competitive sports involving athletes kicking or performing sudden changes in speed, and the rate of similar symptoms of groin pain is 5–13% among soccer players<sup>2)</sup>.

The first-choice approach to osteitis pubis is conservative treatment<sup>3)</sup>, and symptoms often improve with rest and oral analgesics. However, when resistance to conservative treatment is encountered, osteomyelitis pubis must also be considered. If treatment is delayed, pelvic ring instability, pubic symphysis diastasis, or bladder perforation may occur<sup>4)</sup>. In patients with suspected osteitis pubis who also have fever, nausea, or vomiting, osteomyelitis pubis must always be actively considered<sup>1)</sup>.

Ross and Hu<sup>5)</sup> reviewed 100 cases of osteomyelitis pubis and reported fever in 74%. Choi<sup>3)</sup> reviewed 10 cases in athletes and reported fever in 100% of these patients. Our patient, a soccer player who had been healthy since birth, was transferred to our hospital with a chief complaint of fever and tenderness involving the pubis and hip. Osteitis pubis was initially suspected, but symptoms did not improve with rest and analgesics; therefore, osteomyelitis pubis was suspected. The diagnosis was confirmed based on imaging findings and positive blood cultures for *S. aureus*, and antibiotic therapy was started. Choi<sup>3)</sup> reported *S. aureus* from blood cultures in 4 patients, and from aspirations in 3 patients with osteomyelitis pubis. Ross and Hu<sup>5)</sup> also reported *S. aureus* as the major causative organism among athletes.

Osteomyelitis pubis may also coexist with osteitis pubis<sup>4)</sup>. Our patient probably initially had osteitis pubis associated with playing soccer, and symptoms improved when he refrained from sports activities. When he was evaluated at our hospital, infection established for some reason unknown, resulting in bacteremia.

In the report by Choi<sup>3)</sup>, 6 patients underwent 6 weeks of intravenous (IV) antibiotic therapy, 2 patients had 2 weeks

of IV antibiotics, followed by 4 weeks of oral antibiotics, and treatment duration was unknown in 2 patients. However, none of those patients had undergone surgical treatment. Seven patients returned to sports activities after an average of 3.2 months. Pham<sup>1)</sup> reported good outcomes with proper diagnosis and treatment. Our patient received 4 weeks of IV treatment and was able to jog after 3 months; however, he was ultimately unable to return to competitive soccer. Although osteomyelitis did not recur after initial treatment, the patient experienced inguinal pain with strenuous physical activity, and had to discontinue soccer practice. The patient began to feel that his coach no longer had faith in his performance, and he found it difficult to maintain his motivation. This also affected his ability to return to competitive sports.

## [Conclusion]

The differential diagnosis of inguinal pain in athletes without specific injury includes osteitis pubis, but when the patient also presents with high fever, osteomyelitis pubis must be suspected, and blood culture is recommended. With long-term antibiotic therapy, the prognosis of osteomyelitis pubis is good, but some patients might not be able to return to competitive sports. To maintain the motivation of athletes, it is also important to explain the need for early and long-term treatment to coaches and parents.

## References

1. Pham DV, Scott KG. Presentation of osteitis and osteomyelitis pubis as acute abdominal pain. *Permanente J* 11:65-68, 2007
2. Hiti CJ, Stevens KJ, Jamati MK, et al. Athletic Osteitis Pubis. *Sport Med* 41: 361-376, 2011
3. Choi H, McCartney M, Best TM. Treatment of osteitis pubis and osteomyelitis of the pubic symphysis in athletes: a systematic review. *Br J Sports Med* 45:57-64, 2011
4. Pauli S, Willemsen P, Declerck K, et al. Osteomyelitis pubis versus osteitis pubis: a case presentation and review of the literature. *Br J Sports Med* 36:71-73, 2002
5. Ross JJ, Hu LT. Septic arthritis of the pubic symphysis: review of 100 cases. *Medicine* 82:340-345, 2003

