

A Case of Acute Kidney Injury with Marked Hyperuricemia During Mizoribine Administration

Tomoya Nishino¹, Takeaki Shinzato², Yuuki Ohta², Hiroshi Yamashita², Yoko Obata¹, Ken Shinzato³ and Shigeru Kohno¹

Abstract

A 52-year-old woman was diagnosed with Blau syndrome and rheumatoid arthritis and was treated with prednisolone and methotrexate. Joint pain and skin ulcers were poorly controlled; therefore, mizoribine (MZ; 150 mg/day) was administered once daily from March 2011. In early July 2011, the patient was hospitalized because of acute kidney injury (AKI) and acute pancreatitis. We reasoned that AKI resulted from hyperuricemia during MZ administration because serum concentrations of uric acid (31.6 mg/dL) and MZ (trough level, 5.14 µg/mL) were markedly elevated on admission. MZ should be administered with caution because of the risk of marked hyperuricemia leading to AKI.

Key words: mizoribine, acute kidney injury, acute pancreatitis, hyperuricemia, uric acid nephropathy

(Intern Med 51: 1239-1243, 2012)

(DOI: 10.2169/internalmedicine.51.7230)

Introduction

Mizoribine (MZ) is an antimetabolite, first developed in Japan. MZ is used as an immunosuppressant for collagen disease, nephrotic syndrome (NS), and organ transplantation. The immunosuppressive action of MZ results primarily from inhibition of purine metabolism, a key step in nucleic acid synthesis. Nucleic acid synthesis proceeds via 2 pathways: a *de novo* pathway and a salvage pathway. Lymphocytes mainly depend on the *de novo* pathway. MZ inhibits inosine monophosphate (IMP) dehydrogenase, which is the rate-limiting enzyme in the *de novo* pathway, thus inhibiting nucleic acid synthesis in lymphocytes (1). Other cells are less affected by MZ, because they use the salvage pathway for nucleic acid synthesis. Therefore, MZ is thought to have fewer side effects than other immunosuppressive drugs.

Hyperuricemia is a side effect of MZ treatment, and occasional cases of marked hyperuricemia leading to acute kidney injury (AKI) have been reported (2-4). Here, we report a case of hyperuricemia leading to AKI during MZ administration in a patient with Blau syndrome. Blau syndrome is juvenile sarcoidosis with an autosomal dominant pattern of

inheritance and is characterized by skin rash, uveitis, and rheumatoid arthritis.

Case Report

A 52-year-old woman with Blau syndrome (juvenile sarcoidosis with an autosomal dominant pattern of inheritance and characterized by skin rash, uveitis, and rheumatoid arthritis) was treated with prednisolone (PSL) at 10 mg/day and methotrexate (MTX) at 6 mg/week from 2006 to 2011. The patient was frequently hospitalized secondary to painful, recalcitrant skin ulcers on both legs. These ulcers were likely the result of poor control of Blau syndrome. Therefore, MZ therapy was initiated in March 2011. MZ was administered at a dose of 150 mg/day once daily to control the skin ulcers and to hopefully reduce the dose of PSL. However, the patient showed poor control of the underlying Blau syndrome even after the addition of mizoribine therapy. She had arthralgia and skin ulceration with frequent remissions and exacerbations, and the inflammatory response persisted. In early July 2011, laboratory data were as follows: blood urea nitrogen (BUN), 18.6 mg/dL; creatine (Cr), 0.65 mg/dL; estimated glomerular filtration rate (eGFR), 73.9 mL/

¹Second Department of Internal Medicine, Nagasaki University of Medicine, Japan, ²Department of Nephrology, Sasebo General Hospital, Japan and ³Shinzato Clinic Urakami, Japan

Received for publication January 4, 2012; Accepted for publication February 7, 2012

Correspondence to Dr. Takeaki Shinzato, takeakishinzato@yahoo.co.jp

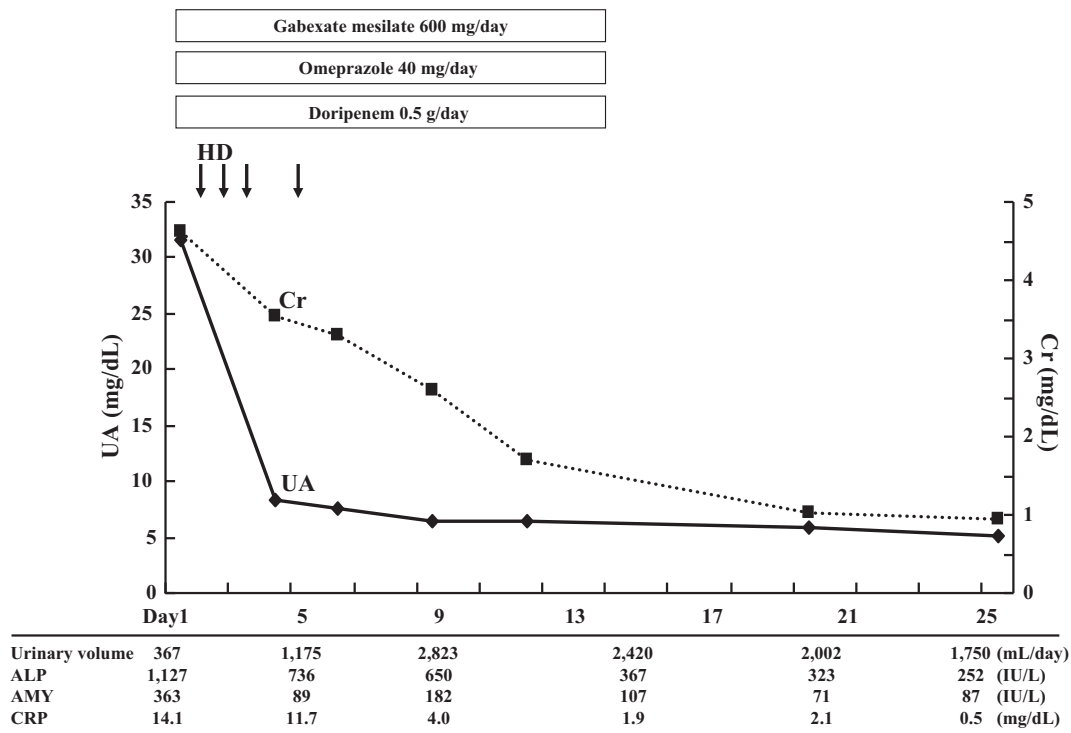


Figure 2. Clinical course of the patient.

to AKI during administration of MZ. Hyperuricemia is a side effect of MZ and results from inhibition of IMP dehydrogenase. The incidence of hyperuricemia and AKI due to MZ has been reported to be 1.0% and 0.04%, respectively (5). MZ inhibits the production of guanosine monophosphate (GMP) from IMP and subsequently increases UA production via hypoxanthine and xanthine (6). Indeed, marked hyperuricemia has been reported in other cases of AKI after MZ administration (2-4).

UA may be involved in the development and progression of kidney diseases and may contribute to AKI. AKI is associated with increased serum UA levels as a result of both increased generation and decreased excretion of UA. In cases of MZ-induced hyperuricemia, the increased serum UA level is primarily a result of increased UA production. Increased UA levels in the blood are widely recognized to cause AKI by obstruction of renal tubules due to the formation of UA crystals within the renal tubules; this is known as acute UA nephropathy (7). Although acute UA nephropathy is typically observed as a complication of tumor lysis syndrome during antineoplastic treatment of leukemia and malignant tumors (8), it has been occasionally reported in cases of rhabdomyolysis (9) and in other conditions. Moreover, recent studies have reported that AKI due to hyperuricemia is not simply mediated by tubular cell injury but is frequently accompanied by renal vasoconstriction, microvascular injury, and a local inflammatory response (10).

MZ is excreted mainly through the kidney, and 81.1% of MZ is excreted in urine as unmetabolized drug. The excretion rate of MZ depends on renal function and is directly correlated with creatinine clearance (Ccr) (11). The half-life

of MZ is 2.5 h in patients with normal renal function ($Ccr > 80$ mL/min), 4.5 hours in patients with Ccr of 40 mL/min, 9 hours in patients with Ccr of 20 mL/min, and longer in patients with deterioration of renal function (11). Therefore, MZ dosing should be reduced in cases of decreased renal function. However, in the present case, there was no deterioration of renal function at the start of MZ administration; the patient had a Cr level of 0.55 mg/dL and an $eGFR$ of 88.7 mL/min. Therefore, MZ was administered orally at 150 mg once daily after breakfast beginning in March 2011. Two months after beginning treatment with MZ, the patient's serum MZ concentration was below the limit of detection; this may have been attributable to poor patient compliance.

In the present case, the MZ concentration in the blood was 3.94 μ g/mL at C2 level in early July 2011. Unfortunately, serum UA levels were not measured until AKI was suspected. The patient showed poor control of the underlying Blau syndrome even after the addition of mizoribine therapy. She had arthralgia and skin ulceration with frequent remissions and exacerbations, and the inflammatory response persisted. After a routine consultation in early July 2011, she developed fever of around 38°C and painful erythema tuberculatum, which seemed to have been caused by the exacerbation of Blau syndrome. She presented with general fatigue and appetite loss, and therefore hospitalized in mid-July. Laboratory tests performed on admission revealed increased inflammatory reaction and findings that include increased white blood cell count and C-reactive protein level. Since she had already developed oliguric AKI at the time of hospitalization, we did not measure urinary uric

acid levels, unfortunately. Based on the patient's course, we presumed that the decreased renal blood flow due to inflammatory cytokine-induced increased vascular permeability, and dehydration due to pyrexia or decreased dietary intake might have led to mizoribine-induced hyperuricemia. Nevertheless, the reason for the patient not showing increased blood urea nitrogen levels was considered to be the decreased dietary intake associated with loss of appetite. Furthermore, the increased serum MZ concentration could have resulted in increased serum UA levels, rapidly causing UA nephropathy. This would have led to the deterioration of renal function. These events may have initiated a vicious cycle, thereby increasing MZ concentration in the serum. Therefore, monitoring of serum UA and MZ is necessary during MZ treatment.

In recent years, the importance of increasing the maximum drug concentration (C_{max}) of MZ to adequately inhibit lymphocytes has been discussed. Although there are few reports on the effective serum peak concentrations of MZ, approximately 4-5 $\mu\text{g/mL}$ of MZ is considered appropriate, as this results in a target C_{max} of 3 $\mu\text{g/mL}$ or higher (12, 13). Previous studies have reported that the time until maximum drug concentration (T_{max}) of MZ averaged 4 hours. Therefore, it is necessary to monitor the C4 level of serum MZ. In the present case, the C2 level of serum MZ concentration had already reached 3.94 $\mu\text{g/mL}$ in early July 2011, and the C4 level was estimated to be markedly higher than the target C_{max} level. In fact, trough levels of MZ were very high (5.14 $\mu\text{g/mL}$) upon admission in the present case. In patients with trough levels of higher than 4 $\mu\text{g/mL}$, there is a significantly high risk of adverse effects such as thrombocytopenia, hepatic dysfunction, and mouth ulcers (14). The present patient also had comorbid acute pancreatitis of unknown origin. To date, only 2 cases of MZ-associated acute pancreatitis have been reported (15, 16). Although the precise mechanism of MZ-associated acute pancreatitis is unclear, drug-associated acute pancreatitis is thought to be due to a hypersensitivity reaction or generation of toxic metabolites. Therefore, it is important to monitor serum UA levels, renal function, pancreatic enzymes, and serum MZ concentrations (trough level and C4 level) in all patients treated with MZ.

Prevention and treatment of acute hyperuricemia and AKI are aimed at maintaining adequate hydration, reducing serum UA levels, and alkalization of the urine, which promotes urate solubilization. Therapy for reducing UA levels includes administration of recombinant uricase, a xanthine oxidase inhibitor, and dialysis. Allopurinol is a xanthine oxidase inhibitor that blocks UA formation. Allopurinol should be used with caution because it interacts with azathioprine, resulting in bone marrow suppression. However, the use of urate-secreting drugs, such as probenecid is contraindicated for several reasons. Urate-secreting drugs reduce the resorption of UA in the proximal tubule by inhibiting urate transporter 1 (URAT-1); they promote the formation of UA crystals in the renal tubule lumen, and increase the concentration

of MZ in the serum with the decline of renal function (17). Hemodialysis effectively eliminates MZ. In addition, hemodialysis can prevent the blockage of renal tubules by UA crystals. The protein-binding ratio of MZ is 1.2-5.5%, and 43% of MZ is eliminated after hemodialysis for 4 hours (18). Among 12 cases of hyperuricemia leading to AKI during MZ administration reported in Japan, 10 cases were treated with hemodialysis. In these cases, 9 of the 10 patients recovered from AKI without renal dysfunction. Similarly, in the present case, hemodialysis was performed 4 times, and there was rapid improvement in UA levels and renal function. Therefore, hemodialysis should be performed as early as possible in cases of hyperuricemia resulting in AKI during MZ administration.

In conclusion, we report a case of hyperuricemia leading to AKI during administration of MZ. During MZ administration, serum UA levels, renal function, and serum MZ concentrations (trough level and C4 level) should be closely monitored. In cases of renal dysfunction, it may be necessary to consider discontinuation of MZ and initiation of hemodialysis.

The authors state that they have no Conflict of Interest (COI).

References

1. Koyama H, Tsuji M. Genetic and biochemical studies on the activation and cytotoxic mechanism of bredinin, a potent inhibitor of purine biosynthesis in mammalian cells. *Biochem Pharmacol* **32**: 3547-3553, 1983.
2. Guo HB. Acute allograft renal failure with marked hyperuricemia developing during mizoribine administration: a case report with review of the literature. *Transplant Proc* **42**: 2804-2807, 2010.
3. Kushihata S, Hirabayashi A, Sekiguchi Y, Nagai K, Arata T. A case of acute renal failure with marked hyperuricemia developing during mizoribine administration. *Nihon Jinzo Gakkai Shi* **44**: 543-546, 2002 (in Japanese).
4. Tanaka H, Abe T, Nishimura S, et al. A case of rheumatoid arthritis/Sjogren's syndrome with acute renal failure due to hyperuricemia associated with mizoribine therapy. *Nihon Rinsho Meneki Gakkai Kaishi* **27**: 171-176, 2004 (in Japanese).
5. Ishikawa I, Maekawa S, Saito T, Horiguchi T, Shinoda A, Ishii H. Mizoribine-induced hyperuricemia. *Nihon Jinzo Gakkai Shi* **28**: 1353-1357, 1986 (in Japanese).
6. Kusumi T, Tsuda M, Katsunuma T, Yamamura M. Dual inhibitory effect of bredinin. *Cell Biochem Funct* **7**: 201-204, 1989.
7. Kjellstrand CM, Cambell DC 2nd, von Hartitzsch B, Buselmeier TJ. Hyperuricemic acute renal failure. *Arch Intern Med* **133**: 349-359, 1974.
8. Rieselbach RE, Bentzel CJ, Cotlove E, Frei E 3rd, Freireich EJ. Uric acid excretion and renal function in the acute hyperuricemia of leukemia. Pathogenesis and therapy of uric acid nephropathy. *Am J Med* **37**: 872-883, 1964.
9. Moreau D. Pharmacological treatment of acute renal failure in intensive care unit patients. *Contrib Nephrol* **147**: 161-173, 2005.
10. Bonventre JV. Pathophysiology of ischemic acute renal failure. Inflammation, lung-kidney cross-talk, and biomarkers. *Contrib Nephrol* **144**: 19-30, 2004.
11. Takada K, Asada S, Ichikawa Y, et al. Pharmacokinetics of bredinin in renal transplant patients. *Eur J Clin Pharmacol* **24**: 457-461, 1983.

12. Doi T, Masaki T, Shiraki N, Kawai T, Yorioka N. Oral mizoribine pulse therapy for steroid-dependent focal segmental glomerulosclerosis. *Clin Nephrol* **69**: 433-435, 2008.
13. Tanaka H, Suzuki K, Nakahata T, Tsugawa K, Ito E, Waga S. Mizoribine oral pulse therapy for patients with disease flare of lupus nephritis. *Clin Nephrol* **60**: 390-394, 2003.
14. Sonda K, Takahashi K, Tanabe K, et al. Clinical pharmacokinetic study of mizoribine in renal transplantation patients. *Transplant Proc* **28**: 3643-3648, 1996.
15. Mori S, Ebihara K. A sudden onset of diabetic ketoacidosis and acute pancreatitis after introduction of mizoribine therapy in a patient with rheumatoid arthritis. *Mod Rheumatol* **18**: 634-638, 2008.
16. Yutsudo Y, Hasegawa Y, Takada T, et al. A case of rheumatoid arthritis (RA) with drug-induced acute pancreatitis due to mizoribine. *Ryumachi* **37**: 564-567, 1997 (in Japanese).
17. Utsunomiya Y, Hara Y, Ito H, et al. Effects of probenecid on the pharmacokinetics of mizoribine and co-administration of the two drugs in patients with nephrotic syndrome. *Int J Clin Pharmacol Ther* **48**: 751-755, 2010.
18. Takada K, Yoshikawa H, Muranishi S, et al. Elimination characteristics of bredinin from patients serum in hemodialysis. *Int J Clin Pharmacol Ther Toxicol* **23**: 197-199, 1985.