

**Case report**

**Culprit segments identified by optical coherence tomography in patients with acute myocardial infarction: two case reports**

Daisuke Sato, Seiji Koga, Tomohiko Yasunaga, Tomoo Nakata, Masayoshi Takeno, Yuji Koide, Satoshi Ikeda, Naoto Ashizawa, and Koji Maemura

Department of Cardiovascular Medicine, Nagasaki University Hospital, Nagasaki, Japan

Short title: Culprit segments identified by OCT in AMI patients

Corresponding author: Seiji Koga

Department of Cardiovascular Medicine, Nagasaki University Hospital

1-7-1 Sakamoto, Nagasaki 852-8501, Japan

Tel: 095-819-7288; Fax: 095-819-7290

E-mail: kogase@nagasaki-u.ac.jp

## **Abstract**

The high resolution of optical coherence tomography (OCT) provides detailed information of coronary plaque morphologies, which enable to evaluate the mechanism of acute myocardial infarction. We describe two patients with acute myocardial infarction in whom culprit segments were identified by optical coherence tomography (OCT), but not by either coronary angiography or intravascular ultrasound.

Key words: acute myocardial infarction, optical coherence tomography, plaque rupture, thrombus, ulcer

## **Introduction**

Optical coherence tomography (OCT) is a new intravascular imaging modality with a resolution (10 – 20  $\mu\text{m}$ ) that is superior to that of intravascular ultrasound (IVUS). Herein, we described two patients with acute myocardial infarction in whom OCT provided useful intracoronary information for detection of culprit lesions and understanding the mechanism of onset.

## **Case 1**

A 73-year-old woman with diabetes mellitus and hypertension was admitted to our hospital with 6 hours of severe chest pain. Electrocardiography demonstrated ST segment elevation in leads I, aVL, V2 – V5, and reciprocal ST segment depression in leads II, III, aVF. Echocardiography revealed severe hypokinesis in the antero-septal and apex wall with an ejection fraction (EF) of 42%. Emergency coronary angiography (CAG) revealed occlusion in the proximal portion of left anterior descending artery (LAD) (Figure 1, A1 and B1). Thrombus aspiration was performed, and red colored thrombi was retrieved (there was no picture) and thrombolysis in myocardial infarction (TIMI) flow grade 2 was obtained. Since the recanalized vessel was small and not

reaching to the apex, we regarded it as the first major septal branch (MSB), not the main vessel of LAD (Figure 1, A2 and B2). It was very difficult to cross the guide wire into the occluded main vessel of LAD, because the entry site to it was not identified on CAG. Alternatively, we performed IVUS (Atlantis SR Pro 2, Boston Scientific, Natick, Massachusetts) and OCT (ImageWire, LightLab Imaging, Westford, Massachusetts) to find out the entry site. Images were obtained by the pullback from the MSB. IVUS presented the clear images of the LAD-MSB bifurcation, but no evidence of either plaque rupture or thrombi (Figure 2, B1 and B2). In contrast, OCT revealed ruptured plaque at the LAD-MSB bifurcation, and the flap-like mass protruding into the lumen of LAD at the LAD-MSB bifurcation (Figure 2, C1 and C2). We regarded this flap-like mass as thrombus. Based on these images, we considered that the culprit lesion was located in LAD side of the LAD-MSB bifurcation. However, we finally failed to cross the guide wire to the occluded LAD. Patient was medically treated with heparin and aspirin. Two weeks later, CAG revealed the recanalized large main vessel of LAD reaching the apex (Figure 1, A3 and B3). Furthermore, severe stenosis was indentified at a little distal to the LAD-MSB bifurcation. Based on these findings, we considered that this stenosis had been possibly the culprit lesion of the present case.

## Case 2

A 53-year-old man with coronary risk factors including hyperlipidemia and current smoking was admitted to our hospital 48 hours of chest pain. Electrocardiography demonstrated ST segment elevation in leads I, aVL, V2 – V5, and a negative T wave in leads I, aVL, V4 – V6. Echocardiography indicated severe hypokinesis in the antero-lateral wall with an EF of 50%. CAG revealed TIMI flow grade 3 in the LAD, but the first diagonal branch (DB) was occluded (Figure 3, A). There was mild stenosis with ulcer-like formation in LAD at the origin of DB (Figure 3, B). Thrombus aspiration was performed and the removed thrombi were mainly red in color (Figure 3, C). IVUS demonstrated the low echo plaque and ulcer in a site opposite the DB, but no thrombi (Figure 4, B1-4). On the other hand, OCT revealed lipid rich plaque and thrombus formation in LAD at the origin of DB (Figure 4, C1-4), and ulcer with microvessels formation (diameter < 100  $\mu$ m) at just proximal to LAD-DB bifurcation (Figure 4, C2). Based on these findings, we considered that the thrombosis in LAD was spontaneously resolved, but DB was persistently occluded. We attempted to cross the guide wire to the occluded DB, but we finally failed. Since the main vessel of LAD was TIMI grade 3, the patient was medically treated with heparin and aspirin.

## **Discussion**

Optical coherence tomography is a novel invasive imaging method that can assess coronary plaque morphology at a resolution of 10 - 20  $\mu\text{m}$ , which is about 10-fold higher than that of IVUS. OCT has emerged as an exceedingly promising tool for assessing patients with acute coronary syndrome and for detecting key features of plaques including thin-cap fibroatheroma, plaque rupture and thrombus in such patients<sup>1)</sup>.

In case 1, OCT revealed ruptured plaque at the LAD-MSB bifurcation, and flap-like mass in the LAD side of the LAD-MSB bifurcation. We regarded this flap-like mass as thrombus. Thrombi on OCT are defined as masses protruding into the vessel lumen discontinuous from the surface of the vessel wall<sup>2)</sup>. OCT can identify intracoronary thrombus with high accuracy<sup>3)</sup>. Thrombus detected by OCT can present various form, but flap-like thrombus like the present case is uncommon. Prati et al. also presented a figure of flap-like thrombus<sup>2)</sup>, but the present case was interesting in the point that the size of flap was very large. It has been reported that OCT can distinguish the characteristics of thrombi. Red thrombi consist mainly of red blood cells; relevant OCT images are characterized as high-backscattering protrusions with signal free shadowing. White thrombi consist mainly of platelets and white blood cells and are characterized by

a signal-rich, low backscattering billowing projections protruding into the lumen<sup>4</sup>). In reality, pure white or red thrombi are rarely found; mixed thrombi, on the other hand, are common. It was unclear whether the flap-like thrombus in the present case was red or white thrombus. In general, when ulcerated or ruptured plaques present with thrombus on OCT, the lesion can be defined as a 'culprit'<sup>2</sup>). Thus, in acute phase of the present case, OCT was helpful to convince us that the culprit lesion was located in LAD side of the LAD-MSB bifurcation. In fact, this consideration was strongly supported by CAG findings in chronic phase.

In case 2, CAG showed occlusion in DB and TIMI-3 grade flow in main vessel of LAD. These findings might lead us to misunderstanding that DB was the culprit vessel unless we performed OCT. OCT clearly revealed ulcer with thrombi in LAD at the origin of DB. Thus, OCT findings convinced us that the culprit lesion was ulcerated plaque in LAD, not in DB. Furthermore, OCT detected microvessel formation in the inner plaque near the ulcer. It has been reported that neovascularization in atherosclerotic plaques is associated with plaque vulnerability<sup>5</sup>). The high resolution of OCT can provide chance to directly visualize plaque neovascularization in vivo<sup>6</sup>). There is a general consensus on OCT that microvessels in plaque appear as thin black holes with a diameter of 50–100 nm that are present for at least 3–4 consecutive frames in

pull-back images<sup>2)</sup>. In the present study, the presence of microvessels in the inner plaque near the ulcer may also support the opinion that culprit lesion was ulcerated plaque in LAD.

Thus, OCT can provide detail intracoronary information in addition to CAG and IVUS. Combinations of those imaging modality would be more helpful and reliable for detection of culprit lesion and understanding the mechanism of onset in acute coronary syndrome.



## References

1. Regar E, van Soest G, Bruining N, Constantinescu AA, van Geuns RJ, van der Giessen W, et al. Optical coherence tomography in patients with acute coronary syndrome. *EuroIntervention*. 2010; 6 Suppl G: G154-160.
2. Prati F, Regar E, Mintz GS, Arbustini E, Di Mario C, Jang IK, et al. Expert review document on methodology, terminology, and clinical applications of optical coherence tomography: physical principles, methodology of image acquisition, and clinical application for assessment of coronary arteries and atherosclerosis. *Eur Heart J*. 2010; 31: 401-415.
3. Meng L, Lv B, Zhang S, Yv B. In vivo optical coherence tomography of experimental thrombosis in a rabbit carotid model. *Heart*. 2008; 94: 777-780.
4. Kume T, Akasaka T, Kawamoto T, Ogasawara Y, Watanabe N, Toyota E, et al. Assessment of coronary arterial thrombus by Optical Coherence Tomography. *Am J Cardiol*. 2006; 97: 1713–1717.
5. Kolodgie FD, Gold HK, Burke AP, Fowler DR, Kruth HS, Weber DK, et al. Intraplaque hemorrhage and progression of coronary atheroma. *N Engl J Med*. 2003; 349: 2316-2325.
6. Kitabata H, Tanaka A, Kubo T, Takarada S, Kashiwagi M, Tsujioka H, et al.

Relation of microchannel structure identified by optical coherence tomography to plaque vulnerability in patients with coronary artery disease. *Am J Cardiol.* 2010; 105: 1673-1678.

## **Figure legends**

### **Figure 1.**

(A and B) CAG in the RAO-cranial view and the LAO-cranial view. (A1 and B1) CAG before thrombus aspiration showed occlusion in the proximal portion of LAD (white arrowheads). (A2 and B2) CAG after thrombus aspiration revealed the reperfusion of MSB and the remaining of occlusion of LAD (white arrows). (A3 and B3) CAG after 2-week of the onset showed the recanalized LAD (black arrowheads) with severe stenosis (black arrows) at a little distal to the LAD-MSB bifurcation. CAG, coronary angiography: RAO, right anterior oblique: LAO, left anterior oblique: LAD, left anterior descending artery: MSB, first major septal branch.

### **Figure 2.**

(A) Magnified image of the proximal LAD. Black arrowhead indicates the occlusion point of LAD. (B1,2 and C1,2) IVUS and OCT images at the bifurcation of LAD-MSB. Flap-like thrombus (white arrow) and plaque rupture (white arrowhead) are clearly visible by OCT, not by IVUS. IVUS, intravascular ultrasound: OCT, optical coherence tomography: Other abbreviations as in Figure 1.

**Figure 3.**

(A) CAG in the LAO-cranial view and (B) magnified image of the proximal LAD. The occlusion of DB and mild stenosis with ulcer in LAD at the origin of DB were identified. (C) Gross findings of the red thrombi removed from the proximal LAD. DB, first diagonal branch. Other abbreviations as in Figure 1.

**Figure 4.**

(A) Magnified image of the proximal LAD after thrombus aspiration. (B1-4 and C1-4) IVUS and OCT images. Compared to IVUS, OCT clearly showed lipid-rich plaque (asterisk), ulcer (star), white (arrows) and red (arrowhead) thrombi. (D) Magnified image of ulcerated plaque by OCT. Microvessel was visible (small arrowhead). Abbreviations as in Figure 1, 2, and 3.

Figure 1.

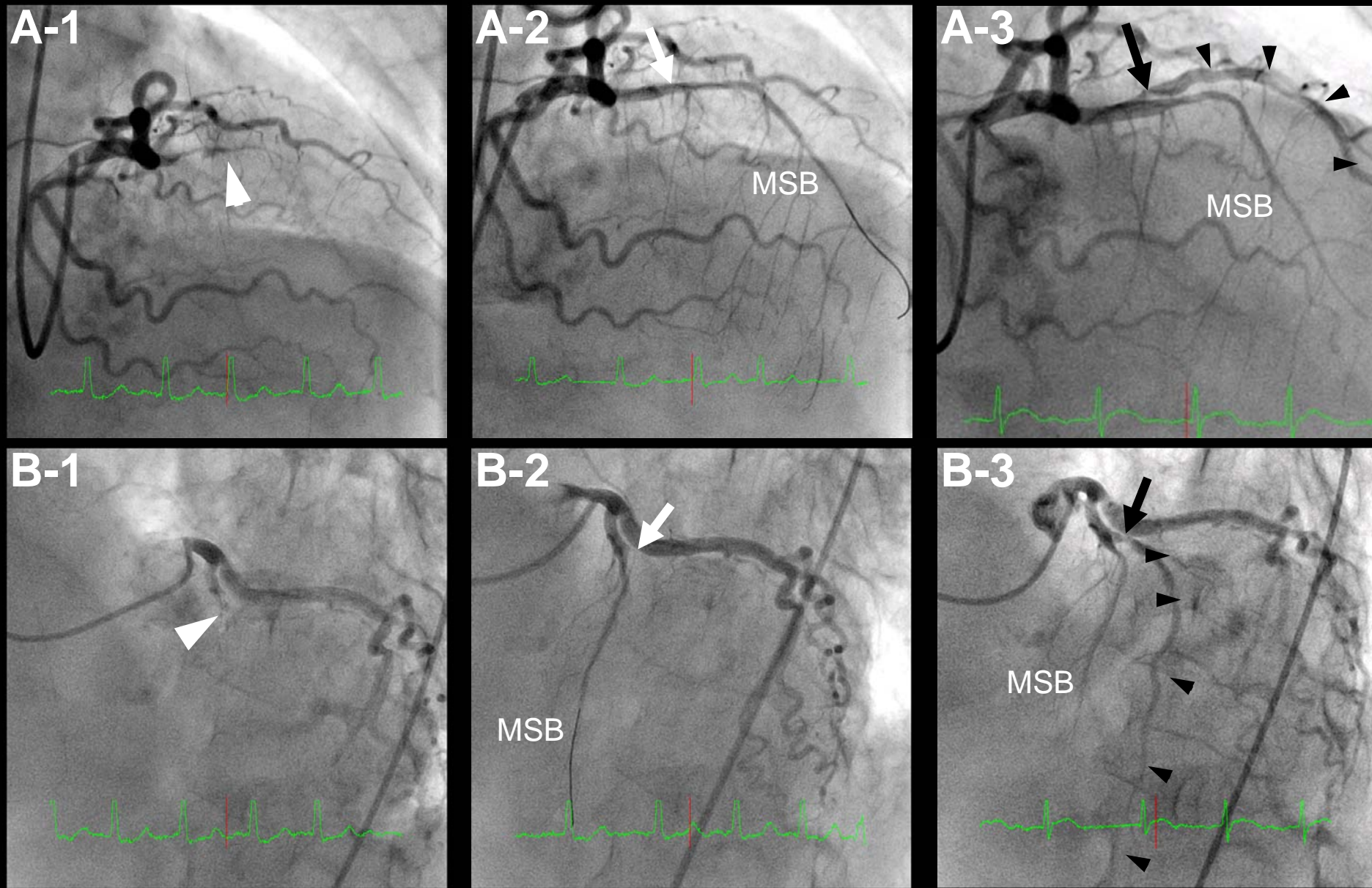


Figure 2.

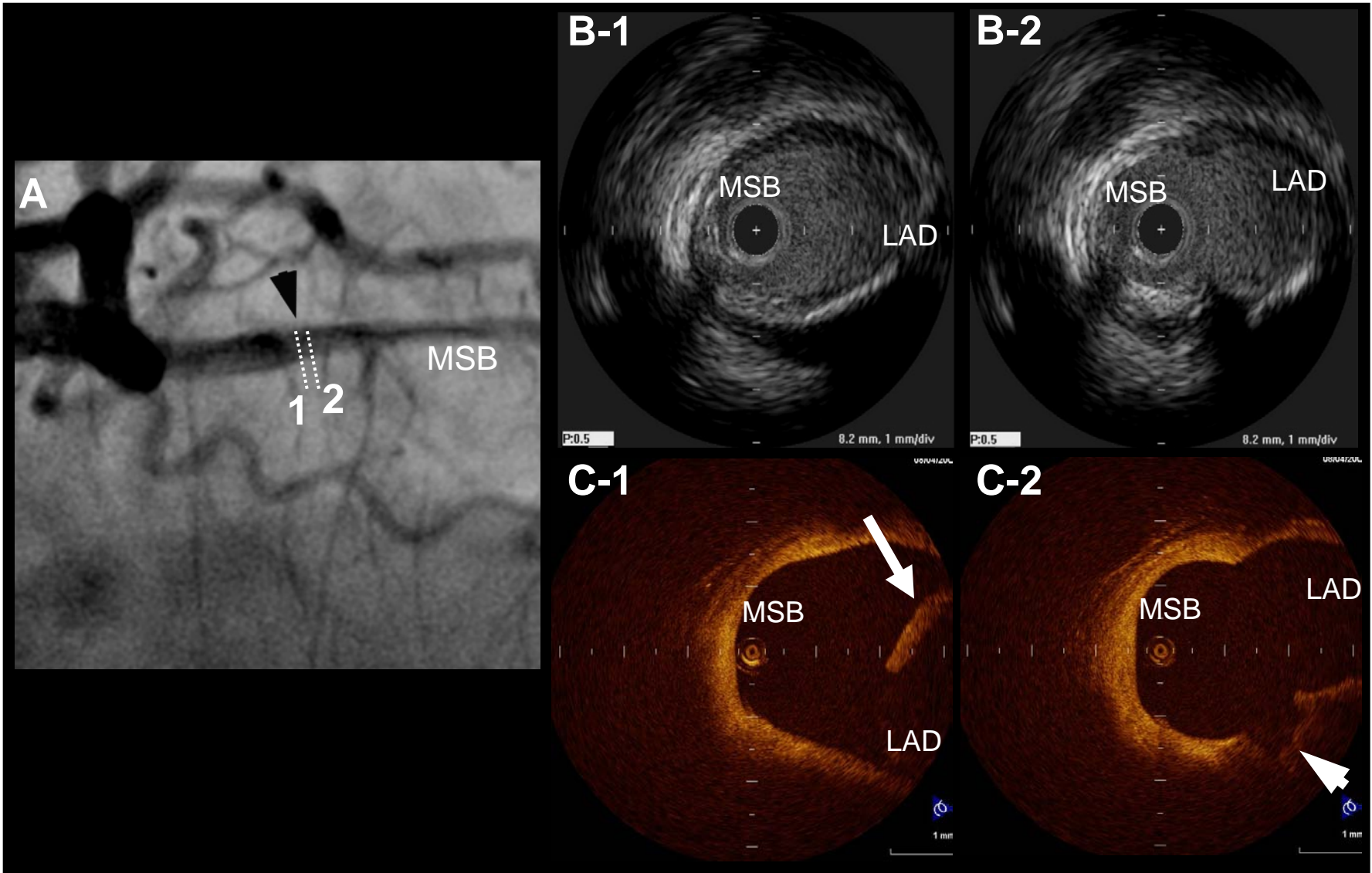




Figure 3.

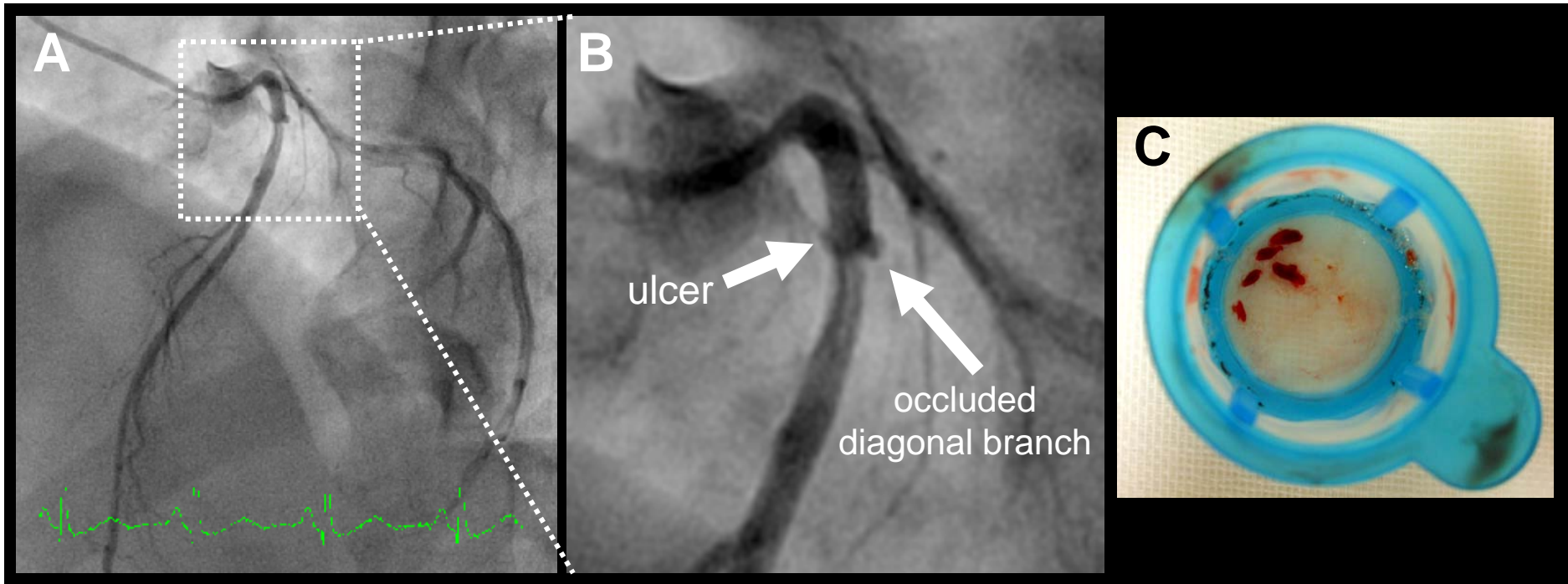


Figure 4.

