

Title: Tracheal Reconstruction Using S-shaped Skin Flaps and a Conchal Cartilage Graft

Running Head: Tracheal Reconstruction

Kenichi Kaneko,¹ MD, PhD; Koichi Sakaguchi,¹ MD; Atsushi Takano,¹ MD; Shinya Jinnouchi,¹ MD;

Kotaro Ishimaru,¹ MD, PhD; Haruo Takahashi,¹ MD, PhD

¹Department of Otolaryngology–Head and Neck Surgery, Nagasaki University Graduate School of

Biomedical Sciences

Total word count of the manuscript: 1119

Corresponding Author:

Kenichi Kaneko, MD, PhD

Department of Otolaryngology–Head and Neck Surgery, Nagasaki University Graduate School of

Biomedical Sciences

1-7-1 Sakamoto, Nagasaki 852-8501, Japan

Tel: +81-95-819-7349

Fax: +81-95-819-7352

E-mail: kkaneko@nagasaki-u.ac.jp

Abstract

We have devised a technique of two-stage tracheal reconstruction using S-shaped skin flaps and an aural conchal cartilage graft. During the first operation, S-shaped skin flaps were elevated before resection of the trachea. A tracheocutaneous fistula was created at the tracheal defect using S-shaped skin flaps while placing the conchal cartilage graft underneath. During the second operation, a skin incision was made around the fistula to elevate the hinge flaps, including the cartilage. The edges of the hinge flaps were sutured to form the tracheal lumen, and the area of the skin defect was then closed with double-rotation skin flaps.

Abstract word count: 100

Full-thickness window resection of the involved tracheal wall is an option when tumor invades the tracheal cartilage and lumen. However, tracheal reconstruction is still a challenging surgical technique because it requires a skeletal framework to maintain the lumen. We describe a new technique for tracheal reconstruction, a successful two-stage procedure using S-shaped skin flaps and an aural conchal cartilage graft, to create a temporary tracheocutaneous fistula following tracheal resection.

Technique

The patient was a 73-year-old woman with thyroid carcinoma invading the trachea and right recurrent laryngeal nerve. During the first operation, we performed total thyroidectomy and partial resection of the trachea with an S-shaped skin incision (Fig 1A) under general anesthesia. The skin flaps contained the platysma muscle. The tracheal defect was 3 cm in length, from the first to the fourth tracheal rings, and involved two-thirds of the circumferential width. The cricoid cartilage was left intact. The right recurrent laryngeal nerve was resected because of tumor invasion. We harvested a curved conchal cartilage (17 × 12 mm) with a perichondrium on its posterior surface, which was performed with a skin incision behind the auricle that was closed with a few primary sutures. We created a tracheocutaneous fistula using S-shaped skin flaps, placing the autologous conchal cartilage graft underneath the flap with its concave surface facing the tracheal lumen, and sutured the skin flaps to the mucosal margin of the trachea (Figs 1B, C).

During the second operation two months later, the tracheocutaneous fistula was closed under local

anesthesia; a skin incision was made around the fistula to elevate the hinge flaps containing the cartilage (Fig 2A). The edges of the hinge flaps were sutured to form the tracheal lumen. Then, the area of the skin defect was closed with double-rotation skin flaps that were designed using parts of the same incision as the first operation (Fig 2B, C). Fifteen months later, the fistula remained closed and the tracheal lumen was maintained without malacia.

Comment

Full-thickness window resection is frequently adopted when a tumor such as thyroid carcinoma invades the tracheal cartilage and lumen. We devised a technique of two-stage tracheal reconstruction using S-shaped skin flaps and a conchal cartilage graft. Our procedure consists of two steps. During the first operation, we create a tracheocutaneous fistula, placing the conchal cartilage graft underneath S-shaped skin flaps after tracheal resection. The second operation involves closing the fistula using the hinge flaps containing the conchal cartilage graft, followed by fixation with double-rotation flaps.

Using a free autograft of conchal cartilage is a simple, less invasive, and cost-effective way to create a skeletal support for the tracheal wall [1]. Harvesting conchal cartilage is relatively easy and the resulting defect not usually noticeable. S-shaped skin flaps also have certain advantages. Firstly, it is easy to create a long tracheocutaneous fistula, i.e., our unique S-shaped skin incision makes it easy for the skin edge to closely approach the edge of the tracheal wall. It is sometimes difficult to create a tracheocutaneous fistula after an ordinary collar incision when the tracheal defect is large. Secondly,

during the first operation, a cartilage graft can be placed next to the tracheal defect to be covered by the skin flap. Complete coverage of the cartilage by the skin flap is an ideal site for graft survival, and simultaneous placement of the cartilage and creation of the tracheocutaneous fistula avoids the need for further steps during tracheal reconstruction. Thirdly, after closing the tracheocutaneous fistula at the second operation, the area of the skin defect can be covered by double-rotation flaps designed using the incision from the first operation; this also provides better blood supply to the skin flaps.

The creation of a tracheocutaneous fistula after tracheal resection is safer than a primary reconstruction with regard to postoperative care for some patients, even though a second step is required to close the fistula. In particular, since the present case had poor pulmonary function and purulent sputa because of bronchiectasis, we decided to create a temporary tracheocutaneous fistula for respiratory control and for postoperative removal of tracheal sputa. A staged procedure also ensures correct tracheal reconstruction. We believe that the second operation should be performed at least three weeks after the first operation to optimize survival of the cartilage graft. When harvesting the graft, leaving the perichondrium attached to its posterior surface helps the graft to survive under the skin flap.

We consider this two-stage procedure for tracheal reconstruction to be safe, reliable, and easy to perform. This procedure can be applied to cases with a circumferential tracheal defect less than 360°.

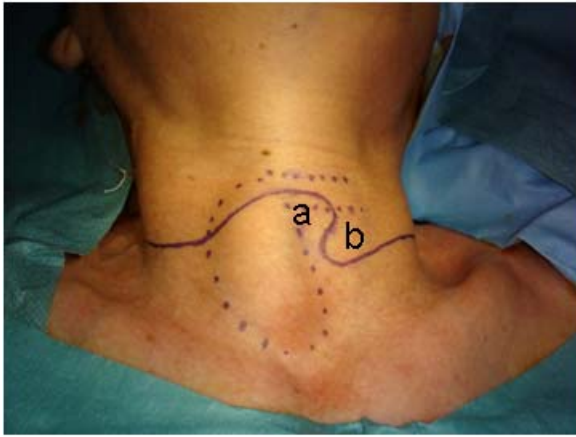
Conditions necessitating tracheal resection include tumor invasion and scar formation.

References

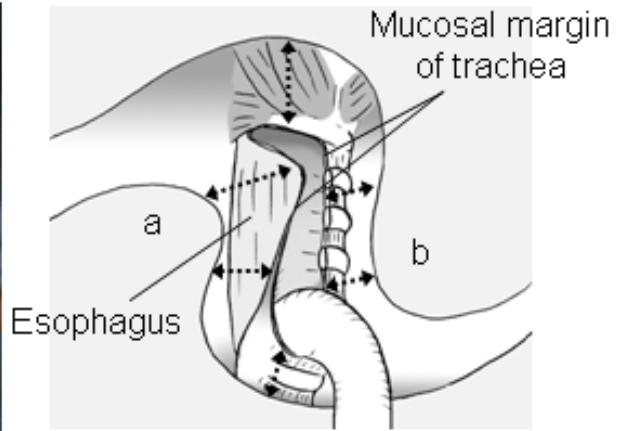
1. Sugeno A, Matsuo K, Asanuma K, et al. Management of tracheal wall resection for thyroid carcinoma by tracheocutaneous fenestration and delayed closure using auricular cartilage. *Head Neck* 1995;17:339–42.

Figure Legends

(A)



(B)



(C)

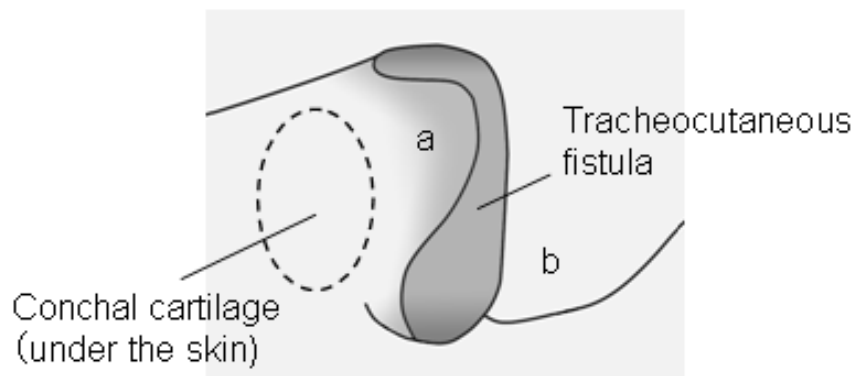
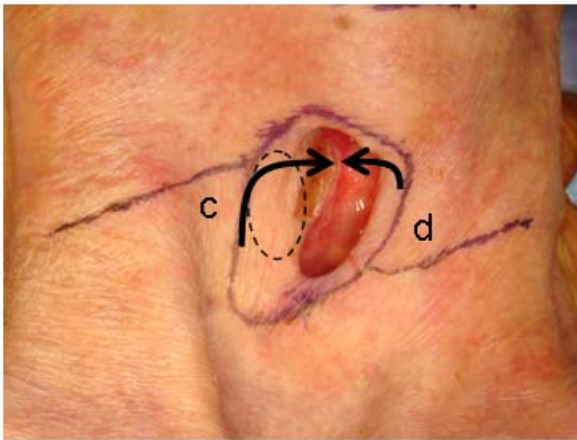
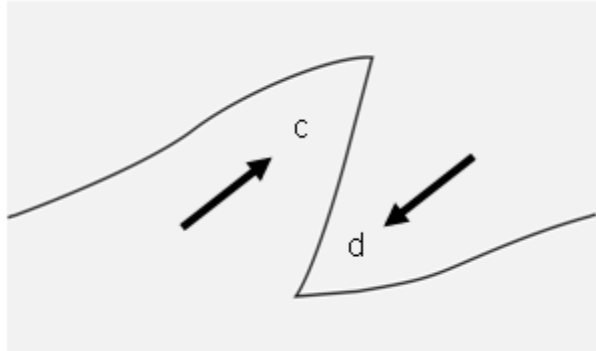


Fig 1. (A) Skin incision (solid line) and S-shaped skin flaps (a, b). Dotted lines indicate the cricoid cartilage and right lobe of the thyroid. (B) Relationship between tracheal defect and S-shaped skin flaps. Skin flaps were sutured to the mucosal margin of the trachea. (C) Tracheocutaneous fistula and conchal cartilage graft (dotted circle) under the skin flap.

(A)



(B)



(C)

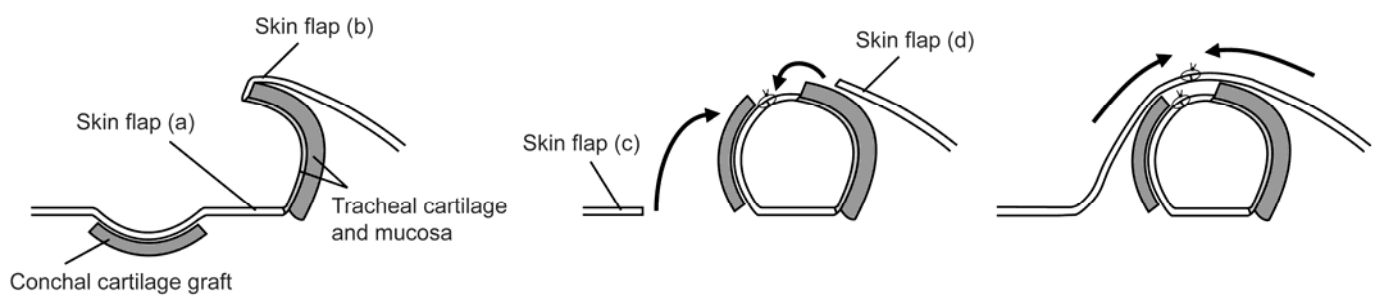


Fig 2. (A) Skin incisions around the tracheocutaneous fistula. Note that the incisions from the first operation were partially used. The edges of the hinge flaps containing the cartilage (dotted circle) were sutured to form the tracheal lumen (arrows); c, d: double rotation skin flaps. (B) The area of the skin defect closed by double-rotation skin flaps (c, d). (C) Coronal views of tracheal reconstruction.