

**Hand-assisted laparoscopic total pancreatectomy for a main duct intraductal papillary mucinous neoplasm of the pancreas**

Amane Kitasato, Yoshitsugu Tajima, Tamotsu Kuroki, Tomohiko Adachi, Takashi Kanematsu

Department of Surgery, Nagasaki University, Graduate School of Biomedical Sciences,  
1-7-1 Sakamoto, Nagasaki 852-8501, Japan

Correspondence to: Amane Kitasato, Department of Surgery, Nagasaki University,  
Graduate School of Biomedical Sciences, 1-7-1 Sakamoto, Nagasaki 852-8501, Japan

E-mail: a-kit@bg8.so-net.ne.jp

Telephone: +81-95-8197316

Fax: +81-95-8197319

Running title: HALS total pancreatectomy

Key words: Hand-assisted laparoscopic surgery, Total pancreatectomy, Intraductal papillary mucinous neoplasm

## **Abstract**

The laparoscopic approach to pancreatectomy entails a number of restrictions in performing major pancreatic surgery. This report describes a hand-assisted laparoscopic total pancreatectomy performed for a main duct IPMN of the pancreas. Dissection of the gastroduodenal artery and splenic artery, and the transection of the duodenum were done through the midline mini-laparotomy, while mobilization of the spleen and the pancreatic tail and body, and Kocher's maneuver were performed in the hand-assisted laparoscopic approach. Furthermore, dissection of lymph nodes in the hepatoduodenal ligament, removal of the gallbladder, division of the hepatic duct, tunneling of the pancreas, and dissection of the pancreas from the SMV and SMA were possible to perform safely under a pure laparoscopic technique with an excellent laparoscopic view. The reconstruction procedures were performed through the mini-laparotomy. The hand-assisted laparoscopic total pancreatectomy should be a considered for the treatment of selected patients because it has various advantages as one type of minimally invasive surgery.

## **Introduction**

Laparoscopic surgery has become widely accepted as a less invasive and effective approach in gastrointestinal fields.<sup>1, 2</sup> However, unlike laparoscopic distal pancreatectomy<sup>8</sup>, the performance of successful laparoscopic pancreaticoduodenectomy has been limited<sup>3-7</sup>. The laparoscopic approach entails a number of restrictions in the performance of major pancreatic surgeries. In contrast, hand-assisted laparoscopic surgery (HALS) allows us to perform advanced laparoscopic operations without appreciable loss of the advantages of the total laparoscopic approach. The assisting hand of the surgeon is used for palpation, easy exposure, optimal retraction, and immediate hemostasis. This report describes a hand-assisted laparoscopic total pancreatectomy for a main duct intraductal papillary mucinous neoplasm (IPMN) of the pancreas.

## **Patient**

A 72-year-old Japanese male was admitted to our hospital in February 2009 for further investigation of dilated main pancreatic duct with an elevation of serum carbohydrate antigen 19-9 (CA19-9) level of 156.3 U/ml (reference range, < 37 U/ml). Abdominal computed tomography (CT), magnetic resonance cholangiopancreatography (MRCP), and endoscopic retrograde cholangiopancreatography (ERCP) demonstrated a marked dilation of the entire main pancreatic duct from the pancreatic head to the tail, along with mural nodules in the pancreatic head, body and tail (Figures 1A, 1B). Upon examination by <sup>18</sup>F-fluorodeoxyglucose-positron emission tomography/computed tomography (FDG-PET/CT), we noted that there was an accumulation in the pancreatic

tail and a weak accumulation in the pancreatic head, thus corresponding to the mural nodules in the main pancreatic duct (Figure 1C). These findings were compatible with a diagnosis of main duct type IPMN of the pancreas with invasive carcinoma arising from IPMN. Because there was no evidence of extrapancreatic progression, invasion to the pancreatic nerve plexus, lymph node metastasis, nor distant metastasis, the patient was considered to be a candidate for HALS total pancreatectomy. The details of the surgery, and the risks and complications of this procedure were all explained to the patient, and informed consent to perform the surgery was obtained.

### **Surgical technique**

Under general anesthesia, the patient was placed in a supine position with his legs spread apart. A 7-cm mini-laparotomy was made in the upper midline of the abdomen. The gastrocolic ligament was then divided with a SonoSurg (Olympus, Tokyo, Japan) and the omental bursa was opened to visualize the anterior surface of the pancreas. The right gastroepiploic vessels were dissected and divided on the peripheral side. The duodenum was transected using an auto suture (Echelon 60, Johnson & Johnson Medical Pty Ltd, Cincinnati, OH) 3-cm distal to the pylorus ring. The gastroduodenal artery (GDA) and the splenic artery (SA) were dissected and divided.

#### *Hand-assisted laparoscopic surgery (HALS)*

The upper midline incision was covered with a Lap Disk (Hakko inc., Tokyo, Japan) for a hand port. After creating the pneumoperitoneum, a 12 mm trocar was

placed below the umbilicus for the laparoscope. Four additional 5 mm trocars were placed in the upper abdomen as shown in Figure 2. During the hand-assisted laparoscopic procedure, the splenocolic and gastrosplenic ligaments were divided with the SonoSurg. The spleen and the tail and body of the pancreas were mobilized from the retroperitoneum (Figure 3). Kocher's maneuver was then completed.

#### *Laparoscopic procedure*

A 12 mm trocar was installed in the Lap Disk of the midline incision, and laparoscopic procedures were performed. The hepatoduodenal ligament was skeletonized with the dissection of lymph nodes and the common hepatic and proper hepatic arteries were isolated. Next, the gallbladder was dissected from the liver bed and the cystic artery was divided. After the Treitz's ligament was divided using a SonoSurg, the proximal jejunum was transected with an auto suture (Echelon 60) and the mesentery of the jejunum and duodenum was dissected proximally. The superior mesenteric vein (SMV) was identified below the pancreatic lower border and the dorsal surface of the pancreas was bluntly dissected from the SMV-portal vein (PV). A 6-mm wide Penrose drain was then placed on the SMV as a guide for a safe dissection of the pancreatic parenchyma from the retroperitoneum, including the neural plexuses around the superior mesenteric artery (SMA). After transecting the common bile duct, lymph node dissection along the hepatoduodenal ligament was completed. Then, the spleen and the pancreatic body and tail were mobilized completely. Following the division of the splenic vein, the pancreatic specimen was moved to the right using the Penrose drain

placed on the SMV. This traction opened the plane to make the planned isolation line visible with a sufficient laparoscopic view (Figure 4). The uncinate process was then dissected off along the right lateral aspect of the SMV-PV using the SonoSurg. Finally, the pancreatic neural plexus connecting to the SMA was transected off of the postero-lateral aspect of the SMA under appropriate traction. The specimen was delivered from the peritoneal cavity through the midline incision.

### *Reconstruction*

The reconstruction procedures were performed through the small midline incision. The proximal jejunal stump was delivered through a window in the transverse mesocolon. An end-to-side hepaticojejunostomy was performed with 4-0 absorbable monofilament interrupted sutures. An antecolic end-to-side duodenojejunostomy was performed with 4-0 absorbable monofilament interrupted sutures on the 40cm anal side from the hepaticojejunostomy and the Braun anastomosis was added. A drainage tube was placed beneath the hepatoduodenal ligament.

The duration of the operation was 779 min, and operative blood loss was 1300g. A histological examination showed an invasive pancreatic carcinoma derived from IPMN in the tail of the pancreas. There was no invasion into the peripancreatic tissue, and no metastasis was observed in the dissected lymph nodes. Oral intake was started on the second postoperative day, and the abdominal drain was removed on the fifth postoperative day. Although postoperative patient education on blood sugar control and the occurrence of delayed gastric emptying required a prolonged hospitalization

with a postoperative hospital stay of 78 days, other postoperative complications, such as postoperative hemorrhage, bile leakage, intra-abdominal abscess, pulmonary complications, and deep vein thrombosis were not observed. The patient has been doing well without any evidence of recurrence of the carcinoma 7 months after surgery at the time of this writing.

## **Discussion**

IPMNs of the pancreas arise from the main pancreatic duct or its major branches, and present unique clinical features characterized by the massive production and accumulation of mucin in the pancreatic duct, cystic dilation of the main and/or branch pancreatic ducts, less aggressive biological behavior, and a better prognosis. However, main duct IPMNs are often malignant, with the incidence of malignancy of 60 to 92%, and approximately two-thirds of these malignant IPMNs become invasive.<sup>9</sup> Some reports have described that total pancreatectomy should be considered for patients with main duct IPMNs involving the entire pancreas when the patient's condition permits.<sup>10-12</sup> Recently, there have been increasing reports of successful laparoscopic pancreatectomies, however, laparoscopic total pancreatectomies have rarely been described in the literature.<sup>3,13,14</sup> Casadei *et al.*<sup>14</sup> reported a laparoscopically-assisted total pancreatectomy which consisted of a totally laparoscopic body-tail mobilization followed by the opening of a right subcostal mini-laparotomy in order to perform a pancreaticoduodenectomy and a reconstructive phase. In this study, we performed a total pancreatectomy for a patient with a main duct IPMN of the pancreas because the

tumor involved the entire main pancreatic duct, and the possibility of malignant transformation was considered to be high based on the preoperative diagnostic images. Because no extrapancreatic involvement of the tumor was observed, the laparoscopic approach was introduced to reduce surgical invasion, and the hand-assisted laparoscopic surgery was selected for the patient since a mini-laparotomy was necessary for removing the pancreatic specimen that was expected to be relatively large. We selected a midline incision for the mini-laparotomy because it would allow us to lengthen the incision if necessary. With a hand-assisted laparoscopic approach, mobilization of the spleen and the pancreatic tail and body, and Kocher's maneuver, which were difficult to perform through a mini-laparotomy, were performed safely. The procedure provided us with not only a good laparoscopic visualization, but also the convenience of hand assistance, such as manipulation of organs and easy control of unexpected bleeding. The next stage of the process was done using a full laparoscopic approach, because the surgeon's hand was inverted, and the operation was difficult to accomplish in HALS. In fact, lymph node dissection in the hepatoduodenal ligament, removal of the gallbladder, division of the hepatic duct, tunneling of the pancreas, and dissection of the pancreas from the SMV and SMA could be safely performed under a pure laparoscopic technique with an excellent laparoscopic view. When dissecting the neural plexuses between the pancreas head and the SMA, the laparoscopic pancreas-hanging technique, which tracts the pancreas to the right side using a Penrose drain, was especially useful and facilitated a secure dissection.

Although the duration of the operation was prolonged, and the total blood loss



thereby increased in our patient, we assumed that the hand-assisted laparoscopic total pancreatectomy would provide the patient with decreased wound pain because of the smaller size of the incision, decreased surgical stress, and less postoperative impairment of the immune system.<sup>4, 15</sup> The patient is still doing well as of the writing of this manuscript, demonstrating the safety and feasibility of this technique. A total pancreatectomy is a complex operation even in an open surgery, but the hand-assisted laparoscopic approach could become a treatment of choice for selected patients because it has various advantages as one type of minimally invasive surgery.

## References

1. Huscher CG, Mingoli A, Sgarzini G, Sansonetti A, Di Paola M, Recher A, et al. Laparoscopic versus open subtotal gastrectomy for distal gastric cancer. *Ann Surg* 2005; 241: 232-37
2. Veldkamp R, Kuhry E, Hop WC, Jeekel J, Kazemier G, Bonjer HJ, et al. Laparoscopic surgery versus open surgery for colon cancer: short-term outcomes of a randomized trial. *Lancet Oncol* 2005; 6: 477-84
3. Dulucq JL, Wintringer P, Stabilini C, Feryn T, Perissat J, Mahajna A. Are major laparoscopic pancreatic resections worthwhile? *Surg Endosc* 2005; 19: 1028-34
4. Palanivelu C, Jani K, Senthilnathan P, Parthasarathi R, Rajapandian S, Madhankumar MV. Laparoscopic pancreaticoduodenectomy: technique and outcomes. *J Am Coll Surg* 2007; 205: 222-30
5. Takaori K, Tanigawa N. Laparoscopic pancreatic resection: the past, present, and future. *Surg Today* 2007; 37: 535-45
6. Gagner M, Pomp A. Laparoscopic pylorus-preserving pancreatoduodenectomy. *Surg Endosc* 1994; 8:408-10
7. Cho A, Yamamoto H, Nagata M, Taniguchi N, Shimada H, Kainuma O, et al. A totally laparoscopic pylorus-preserving pancreaticoduodenectomy and reconstruction. *Surg Today* 2009; 39: 359-62
8. Melotti G, Butturini G, Piccoli M, Casetti L, Bassi C, Mullineris B, et al. Laparoscopic distal pancreatectomy: results on a consecutive series of 58 patients. *Ann Surg* 2007; 246: 77-82

9. Tanaka M, Chari S, Adsay V, Fernandez-del Castillo C, Falconi M, Shimizu M, et al. International consensus guidelines for management of intraductal papillary mucinous neoplasms and mucinous cystic neoplasms of the pancreas. *Pancreatology* 2006; 6: 17-32
10. Kim SG, Park KT, Lee YJ, Lee SS, Seo DW, Lee SK, et al. Intraductal papillary mucinoma neoplasm of the pancreas: clinical characteristics and treatment outcomes of 118 consecutive patients from a single center. *J Hepatobiliary Pancreat Surg* 2008; 10: 125-36
11. Inagaki M, Obara M, Kino S, Goto J, Suzuki S, Ishizaki A, et al. Pylorus-preserving total pancreatectomy for an intraductal papillary-mucinous neoplasm of pancreas. *J Hepatobiliary Pancreat Surg* 2007; 14: 264-69
12. Yamaguchi K, Konomi H, Kobayashi K, Ogura Y, Sonoda Y, Kawamoto M, et al. Total pancreatectomy for intraductal papillary-mucinous tumor of the pancreas: reappraisal of total pancreatectomy. *Hepato-gastroenterology* 2005; 52: 1585-90
13. Sa Cunha A, Rault A, Beau C, Laurent C, Collet D, Massaon B. A single-institution prospective study of laparoscopic pancreatic resection. *Arch Surg* 2008; 143: 289-95
14. Casadei R, Marchegiani G, Laterza M, Ricci C, Marrano N, Margiotta A, et al. Total pancreatectomy: doing it with a mini-invasive approach. *JOP* 2009; 18: 328-32
15. Tang CL, Eu KW, Tai BC, Soh JG, MacHin D, Seow-Choen F. Randomized clinical trial of the effect of open versus laparoscopically assisted colectomy on systemic immunity in patients with colorectal cancer. *Br J Surg* 2001; 88: 801-7

## Figure legend

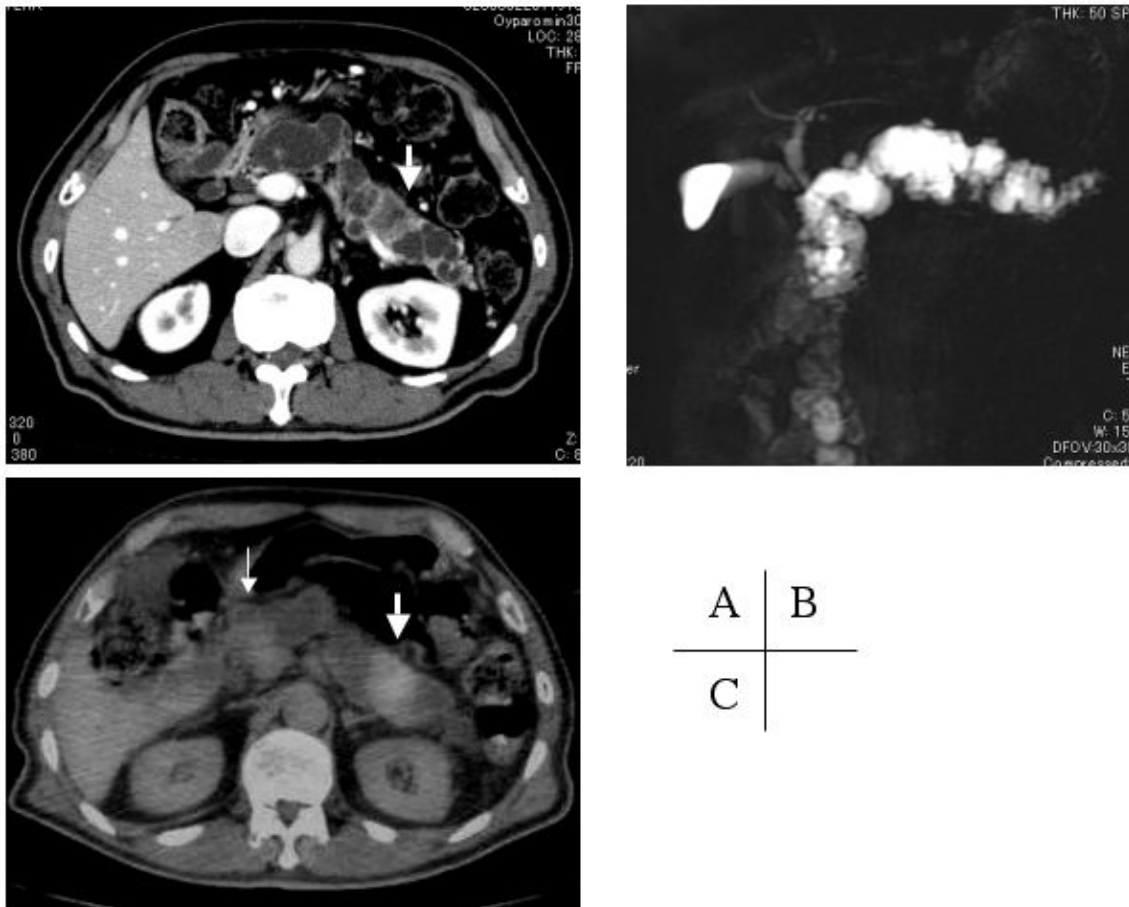


Figure 1

A: Contrast-enhanced abdominal computed tomography (CT) demonstrated a remarkable dilatation of the main pancreatic duct and mural nodules in the tail of the pancreas (arrow). B: Magnetic resonance cholangiopancreatography (MRCP) demonstrated a dilatation of the entire main pancreatic duct. C:  $^{18}\text{F}$ -fluorodeoxyglucose-positron emission tomography/computed tomography (FDG-PET/CT) showed a marked accumulation in the pancreatic tail (thick arrow) and a weak accumulation in the pancreatic head (thin arrow).

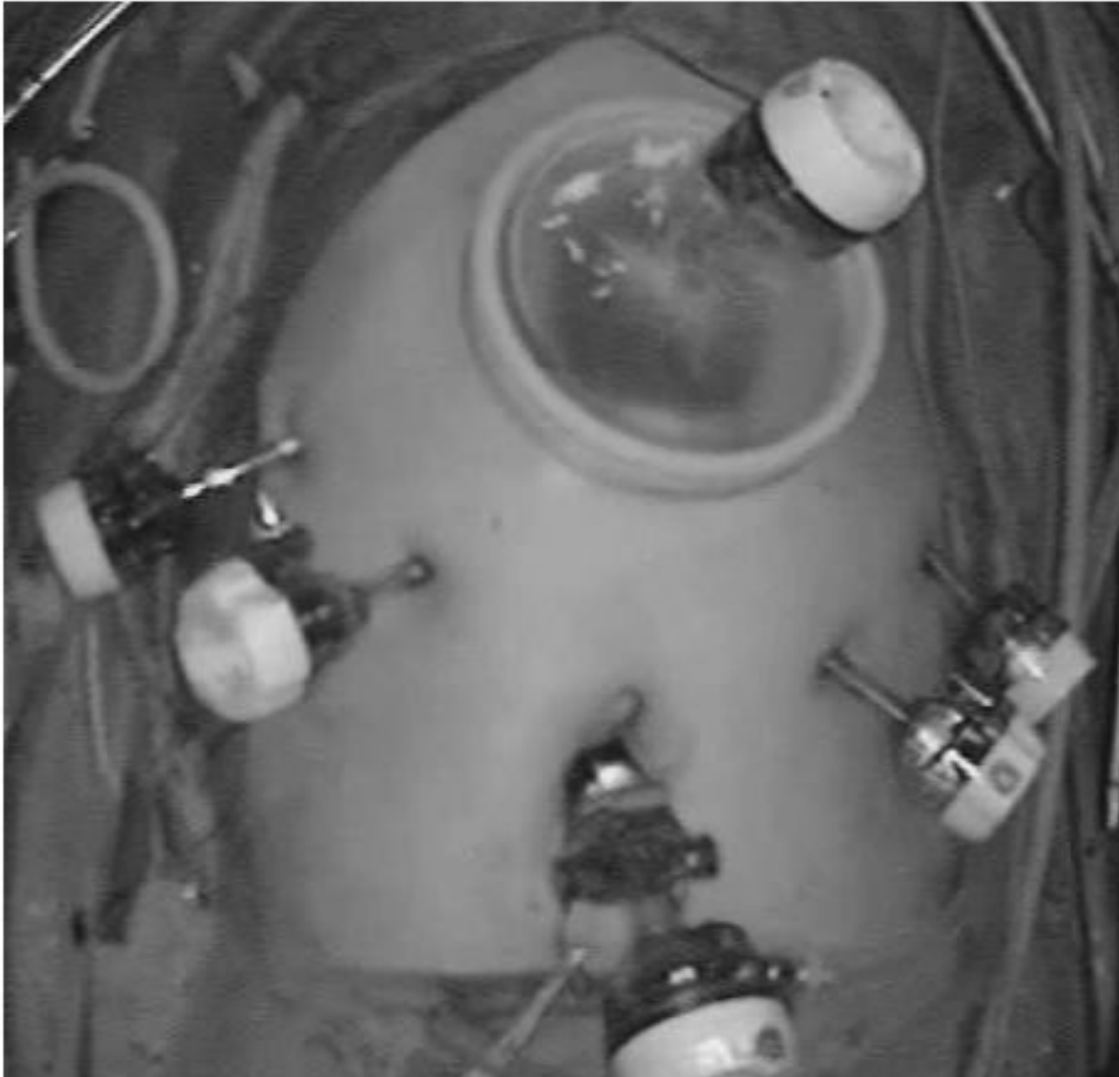

Figure 2

Port placement, and a 7-cm mini-laparotomy for a hand-assisted laparoscopic total pancreatectomy.

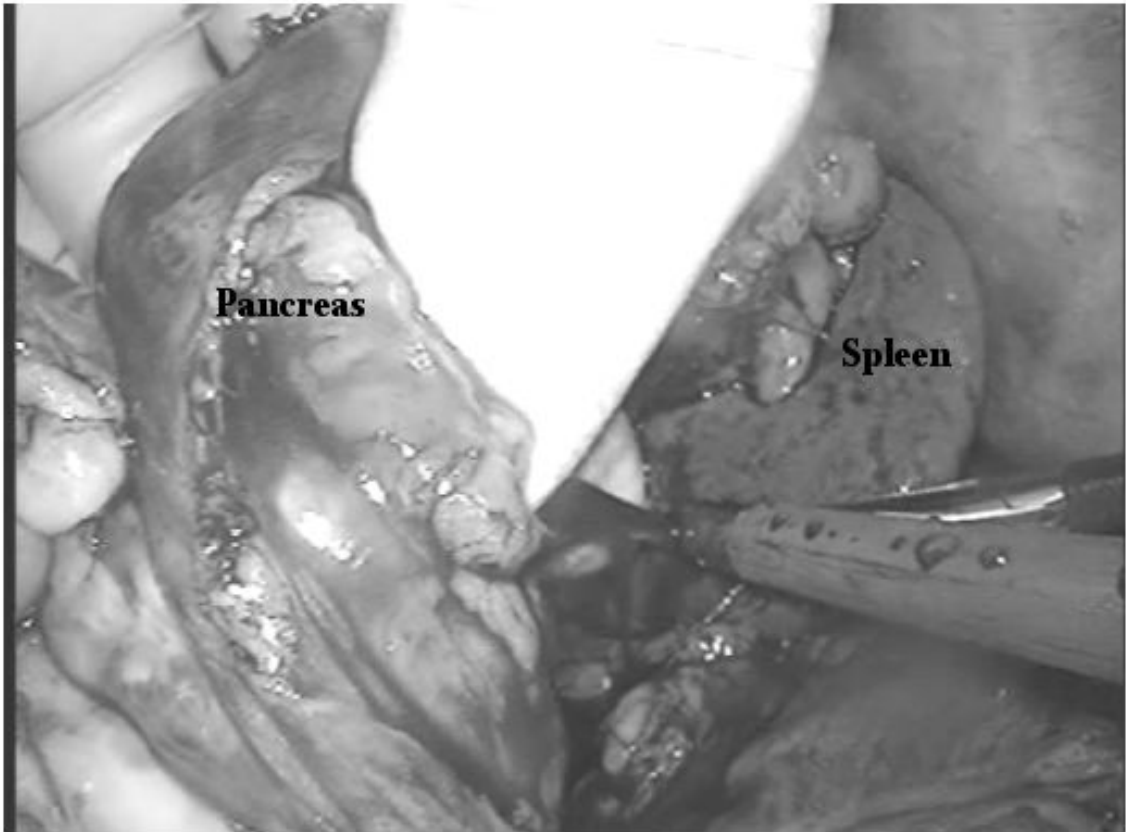


Figure 3

The spleen and the tail and body of the pancreas were mobilized from the retroperitoneum in the hand-assisted laparoscopic approach.

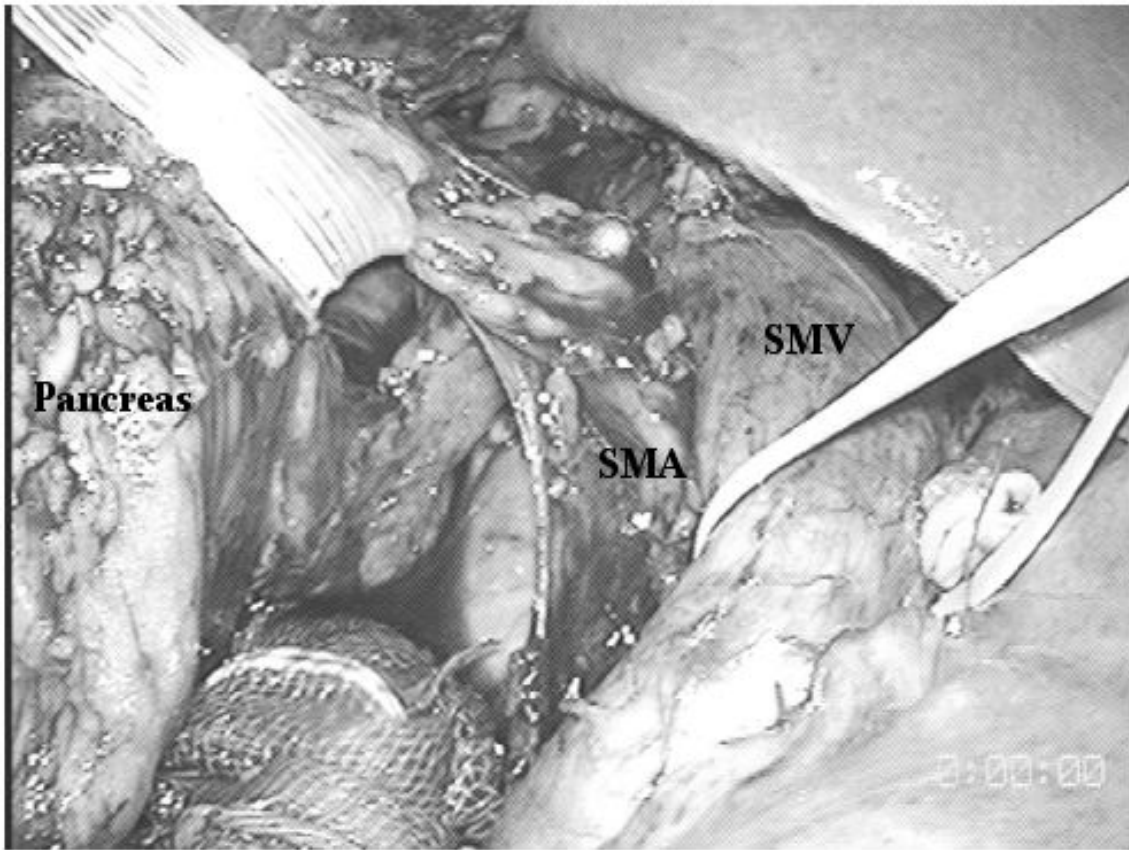


Figure 4

The specimen was tracted to the right using a 6mm Penrose drain placed between the pancreas and the superior mesenteric artery (SMA). The superior mesenteric vein (SMV) was tracted in the opposite direction using vessel tape.