

Original Article

**Dynamic contrast-enhanced magnetic resonance imaging to predict
pancreatic fistula after distal pancreatectomy**

**Tamotsu Kuroki, Yoshitsugu Tajima, Noritsugu Tsuneoka, Tomohiko
Adachi, and Takashi Kanematsu**

Department of Surgery, Nagasaki University Graduate School of
Biomedical Science, 1-7-1 Sakamoto, Nagasaki 852-8501, Japan.

Running Title: MRI to predict pancreatic fistula after distal
pancreatectomy.

Key words: Dynamic magnetic resonance imaging, time-intensity
curve, pancreatic fibrosis, pancreatic fistula, distal
pancreatectomy.

Please address reprint requests to: T. Kuroki

Fax: +81-95819-7319

E-mail: tkuroki-gi@umin.ac.jp

Abstract

Background: To identify risk factors for postoperative pancreatic fistula in patients undergoing distal pancreatectomy.

Methods: The study group was composed of 39 patients who had undergone distal pancreatectomy between January 2000 and June 2008. Fourteen presumed risk factors were retrospectively reviewed.

Results: Pancreatic fistula developed in 10 patients (25.6%). Pancreatic fibrosis estimated by dynamic contrast-enhanced magnetic resonance imaging (MRI) was the only predictor of pancreatic fistula formation after distal pancreatectomy ($P = 0.037$).

Conclusions: The preoperative evaluation of pancreatic fibrosis by dynamic MRI can provide reliable and objective information for predicting the risk of postoperative pancreatic fistula after distal pancreatectomy.

INTRODUCTION

Pancreatic fistula is one of the most common and serious complications after distal pancreatectomy ^[1], and various surgical techniques and devices have been proposed to prevent fistula formation ^[2-5]. The most appropriate strategy for managing a pancreatic stump is still controversial. On the other hand, several risk factors for postoperative pancreatic fistula have also been reported, including the texture of the remnant pancreatic parenchyma ^[6-8]. It is well known that the degree of pancreatic fibrosis influences the texture of the pancreatic gland. Recently, we have reported that a time-signal intensity curve (TIC) of the pancreas obtained from dynamic contrast-enhanced magnetic resonance imaging (MRI) is a reliable indicator of pancreatic fibrosis ^[9]. The aim of this retrospective study was to evaluate risk factors for pancreatic fistula after distal pancreatectomy. We report herein the usefulness of the preoperative pancreatic TIC analysis by using dynamic MRI for predicting pancreatic fistula formation after distal pancreatectomy.

PATIENTS AND METHODS

Patients

A retrospective review of a consecutive series of 39 patients who had undergone distal pancreatectomy between January 2000 and June 2008 at Nagasaki University Hospital was analyzed. There were 15 men and 24 women, with a mean age of 61.7 years (range, 30 to 81). Patient data obtained included age, gender, the pathology of pancreatic diseases, the concentrations of serum albumin, results of the oral glucose tolerance test (OGTT), hemoglobin A1c (HbA1c) levels, *N*-benzoyl-tyrosyl-*p*-aminobenzoic acid (BT-PABA) test results, pancreatic TIC profile examined at the proposed transection line for the pancreas, operating time, intraoperative blood loss, method for transacting the pancreas, concomitant splenectomy, texture of the remnant pancreas, and the diameter of the pancreatic duct. An abnormal glycemc response to the OGTT was defined according to the criteria proposed by the World Health Organization study group on diabetes mellitus ^[10]. To obtain pancreatic TICs, all patients underwent a dynamic MRI study of the pancreas prior to surgery. Procedures of pancreatic TIC have been described in detail elsewhere ^[9]. Briefly, the

dynamic series comprised five individual dynamic images, obtained before and 25 seconds and 1, 2, and 3 minutes after the rapid bolus injection of meglumine gadopentetate (Magnevist®; Schering, Berlin, Germany). The patterns of pancreatic TIC were classified into three types according to the time to peak: 25 s, 1 min, or 2 min after the bolus injection of contrast material; namely, types I, II, and III, respectively (Fig. 1). The type I pancreatic TIC indicated a normal pancreas without fibrosis, and types II and III indicated a fibrotic pancreas ^[9]. The textures of the pancreatic remnants at the transaction site were classified by the operating surgeon as soft (normal, friable), intermediate, or hard (fibrotic, sclerotic). The diameter of the main pancreatic duct was measured at the cut surface of the pancreatic remnant.

Diagnostic criteria for pancreatic fistula

Postoperative pancreatic fistulas were classified into three grades according to the clinical criteria established by the International Study Group on Pancreatic Fistula (ISGPF) ^[11]: Grade A, biochemical fistula without clinical sequelae; Grades B and C, signs of infection and clinical sequelae.

Statistical analysis

In strict accordance with the ISGPF classification scheme, the patients in this study were divided into two groups--patients who lacked clinical evidence of a fistula (no fistula or Grade A fistula) or patients with a clinically relevant pancreatic fistula (Grade B or C)--because Grade A pancreatic fistula has no clinical impact. ^[11] The eight preoperative and six intraoperative parameters were registered as presumed risk factors for postoperative pancreatic fistula. Statistical analysis was carried out using either the Mann-Whitney *U* test or Fisher's exact test. Differences were considered significant at $P < 0.05$.

RESULTS

There was no pancreatic fistula-related mortality in this study. The overall incidence of clinically relevant postoperative pancreatic fistula following distal pancreatectomy was 25.6% (10/39 patients). Among the preoperative parameters, there were no significant differences between the two groups in patient age, gender, pancreatic pathology, concentrations of serum albumin, the results of OGTT, HbA1c levels, or BT-PABA test results, excepting the pancreatic TIC (Table 1). A dynamic MRI study of the pancreas demonstrated that 28 patients were type I TIC and 11 cases were type II or III. Of the 28 patients with type I pancreatic TIC, 11 (35.7%) demonstrated a clinically relevant pancreatic fistula, whereas none of the 11 patients with type II or III pancreatic TIC displayed pancreatic fistula ($P = 0.037$). Meanwhile, there were no significant differences in the operative time, intraoperative blood loss, transaction of pancreas with stapler, concomitant splenectomy, texture of the remnant pancreas, or diameter of the pancreatic duct between the two patient groups (Table 2). Among the various presumed risk factors, therefore, the pancreatic TIC profile from dynamic MRI was the only

significant predictor of postoperative pancreatic fistula after distal pancreatectomy.

DISCUSSION

Several studies have shown that nonfibrotic pancreas is one of the most important risk factors for postoperative pancreatic fistula after distal pancreatectomy^[7, 8]. A recent study has demonstrated that patients with a nonfibrotic pancreas show a higher fistula rate, 44%, than do those with a fibrotic pancreas, presenting with a fistula rate of 5%, after distal pancreatectomy^[8]. Our previous report demonstrated that the pancreatic TIC profile from dynamic contrast-enhanced MRI offers a good reflection of the histologic degree of pancreatic fibrosis^[9]. Briefly, fibrosis percentages of the pancreas with type I, II, or III TIC were 3.5% (range 1.5% to 10.1%), 15.9% (range 7.5% to 25.2%), and 22.6% (range 17.8% to 27.3%), respectively. In the present study, the pancreatic TIC was identified as the only significant predictor of postoperative pancreatic fistula after distal pancreatectomy. In general, the degree of the pancreatic fibrosis reflects the texture of the pancreas. However, the texture of the pancreas is only a subjective parameter, because the judgment depends on the surgeon's palpation during operation. On the other hand, the pancreatic TIC analysis is an objective

parameter from dynamic MRI, and it can be obtained prior to surgery. If a patient shows type I pancreatic TIC, the patient faces the increased risk of pancreatic fistula after distal pancreatectomy. In such a case, several surgical techniques for the prevention of pancreatic fistula, including ultrasonic-activated scalpels^[12], prolamine injection^[13], or fibrin glue sealing^[4, 14] would be recommended. In addition, a planned perioperative octreotide administration may be helpful in reducing possible pancreatic fistula^[15]. Conversely, if a patient shows type II or type III pancreatic TIC, pancreatic fistula would not be expected to develop after distal pancreatectomy. Therefore, distal pancreatectomy in patients with type II or type III pancreatic TIC may be an appropriate operative experience in resident training programs.

Nonfibrotic pancreas represents challenges because it is easily crushed during the handling of the pancreatic stump and shows a high output of pancreatic juice. Our recent report found that type I pancreatic TIC was a significant risk factor for pancreatic fistula formation after pancreatic head resection^[16]. The pancreas demonstrating a type I TIC is thus associated with

a higher incidence of pancreatic fistula after pancreatic surgery, including both distal pancreatectomy and pancreatic head resection.

In conclusion, the preoperative assessment of the pancreatic TIC profile from dynamic MRI can provide reliable and objective information for predicting the risk of postoperative pancreatic fistula after distal pancreatectomy. When pancreatic TIC shows a type I profile, the optimal pancreatic stump management and the gentle handling of the pancreatic remnant are mandatory.

REFERENCES

- 1 Kuroki T, Tajima Y, Kanematsu T: Surgical management for the prevention of pancreatic fistula following distal pancreatectomy. *J Hepatobiliary Pancreat Surg* 2005; 12: 283-285
- 2 Misawa T, Shiba H, Usuba T, Nojiri T, Uwagawa T, Ishida Y, Ishii Y, Yanaga K: Safe and quick distal pancreatectomy using a staggered six-row stapler. *Am J Surg* 2008; 195: 115-118
- 3 Knaebel HP, Diener MK, Wente MN, Büchler MW, Seiler CM: Systemic review and meta-analysis of technique for closure of the pancreatic remnant after distal pancreatectomy. *Br J Surg* 2005; 92: 539-546
- 4 Suc B, Msika S, Fingerhut A, Fourtanier G, Hay JM, Holmieres F, Sastre B, Fagniez PL: Temporary fibrin glue occlusion of the main pancreatic duct in the prevention of intra-abdominal complications after pancreatic resection: prospective randomized trial. *Ann Surg* 2003; 237: 57-65
- 5 Kawai M, Tani M, Yamaue H: Transection using bipolar scissors reduces pancreatic fistula after distal

- pancreatectomy. *J Hepatobiliary Pancreat Surg* 2008; 15: 366-372
- 6 Sierzega M, Niekowal B, Kulig J, Popiela T: Nutritional status affects the rate of pancreatic fistula after distal pancreatectomy: a multivariate analysis of 132 patients. *J Am Coll Surg* 2007; 205: 52-59
- 7 Fahy BN, Frey CF, Ho HS, Beckett L, Bold RJ: Morbidity, mortality, and technical factors of distal pancreatectomy. *Am J Surg* 2002; 183: 237-241
- 8 Ridolfini MP, Alfieri S, Gourgiotis S, Miceli DD, Rotondi F, Quero G, Manghi R, Doglietto GB: Risk factors associated with pancreatic fistula after distal pancreatectomy, which technique of pancreatic stump closure is more beneficial? *World J Gastroenterol* 2007; 13: 5096-5100
- 9 Tajima Y, Matsuzaki S, Furui J, Isomoto I, Hayashi K, Kanematsu T: Dynamic magnetic resonance imaging to evaluate remnant pancreatic fibrosis. *Br J Surg* 2004; 91: 595-600
- 10 World Health Organization. Report of the expert committee on the diagnosis and classification on diabetes mellitus.

- Diabetes Care 1997; 20: 1183-1197
- 11 Bassi C, Dervenis C, Butturini G, Fingerhut A, Yeo C, Izbicki J, Neoptolemos J, Sarr M, Traverso W, Buchler M: Postoperative pancreatic fistula: an international study group (ISGPF) definition. *Surgery* 2005; 138: 8-13
- 12 Okabayashi T, Kobayashi M, Sugimoto T, Namikawa T, Okamoto K, Hokimoto N, Araki K: Postoperative pancreatic fistula following distal pancreatectomy for pancreatic neoplasm; can pancreatic fistula be prevented? *Hepatogastroenterology* 2004; 51: 1838-1841
- 13 Konishi T, Hiraishi M, Kubota K, Bandai Y, Makuuchi M, Idezuki Y: Segmental occlusion of the pancreatic duct with prolamine to prevent fistula formation after distal pancreatectomy. *Ann Surg* 1995; 221: 165-170
- 14 Suzuki Y, Kuroda Y, Morita A, Fujino Y, Tanioka Y, Kawamura T, Saitoh Y: Fibrin glue sealing for the prevention of pancreatic fistulas following distal pancreatectomy. *Arch Surg* 1995; 130: 952-955.
- 15 Buchler M, Friess H, Klempa I, Hermanek P, Sulkowski U, Becker H, Schafmayer A, Baca I, Lorenz D, Meister R: Role

of octreotide in the prevention of postoperative complications following pancreatic resection. *Am J Surg* 1992; 163: 125-130

- 16 Tajima Y, Kuroki T, Tsutsumi R, Fukuda K, Kitasato A, Adachi T, Mishima T, Kanematsu T: Risk factors for pancreatic anastomotic leakage: the significance of preoperative dynamic magnetic resonance imaging of the pancreas as a predictor of leakage. *J Am Coll Surg* 2006; 202: 723-731

FIGURE LEGEND

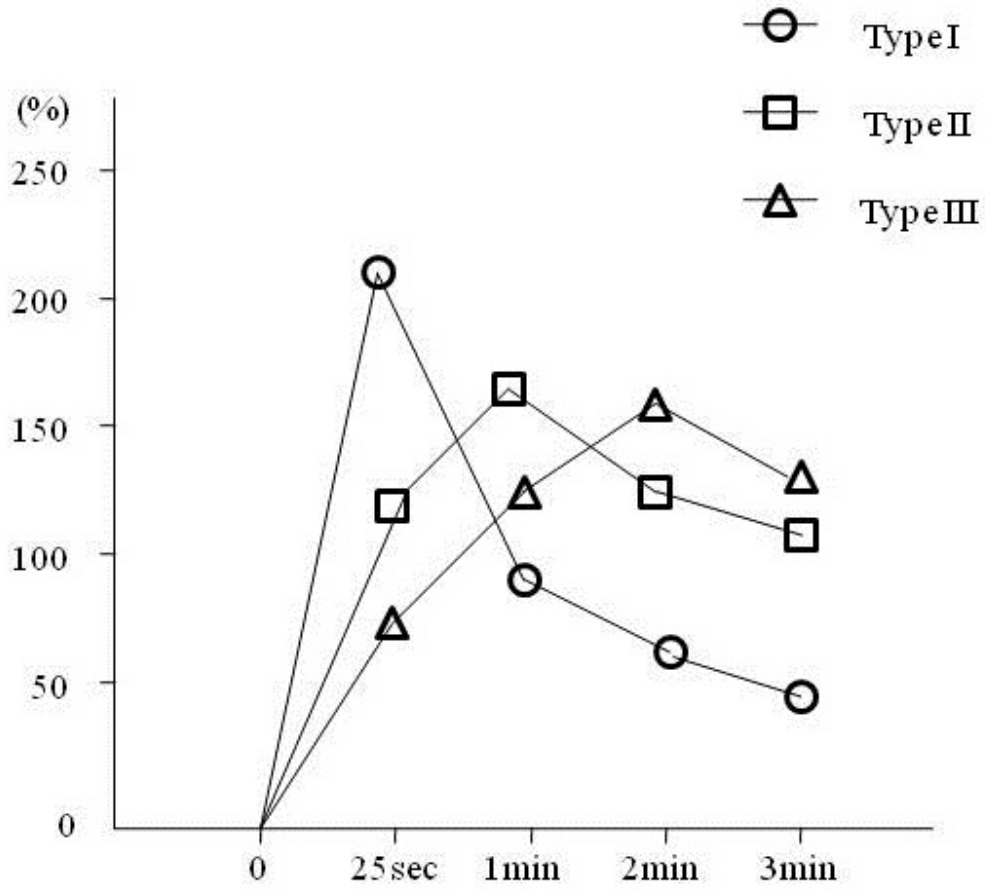


Figure 1. Patterns of the time-signal intensity curve (TIC) from dynamic MRI of the pancreas.

Table 1. Preoperative characteristics of 39 patients who underwent a distal pancreatectomy and risk factors for postoperative pancreatic fistula

	Pancreatic fistula		<i>P</i> value
	Yes (n=10)	No (n=29)	
Age, y (mean±SD)	59.9±8.8	61.7±15.3	N.S
Male/Female, n	5/5	12/17	N.S
Pathological diagnosis, n			
Pancreatic cancer	4	12	N.S
IPMN of the pancreas	3	8	
Chronic pancreatitis	0	3	
Islet cell tumor	1	2	
Mucinous cystic tumor	0	2	
Others	2	2	
Albumin, g/dL (mean±SD)	4.1±0.4	3.9±0.5	N.S
OGTT, n			
Normal	7	16	N.S
Impaired, diabetic	3	13	
HbA1c, %, n			
≤6.0	7	22	N.S
> 6.0	3	7	
BT-PABA test, % (mean±SD)	65.7±11.4	62.1±19.5	N.S
TIC of the pancreas, n			
Type I	10	18	0.037
Type II, III	0	11	

IPMN, intraductal papillary mucinous neoplasm; OGTT, oral glucose tolerance test; HbA1c, hemoglobin A1c; BT-PABA, *N*-benzoyl-tyrosyl-*p*-aminobenzoic acid; TIC, time-signal intensity curve.

Table 2. Intraoperative characteristics of 39 patients who underwent a distal pancreatectomy and risk factors for postoperative pancreatic fistula

	Pancreatic fistula		<i>P</i> value
	Yes (n=10)	No (n=29)	
Operative time, min (mean±SD)	359±87	360±118	N.S
Blood loss, g (mean±SD)	892±756	964±772	N.S
Transection of pancreas with stapler, n	3	2	N.S
Concomitant splenectomy, n	9	25	N.S
Texture of the pancreas, n			
Soft	8	17	N.S
Intermediate	1	7	
Hard	1	5	
Pancreatic duct size, mm, n			
≤ 3.0	8	23	N.S
> 3.0	2	6	