

Case Report

Percutaneous embolization with n-butyl-2 cyanoacrylate for the treatment of bile leakage after liver resection

Tamotsu KUROKI¹, Amane KITASATO¹, Takayuki TOKUNAGA¹, Hiroaki TAKESHITA¹, Ken TANIGUCHI¹, Shigeto MAEDA¹, Atsushi MIYAZAKI² & Hikaru FUJIOKA¹

¹ Department of Surgery, Nagasaki Medical Center, National Hospital Organization, Omura, Japan

² Department of Radiology, Nagasaki Medical Center, National Hospital Organization, Omura, Japan

Persistent bile leakage from an excluded segmental bile duct after liver resection is one of the intractable complications and difficult to manage. A 79-year-old male underwent left hepatectomy for hepatolithiasis. On postoperative day (POD) 6, bile leakage developed from the drain placed on the cut surface of the liver. On POD 19, a fistulography revealed bile leakage from B7-posterior biliary branch without connection to B6-posterior biliary branch or the common bile duct. On POD 21, we confirmed no communication between the common bile duct and the B7-posterior biliary branch by endoscopic retrograde cholangiography. We diagnosed a bile leakage due to an excluded segmental bile duct after liver resection. On POD 41, we performed embolization of n-butyl-2 cyanoacrylate (NBCA) with lipiodol via the percutaneous catheter. On the next day, the bile leakage decreased markedly. On POD 53, the drainage catheter was removed and he was discharge from hospital without any complaints or symptoms. There was no evidence of recurrent biliary leakage and symptom 8 months after the embolization. Percutaneous embolization with NBCA is a safe, feasible, and effective therapeutic strategy for an excluded bile leakage after liver resection.

ACTA MEDICA NAGASAKIENSIA 62: 39–42, 2018

Key words: n-butyl-2 cyanoacrylate (NBCA), bile leakage, excluded segmental bile duct

Introduction

One of the major complications of liver resection is bile leakage. Recent reports showed that the incidence of bile leakage after liver resection remains high in the range from 10.2 to 15.6% [1-3]. Most bile leakages resolve with proper conservative management, mainly persistent drainage. Nevertheless, when bile leakage is persistent, some patients require endoscopic and/or percutaneous interventional procedures. On the other hand, there are various degrees of severity in the bile leakage after liver resection. Persistent bile leakage due to an excluded segmental bile duct is intractable and difficult to manage, which carries higher rates of morbidities including sepsis,

liver failure, and longer hospital stay as well as postoperative mortality [4, 5]. Although few hepatobiliary surgeons encounter such an extremely rare and intractable complication, early recognition and definitive appropriate management is important. Here we report a case with bile leakage due to an excluded segmental bile duct after liver resection that was successfully treated with embolization of n-butyl-2 cyanoacrylate (NBCA).

Case Presentation

A 79-year-old Japanese male was admitted to our hospital for the management of hepatolithiasis with repeated acute

Address correspondence: Tamotsu Kuroki, Department of Surgery, Nagasaki Medical Center, National Hospital Organization, 2-1001-1, Kubara, Omura city, Nagasaki 856-8562, Japan.

Tel: +81-957-52-3121; Fax: +81-957-54-0292; Email: tkuroki-gi@umin.ac.jp

Received June 8, 2018; Accepted June 28, 2018

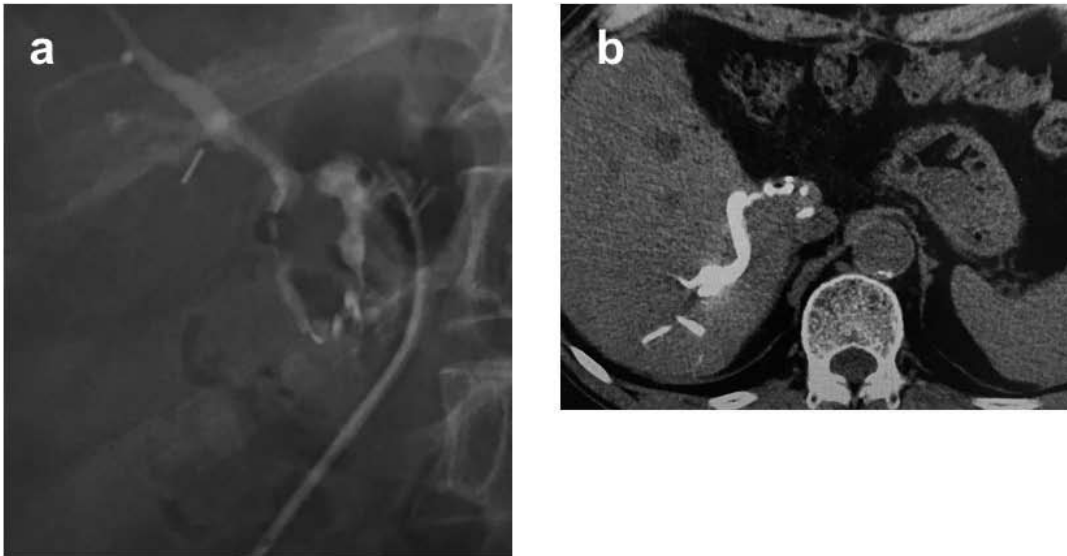


Figure 1a: A fistulography revealed bile leakage from the B7-posterior biliary branch without connection to B6-posterior biliary branch or the common bile duct.
b: The contrast media in the B7-posterior biliary branch was observed on computed tomography.

cholangitis. Abdominal computed tomography (CT) showed marked dilatation of the intrahepatic biliary tract in the left lobe. Laboratory studies revealed albumin of 3.7 g/dl (normal: 4.1-5.1), alkaline phosphatase (ALP) of 626 IU/L (normal: 106-322), and C-reactive protein of 0.37 mg/dl (normal: 0-0.14). Levels of serum AST, ALT, total bilirubin, and prothrombin time were within normal limits. Liver function was classified as type A using the Child-Pugh scoring system. He underwent left hepatectomy. There were no particular problems including bile leakage during the operation. The operation time was 256 min and intraoperative bleeding was 960 ml. At postoperative day (POD) 6, bile leakage developed from the cut surface of the liver. CT imaging revealed abdominal fluid collection around the cut surface of the liver. Percutaneous drainage via the drain placed during the operation was continued. On POD 19, a fistulography revealed bile leakage from B7-posterior biliary branch without connection to B6-posterior biliary branch or common bile duct (Fig. 1a). We confirmed that the contrast media accumulated in the B7-posterior biliary branch on CT (Fig. 1b). On POD 21, no communication between the injured B7-posterior biliary branch and common bile duct was observed by endoscopic retrograde cholangiography (ERC) (Fig. 2). The bile leakage continued at a rate of 100 to 230 ml per day. We diagnosed bile leakage due to an excluded segmental bile duct after liver resection. We continued simple drainage to reduce the volume in the cavity due to the bile leakage. Then, the percutaneous drain catheter was changed to 7-Fr catheter. The cavity was decreased and the drainage route was linearized.

We confirmed that the fistula was linearized by several fistulography with different angles. Laboratory studies revealed albumin of 2.9 g/dl, ALP of 1436 IU/L, and C-reactive protein of 2.06 mg/dl. There were no other abnormal laboratory data. On POD 41, we performed percutaneous embolization with NBCA for the treatment of bile leakage. First, 7-Fr sheath catheter was inserted from the fistula, and then Tacron

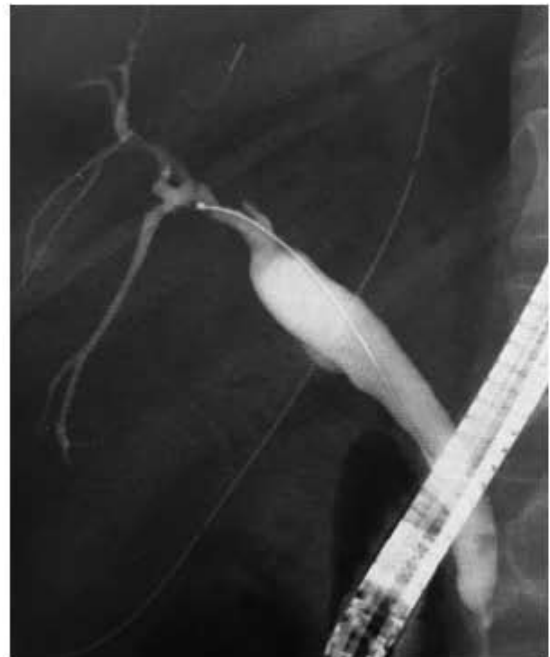

Figure 2: An endoscopic retrograde cholangiography showed no communication between common bile duct and the B7-posterior biliary branch.

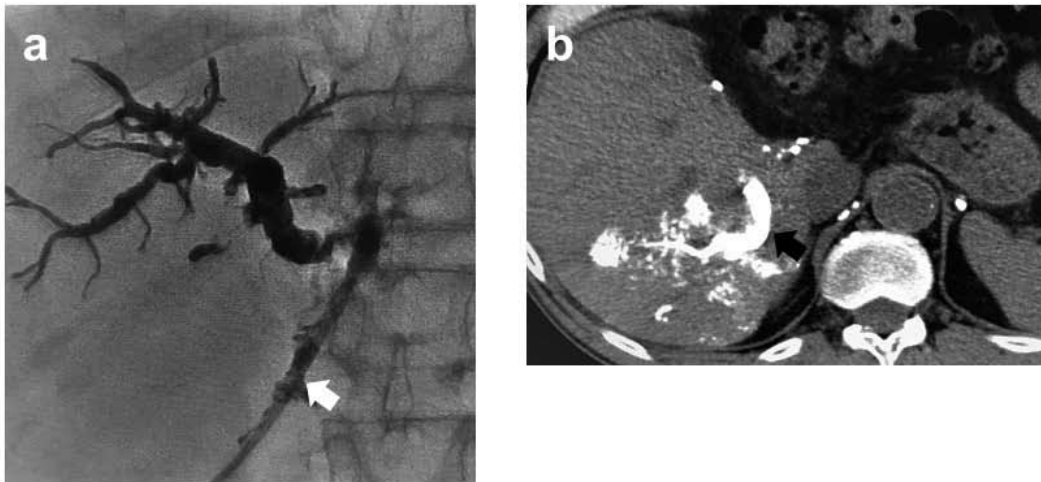


Figure 3a: Percutaneous embolization of the B7-posterior biliary branch with by n-buthyl-2 cyanoacrylate (NBCA) was performed, subsequently complete occlusion of that branch was confirmed. Arrow indicates the linearized abscess cavity with percutaneous drain catheter.
b: The NBCA in the B7-posterior biliary branch was confirmed on computed tomography (arrow).

NB[®] Advantage 5-Fr seeking catheter (COOK[®]) was inserted into the 7-Fr sheath catheter. Finally, the tip of Renegade[™] HI-FLO[™] microcatheter (Boston Scientific) was left with ASAHI CHIKAI black 0.014 guidewire (ASAHI INTECC CO., LTD.) at the B7-posterior biliary branch. 0.7 ml of NBCA with 6.3 ml of lipiodol via the microcatheter was injected and the B7-posterior biliary branch was filled with the NBCA-compound (Fig. 3a). Occlusion of the B7-posterior biliary branch was confirmed on CT (Fig. 3b). The next day, the bile leakage decreased markedly. On POD 53, the percutaneous drainage catheter was removed and he was discharged without any complaints or symptoms. At 8 months after the embolization, CT imaging reveals occlusion of the B7-posterior biliary branch without abscess formation in the liver or intra-abdomen (Fig. 4), and neither evidence of recurrent biliary

leakage nor develop of symptoms.

Discussion

Nagano et al. [4] provided a classification of bile leakage as the four different types. Among the four types, an excluded segmental bile duct leakage is the most troublesome complication after liver resection. This type of bile leakage is difficult to manage, because it is a persistent bile leakage from the isolated bile duct with a normal liver parenchyma without a connection between the injured bile duct and the main biliary system. Liver resection of an isolated biliary region is an effective and definitive treatment for an excluded segmental bile duct leakage. Fukuhisa et al. [6] reported a case of Spiegel lobe excision for the excluded bile leakage from Spiegel lobe after right hemihepatectomy. However, liver resection is accompanied by many difficulties such as severe adhesion, fragile tissue, easy bleeding, and misidentification in anatomy [7]. On the other hand, Sadakari et al. [8] reported successfully management for an excluded bile leakage of posterior branch by percutaneous transhepatic portal embolization. The theory of this strategy is that the embolized liver segment becomes non-functional and produces no bile. Shimizu et al. [9] reported a case of excluded bile leakage managed successfully by intrahepatic biliary ablation with absolute ethanol via the retrograde transhepatic biliary drainage tube which was inserted under open surgery on POD 46. An absolute ethanol is one of the effective sclerosing agents for biliary ablation. There have been no reported severe complications with the use of

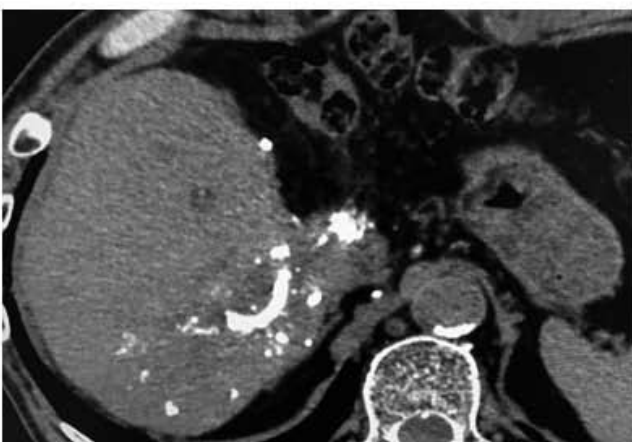


Figure 4: The follow-up computed tomography revealed occlusion of the B7-posterior biliary branch without abscess formation in the liver or intra-abdominal 8 months after the embolization.

absolute ethanol for biliary ablation. Transient abdominal pain during excessive ethanol ablation has been reported as a side effect. On the other hand, ethanol biliary ablation therapy for bile leakage often requires multiple treatments, which results in prolongation of the hospital stay [10]. Bae et al. [11] reported successful percutaneous NBCA embolization for management of persistent biliary or enteric fistulas including 4 patients who showed persistent bile leakage from the injured bile duct after radiofrequency ablation for hepatocellular carcinoma. Percutaneous fistula tract is an optimal route for the embolization of an isolated bile duct using NBCA. In order to fill the isolated bile duct with NBCA, the percutaneous fistula tract need to be linearized. In our patient, isolated bile duct was detected by fistulography via the percutaneous catheter with the linearized route of the intraperitoneal drain which was placed on the cut surface of the liver at the operation. Therefore, it is important to place the postoperative intraperitoneal drain in a straight line and at the shortest distance. If there is a connection between the injured bile duct and main biliary system, endoscopic approach is effective for the management. Terajima et al. [12] reported that endoscopic nasobiliary drainage (ENBD) is an effective strategy for bile leakage after liver resection, when an injured bile duct is recognized to have communication with main biliary system on fistulography or to have an extravasation of contrast media on ERC imaging. Such cases have a good indication for ENBD. The effectiveness of the ENBD for the bile leakage is due to the biliary decompression. In addition, an ENBD tube in common bile duct can provide a repeated cholangiography for evaluation of the status of bile leakage. Wright et al. [13] reported a case with persistent biliary leakage despite sphincterotomy and biliary stenting, who was successfully managed using endoscopic biliary NBCA injection. In conclusion, percutaneous embolization with NBCA is a safe, feasible, and effective therapeutic strategy for the excluded bile leakage after liver resection, and should be considered as an alternative treatment to salvage hepatectomy.

References

1. Sadamori H, Yagi T, Shinoura S, et al. Risk factors for major morbidity after liver resection for hepatocellular carcinoma. *Br J Surg* 100: 122-129, 2013
2. Kajiwara T, Midorikawa Y, Yamazaki S, et al. Clinical score to predict the risk of bile leakage after liver resection. *BMC Surgery* 16: 30, 2016
3. Panaro F, Hacina L, Bouyabrine H, Al-Hashmi AW, Herrero A, Navarro F. Risk factors for postoperative bile leakage: a retrospective single-center analysis of 411 hepatectomies. *Hepatobiliary Pancreat Dis Int* 15: 81-86, 2016
4. Nagano Y, Togo S, Tanaka K, et al. Risk factors and management of bile leakage after hepatic resection. *World J Surg* 27: 695-698, 2003
5. Capussotti L, Ferrero A, Vigano L, Sgotto E, Muratore A, Polastri R. Bile leakage and liver resection: where is the risk? *Arch Surg* 141: 690-694, 2009
6. Fukuhisa H, Sakoda M, Hiwatashi K, et al. Surgical treatment for the excluded bile leakage from Spiegel lobe after right hemihepatectomy: a case report. *Int J Surg Case Rep* 39: 159-163, 2017
7. Honoré C, Vibert E, Hoti E, Azoulay D, Adam R, Castaing D. Management of excluded segmental bile duct leakage following liver resection. *HPB* 11: 364-369, 2009
8. Sadakari Y, Miyoshi A, Ohtsuka T, et al. Percutaneous transhepatic portal embolization for persistent bile leakage after hepatic resection: report of a case. *Surg Today* 38: 668-671, 2008
9. Shimizu T, Yoshida H, Mamada Y, et al. Postoperative bile leakage managed successfully by intrahepatic biliary ablation with ethanol. *World J Gastroenterol* 12: 3450-3452, 2006
10. Saad WE, Darcy MD. Percutaneous management of biliary leaks: biliary embosclerosis and ablation. *Tech Vasc Interv Radiol* 11: 111-119, 2008
11. Bae JH, Kim GC, Ryeom HK, Jang YJ. Percutaneous embolization of persistent biliary and enteric fistulas with histoacryl. *J Vasc Interv Radiol* 22: 879-883, 2011
12. Terajima H, Ikai I, Hatano E, et al. Effectiveness of endoscopic nasobiliary drainage for postoperative bile leakage after hepatic resection. *World J Surg* 28: 782-786, 2004
13. Wright G, Jairath V, Reynolds M, Shidrawi RG. Endoscopic glue injection for persistent biliary leakage. *Gastrointest Endosc* 70: 1279-1281, 2009