

## Case Report

# Primary Omental Myxoid Leiomyosarcoma: Report of a Case and a Review of the Literature

Chieko TANEDA,<sup>1</sup> Tomayoshi HAYASHI,<sup>1</sup> Terumitsu SAWAI,<sup>2</sup> Ichiro ISOMOTO,<sup>3</sup> Kuniko ABE,<sup>1</sup> Naoe KINOSHITA,<sup>1</sup> Masanobu ANAMI,<sup>1</sup> Satoshi NAKASHIMA,<sup>1</sup> Kohei KOTERA,<sup>4</sup> Hideaki MASUZAKI,<sup>4</sup> Takeshi NAGAYASU<sup>2</sup>

<sup>1</sup>Department of Pathology, Nagasaki University Hospital, Nagasaki, Japan

<sup>2</sup>Division of Surgical Oncology, Translational Medical Sciences, Nagasaki University Graduate School of Biomedical Science, Nagasaki, Japan

<sup>3</sup>Unit of Translational Medicine, Department of Radiological Science, Nagasaki University Graduate School of Biomedical Sciences, Nagasaki, Japan

<sup>4</sup>Department of Obstetrics & Gynecology, Nagasaki University Hospital, Nagasaki, Japan

A 41-year-old Japanese woman who presented with right lower abdominal pain underwent partial omental resection with tumor excision, leaving no residual tumor. The tumor was diagnosed as a myxoid leiomyosarcoma that apparently originated in the greater omentum.

A recurrent omental tumor was excised at 4.5 months after the first operation, and then at 5.5 months after this, CT revealed metastatic sarcoma at the surface of the liver (S7) and the left upper abdomen. She died 20 months after the last operation despite treatment of the metastases with MAID therapy (mesna, adriamycin, ifosfamide, dacarbazine).

A literature review revealed that this tumor mainly occurs in the uterus, soft tissue, and cardiovascular system, with a preponderance among middle-aged to elderly women. The present report is the first description of primary omental myxoid leiomyosarcoma.

ACTA MEDICA NAGASAKIENSIA 54: 21 - 24, 2009

**Keywords:** Myxoid leiomyosarcoma; Omentum; Literature review

## Introduction

Myxoid leiomyosarcoma is an unusual variant of leiomyosarcoma.<sup>1-3</sup> This type of tumor rarely arises in the abdominal cavity<sup>1</sup> and when found in this location, the origin is usually the uterus.<sup>4</sup> No reports of primary omental myxoid leiomyosarcoma were found from a search of the PubMed database. The tumor cells appear well differentiated into smooth muscle cells, exhibit relatively little atypia,<sup>5</sup> have abundant myxoid matrix, and a low-grade appearance with relatively few mitotic figures; however, the prognosis is unfavorable.<sup>1,6</sup> We describe a rare case of primary myxoid leiomyosarcoma that originated in the omentum.

## Case report

A 41-year-old Japanese woman presented with right lower abdominal pain. Uterine myoma was tentatively diagnosed on

ultrasonography and magnetic resonance imaging (MRI), and the patient was referred to our hospital for further examination. The personal and family history were unremarkable.

MRI revealed a 4 cm intramural uterine myoma, and a 7 × 7 × 6 cm mass with a smooth margin was located adjacent to the anterior surface of the uterus. The latter mass was slightly hyperintense on T1-weighted images (Figure.1A) and strongly hyperintense on T2-weighted images (Figure.1B). T1-weighted post-contrast images showed peripheral enhancement at the antero-inferior part of the mass (Figure.1C). Uterine subserosal myoma with myxoid change was suspected from these findings.

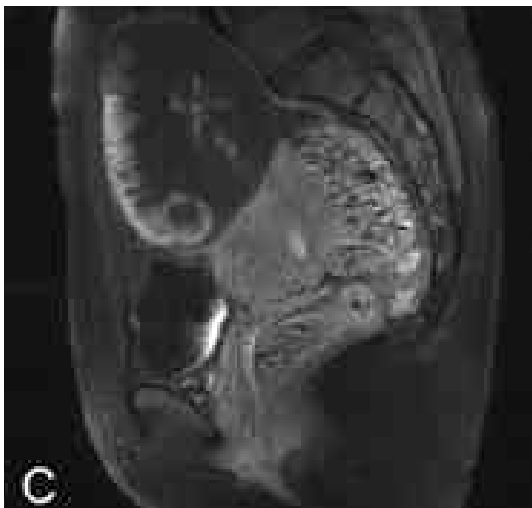
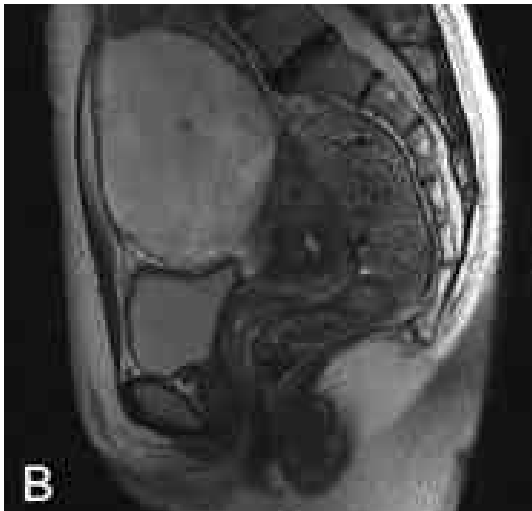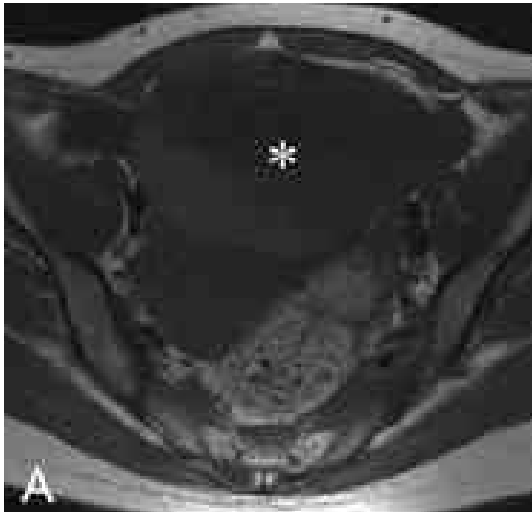
Since the tumor had enlarged to 11 × 10 × 7 cm in 2 months on follow-up MRI, malignant potential was suspected and the tumor was resected surgically 2 months after the MRI.

Bloody serous abdominal fluid (1,470 ml) was found during surgery. Cytodiagnosis of the fluid suggested malignancy. A 30 × 20 × 10 cm, pale yellow to white myxoid mass was found in the greater omentum comprising a cystic gelatinous area and an 8-cm

**Address correspondence:** Tomayoshi Hayashi, M.D., Ph.D., Department of Pathology, Nagasaki University Hospital, 1-7-1 Sakamoto, Nagasaki 852-8501, JAPAN

TEL: +81-(0)95-819-7562, FAX: +81-(0)95-819-7564, E-mail: toma@nagasaki-u.ac.jp

Received November 20, 2008; Accepted June 5, 2009



**Figure 1.** Magnetic resonance imaging findings of the omental tumor. A mass located adjacent to the anterior surface of uterus (\*) shows slight hyperintensity on a T1-weighted image (1A) and strong hyperintensity on a T2-weighted image (1B). A T1-weighted post-contrast enhanced image shows peripheral enhancement at the anteroinferior part of the mass (1C).

soft solid area (Figure.2). It resembled both peritoneal pseudomyxoma and leiomyosarcoma. The tumor was partially ruptured and the gelatinous matrix was exposed to the omental surface. The uterus itself was unremarkable except for a 3-cm intramural myoma. The mesentery of the stomach and transverse colon were not involved. The tumor was completely excised with partial omental resection.

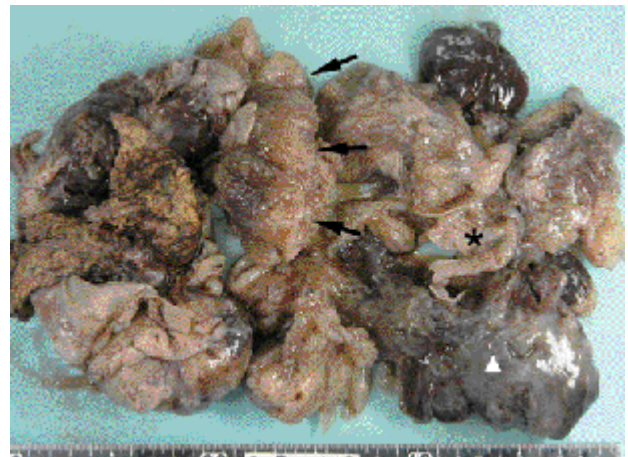On histopathological examination, the tumor comprised an extensive myxoid matrix. Spindle-shaped tumor cells with minimal atypia and an eosinophilic cytoplasm proliferated in ill-defined bundles or in interlacing patterns (Figure.3). Many vacuoles were present in the cytoplasm. There were up to 17 mitoses per 10 high power fields (HPF).

Immunohistochemical staining was positive for  $\alpha$  SM actin, HHF-35 (focal), and vimentin, and negative for desmin, HBME-1, calretinin,  $\alpha$  1 antitrypsin, S-100, CD34, and c-kit. The lesion was thus diagnosed as myxoid leiomyosarcoma.

At 1 month after the first surgery, follow-up abdominal CT revealed a 2.5 cm low density omental mass that subsequently enlarged to 3.2 cm within 2.5 months. The omental mass was resected and histopathologic examination confirmed that it was a recurrence of the previous tumor.

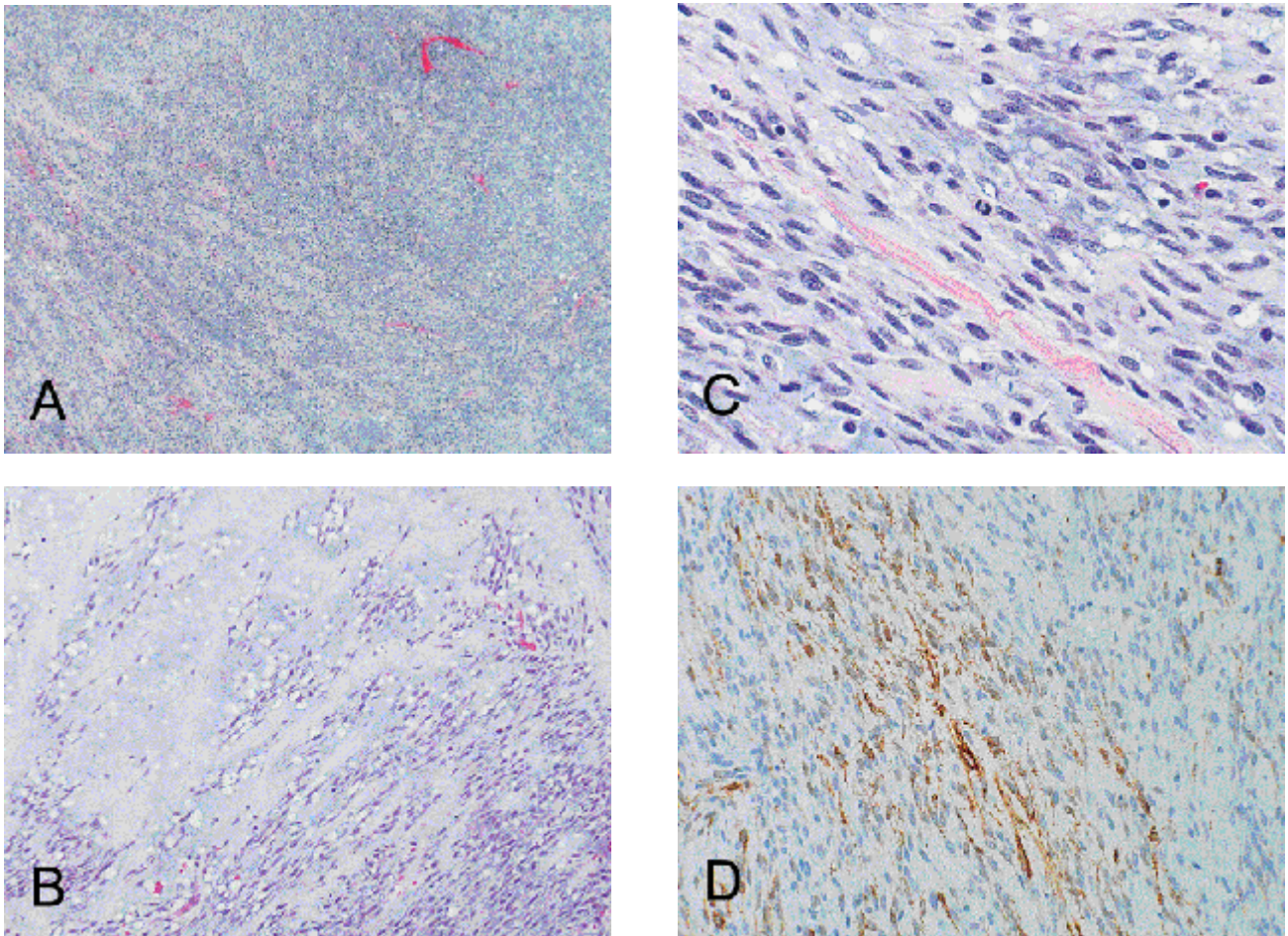
At 5.5 months after the second surgery, CT revealed peritoneal dissemination at the surface of the liver (Figure.4) and the left upper abdomen.

Although the patient was treated with MAID therapy (mesna, adriamycin, ifosfamide, and dacarbazine) for the metastases, she died 20 months after the last operation.



**Figure 2.** Gross findings of the omental tumor

A 30 × 20 × 10 cm, pale yellow to white myxoid mass is visible in the greater omentum comprising a cystic gelatinous area (\*) and an 8-cm soft solid area ( ). It resembles both peritoneal pseudomyxoma and leiomyosarcoma. The tumor is partially ruptured and gelatinous matrix is exposed to the omental surface (arrows).



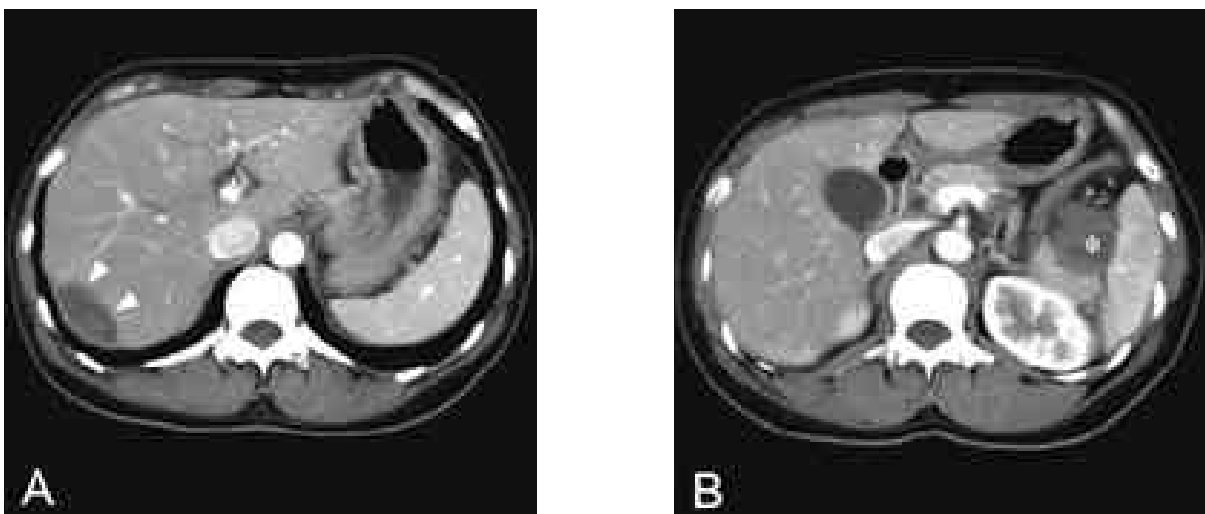
**Figure 3.** Pathological findings of the tumor

A. Tumor proliferation in an ill-defined interlacing pattern with abundant myxoid matrix (HE  $\times 40$ ).

B. Spindle cells are floating in a slightly basophilic to slightly eosinophilic myxoid matrix. There are areas of low (left upper area) and high (right lower area) cellularity (HE  $\times 100$ ).

C. High magnification of a highly cellular area. Spindle-shaped cells with narrow eosinophilic cytoplasm proliferate in a fascicular pattern. There is a mitosis at the center (HE  $\times 400$ ).

D. Tumor cells are immunohistochemically positive for a SM actin ( $\times 200$ ).



**Figure 4.** Computed tomography at recurrence, 5.5 months after second surgery

Peritoneal dissemination at the surface of the liver (A, arrowheads) and the left upper abdomen (B, \*).

## Discussion

Myxoid leiomyosarcoma is extremely unusual<sup>1-3</sup> and rarely occurs or disseminates in the abdominal cavity.<sup>1</sup> Our search of the PubMed database and the Japanese literature revealed only 94 reports of myxoid leiomyosarcoma. Among these, 41 originated in the uterus, 28 in soft tissue, 7 in the cardiovascular system, 4 in the ovary, 4 in the stomach, 2 in the liver, 2 in the esophagus, 2 in the prostate, and 1 each in the lung, kidney, parotid, and urinary bladder. The age ranged from 16 to 88 years (mean 52.7 years), and the male: female ratio was 15:79 (excluding female-specific organs such as the uterus and ovaries, M:F = 15:34). When limited to women, the age ranged from 20 to 85 years (mean 51.6 years). To the best of our knowledge, primary omental myxoid leiomyosarcoma has not been previously described; the present report appears to be the first such case.

Pathologically, the tumor cells had abundant myxoid matrix, and cellular features with smooth-muscle differentiation. The pathogenesis of myxoid change has not been established. One previous study indicates that such tumors are less atypical and have fewer mitotic figures (0-2/10HPF) than conventional leiomyosarcoma.<sup>6</sup> However, contrary to the rather bland appearance, the reported prognosis of patients with this type of tumor is unfavorable.<sup>1,6</sup> King et al. concluded that since 4 of their 6 patients died of the tumor, it must be considered fully malignant.<sup>6</sup> They also speculated that spillage of the grossly gelatinous matrix at the time of surgery might contribute to the common phenomenon of local recurrence.<sup>6</sup> The tumor had already ruptured before our patient underwent surgery, which must have led to dissemination and multiple recurrences. The myxoid matrix in the abdominal cavity must not be exposed during surgery. In addition, the high mitotic count of up to 17/10HPF might have been another reason for the poor outcome.

Differential diagnoses include myxoid endometrial stromal sarcoma, myxoid leiomyoma, low-grade myxofibrosarcoma,<sup>2</sup> nerve sheath neoplasm,<sup>5</sup> and mesothelioma. Immunohistochemical staining was important for our patient, since the results for smooth muscle were positive and those for nerve sheath neoplasm, histiocytes, and mesothelial differentiation were negative.

A treatment strategy for myxoid leiomyosarcoma has not yet been established,<sup>7</sup> and surgery has mostly been the first line of treatment.<sup>4,7,8,9</sup> We administered MAID therapy, which has been established for treating sarcoma in soft tissue,<sup>10</sup> and the patient has survived on this regimen for 20 months.

We described a rare case of primary myxoid leiomyosarcoma that originated in the omentum. The tumor gave rise to multiple metastases, and the patient died despite MAID therapy.

## Acknowledgement

The authors express heartfelt thanks to Christopher D. M. Fletcher, M.D. F.R.C.Path, Brigham & Women's Hospital, Boston, for valuable advice about the precise pathologic diagnosis.

This work was supported in part by a Nagasaki University President's Fund Grant.

## References

1. Malhotra M, Sharma JB, Wadhwa L, Singh S. Disseminating myxoid leiomyosarcoma of the uterus. *Arch Gynecol Obstet* 271: 166-7, 2005
2. Botsis D, Koliopoulos C, Kondi-Pafitis A, Creatas G. Myxoid leiomyosarcoma of the uterus in a patient receiving tamoxifen therapy: a case report. *Int J Gynecol Pathol* 25: 173-5, 2006
3. Vigone A, Giana M, Surico D, Leutner M, Surico N. Massive myxoid leiomyosarcoma of the uterus. *Int J Gynecol Cancer* 15: 564-7, 2005
4. Yasui W, Oda N, Ito H, Ichiba Y, Tahara E. Myxoid leiomyosarcoma of the stomach: a case report. *Jpn J Clin Oncol* 21: 447-52, 1991
5. Christopher D.M. Fletcher. *Diagnostic Histopathology of Tumors, Volume 2, Second ed.* (Churchill Livingstone) pp.1512, 2000
6. Weiss SW, Goldblum JR. *Enzinger and Weiss's Soft Tissue Tumors, Fourth ed.* (Mosby) pp. 736, 2001
7. Kagami S, Kashimura M, Toki N, Katuhata Y. Myxoid leiomyosarcoma of the uterus with subsequent pregnancy and delivery. *Gynecol Oncol* 85: 538-42, 2002
8. Tjalma WA, Colpaert CG. Myxoid leiomyosarcoma of the vulva. *Gynecol Oncol* 96: 548-51, 2005
9. King ME, Dickersin GR, Scully RE. Myxoid leiomyosarcoma of the uterus. A report of six cases. *Am J Surg Pathol* 6: 589-98, 1982
10. Goto T, Kosaku H, Kobayashi H, Hozumi T, Kondo T. [Soft tissue sarcoma: post-operative chemotherapy] *Gan To Kagaku Ryoho* 31: 1324-30, 2004 [in Japanese]