

**Original Article**

**Gastric Wall-Covering Method Prevents Pancreatic Fistula After  
Distal Pancreatectomy**

**Tamotsu Kuroki, Yoshitsugu Tajima, Noritsugu Tsuneoka, Tomohiko  
Adachi, and Takashi Kanematsu**

Department of Surgery, Graduate School of Biomedical Sciences,  
Nagasaki University, 1-7-1 Sakamoto, Nagasaki 852-8501, Japan.

Running Title: Gastric wall-covering method prevents pancreatic  
fistula.

Key words: pancreatic fistula, distal pancreatectomy, gastric  
wall-covering method.

Please address reprint requests to: T. Kuroki

Fax: +81-95819-7319

E-mail: [tkuroki-gi@umin.ac.jp](mailto:tkuroki-gi@umin.ac.jp)

**ABSTRACT**

**Background/Aims:** Pancreatic fistula is the most common complication after distal pancreatectomy. The aim of this study was to evaluate retrospectively the usefulness of a new surgical technique, the gastric wall-covering method, after distal pancreatectomy.

**Methodology:** The study group consisted of 53 patients who underwent distal pancreatectomy. The management of the stump of the remnant pancreas was accomplished by the gastric wall-covering method (GWC group, n=20) or by conventional surgery (CS group, n=33). In the gastric wall-covering method, the cut surface of the pancreas is fixed to the posterior wall of the gastric body.

**Results:** There were no significant differences in operating time, intraoperative blood loss, or texture of the remnant stump between the two groups. Postoperative pancreatic fistula was diagnosed in 1 patient (5.0%) in the GWC group and in 12 patients (36.4%) in the CS group ( $P=0.01$ ).

**Conclusions:** The gastric wall-covering method for the management of the pancreatic stump after distal pancreatectomy reduces the incidence of postoperative pancreatic fistula.

## **INTRODUCTION**

Pancreatic fistula is one of the most common and serious complications after distal pancreatectomy (1, 2), and two recent large series studies have found that postoperative pancreatic fistula affects more patients after distal pancreatectomy than after pancreaticoduodenectomy (3, 4). Pancreatic fistula may cause several secondary complications such as intra-abdominal abscess, subsequent sepsis or massive hemorrhage from the pseudoaneurysm in the artery (2). In addition, pancreatic fistula-related complications may lead to increased hospital costs. Therefore, several surgical techniques have been developed for the management of the stump of the remnant pancreas following distal pancreatectomy in order to prevent pancreatic fistula, including mattress sutures (5), automatic suture stapling (6, 7), prolamine injection (8) and fibrin glue sealing (9, 10). Nevertheless, management of the stump remains difficult and controversial. We recently reported a gastric wall-covering method as a novel technique in pancreatic surgery for the prevention of pancreatic fistula in which the cut surface of the pancreas is covered completely with the gastric wall (11, 12). The aim of the present

study was to evaluate the usefulness of the gastric wall-covering method in distal pancreatectomy.

## **PATIENTS AND METHODS**

### **Patients**

The subjects were a consecutive series of 53 patients who underwent distal pancreatectomy between 1996 and 2007 at Nagasaki University Hospital. There were 23 men and 30 women with a mean age of 59.8 years (range, 17 to 84); 20 patients were in the gastric wall-covering (GWC) group and 33 were in the conventional surgery (CS) group. Conventional management of the stump of the remnant pancreas following distal pancreatectomy, such as mattress sutures (n=21) and automatic suture stapling (n=11), was used until March of 2005, at which point management was changed to the gastric wall-covering method. Distal pancreatectomy was performed for a variety of indications (Table 1).

### **Surgical procedures for the management of the cut surface of the remnant pancreas**

Following isolation of the spleen and the distal pancreas from the retroperitoneum, the splenic artery and vein were ligated and divided. For automatic suture stapling, the pancreatic parenchyma was gently compressed for a few minutes at the

transection line with the jaws of the stapler. The pancreatic parenchyma was then amputated with the main pancreatic duct distal to the stapler using the automatic suture stapler.

In patients in whom mattress sutures were used, the pancreas proximal to the proposed transection line was clamped with intestinal forceps, and the distal pancreas was ligated to prevent unexpected bleeding. The pancreatic cut was made carefully with a scalpel and the main pancreatic duct was isolated from the pancreatic parenchyma. Following distal pancreatectomy, the main pancreatic duct was ligated. The cut edge of the proximal pancreas was then oversewn with interrupted mattress sutures using 4-0 absorbable monofilament only at bleeding points. The procedures used in the GWC group have been described in detail elsewhere (11, 12). Briefly, the proximal pancreas was detached approximately 3 cm from the retroperitoneum and the cut surface was fixed to the posterior wall of the gastric body. The fixation was accomplished by interrupted -suturing between the pancreatic parenchyma and the seromuscular layer of the stomach with 4-0 absorbable monofilament (Fig. 1A). As a consequence, the stump of the pancreas was completely covered by the stomach wall (Fig.

1B) .

### **Diagnostic criteria for pancreatic fistula**

Postoperative pancreatic fistulas were classified into three grades according to the definitions established by the International Study Group on Pancreatic Fistula (ISGPF) (13): Grade A, biochemical fistula without clinical sequelae; Grades B and C, signs of infection and clinical sequelae. In the present study, postoperative pancreatic fistula was defined as Grade B or C, with referred to ISGPF definition.

### **Statistical analysis**

Statistical analysis was carried out using either the  $\chi^2$  test or Fisher's test. Differences were considered significant at  $P < 0.05$ .

## **RESULTS**

There were no significant differences between the two groups in age, gender, distribution of disease or diabetes status prior to operation (Table 1). The overall incidence of postoperative pancreatic fistula following distal pancreatectomy was 24.5% (13/53 patients). There were no significant differences in operating time, intraoperative blood loss, or texture of the remnant stump between the two groups. Postoperative pancreatic fistulas were diagnosed in 1 patient (5.0%) in the GWC group and in 12 patients (36.4%) in the CS group; this difference was statistically significant ( $P = 0.01$ ; Table 2). The relationship between pancreatic texture and the incidence of postoperative pancreatic fistula is shown in Table 3. In the single GWC patient with pancreatic fistula, the remnant stump of the pancreas had a non-fibrotic texture. In the CS group, on the other hand, 11 of the 25 patients (44.0%) whose stump had a non-fibrotic texture suffered pancreatic fistula; of the 8 CS patients with a fibrotic texture, only 1 (12.5%) suffered pancreatic fistula. In the GWC group, none of the 20 patients showed delayed gastric emptying, gastric ulcer or intra-abdominal abscess within a mean observation



period of 14 months (range, 2-31 months). No patient with pancreatic fistula died in either group.

## **DISCUSSION**

Our concept of the present new surgical procedure for the prevention of pancreatic fistula is the management of the small branches of the pancreatic duct communicating with the main duct on the cut surface. In fact, Konishi et al. (8) report that the mean number of open small branches at the cut surface of the pancreas after distal pancreatectomy is 2.0, with a range from 0 to 5. Additionally, Kuroda et al. (14) report that histological examination of specimens harvested 30 days after pancreaticogastrointestinal anastomosis using a canine model revealed a good connective tissue union between the pancreas and the gastric wall. This finding suggests that the cut surface including the small pancreatic ducts is covered tightly by the covering stomach wall using our surgical procedure. It is, of course, essential to close the main pancreatic duct to a certain extent by gentle handling of the pancreatic stump.

Several studies have shown that the texture of the pancreatic parenchyma is one of the most important risk factors of postoperative pancreatic fistula (15-17). Hamanaka et al. (18) report that patients with pancreatic parenchyma of a normal

consistency produce more pancreatic juice and have a higher rate of pancreatic leakage. In addition, a non-fibrotic pancreas shows an easily crushed and soft pancreatic parenchyma. Another recent study found that patients with a soft pancreas have a higher incidence of pancreatic fistula after distal pancreatectomy than those with a fibrotic pancreas (44% vs. 5%;  $P=0.006$ ) (17). In the present study, the higher incidence of postoperative pancreatic fistula in the CS group may have resulted from the high incidence of pancreatic fistula with a non-fibrotic pancreas. In previous reports, the incidence of pancreatic fistula after distal pancreatectomy has been described as 13.6-34.1% (19-21). In the present GWC group, the frequency of pancreatic fistula was at a satisfactory level. However, it must be taken into consideration that a soft pancreas is a primary risk factor for postoperative pancreatic fistula.

In conclusion, it is obvious that there is need for improvement in the prevention of postoperative pancreatic fistula after distal pancreatectomy. Our gastric wall-covering method for the management of the pancreatic stump following distal pancreatectomy has been shown to reduce the incidence of

postoperative pancreatic fistula. Our technique is simple and safe, and can be combined with other surgical procedures, such as mattress sutures or fibrin glue sealing, to prevent pancreatic fistula after distal pancreatectomy. This procedure is expected to be useful in reducing morbidity and mortality after distal pancreatectomy.

**REFERENCES**

- 1 Lillemoe KD, Kaushal S, Cameron JL, Sohn TA, Pitt HA, Yeo CJ: Distal pancreatectomy: indications and outcomes in 235 patients. *Ann Surg* 1999; 229: 693-700.
- 2 Kuroki T, Tajima Y, Kanematsu T: Surgical management for the prevention of pancreatic fistula following distal pancreatectomy. *J Hepatobiliary Pancreat Surg* 2005; 12: 283-285.
- 3 Buchler MW, Wagner M, Schmied BM, Uhl W, Friess H, Z'graggen K: Changes in morbidity after pancreatic resection: toward the end of completion pancreatectomy. *Arch Surg* 2003; 138: 1310-1315.
- 4 Balcom JH 4th, Rattner DW, Warshaw AL, Chang Y, Fernandez-del Castillo C: Ten-year experience with 733 pancreatic resections: changing indications, older patients, and decreasing length of hospitalization. *Arch Surg* 2001; 136: 391-398.
- 5 Shankar S, Theis B, Russell RCG: Management of the stump of the pancreas after distal pancreatic resection. *Br J Surg* 1990; 77: 541-544.

- 6 Kajiyama Y, Tsurumaru M, Udagawa H Tsutsumi K, Kinoshita Y, Akiyama H: Quick and simple distal pancreatectomy using the GIA stapler: report of 35 cases. *Br J Surg* 1996; 83: 1711.
- 7 Misawa T, Shiba H, Usuba T, Nojiri T, Uwagawa T, Ishida Y, Ishii Y, Yanaga K: Safe and quick distal pancreatectomy using a staggered six-row stapler. *Am J Surg* 2008; 195: 115-118.
- 8 Konishi T, Hiraishi M, Kubota K, Bandai Y, Makuuchi M, Idezuki Y: Segmental occlusion of the pancreatic duct with prolamine to prevent fistula formation after distal pancreatectomy. *Ann Surg* 1995; 221: 165-170.
- 9 Suc B, Msika S, Fingerhut A, Fourtanier G, Hay JM, Holmieres F, Sastre B, Fagniez PL: Temporary fibrin glue occlusion of the main pancreatic duct in the prevention of intra-abdominal complications after pancreatic resection: prospective randomized trial. *Ann Surg* 2003; 237: 57-65.
- 10 Suzuki Y, Kuroda Y, Morita A, Fujino Y, Tanioka Y, Kawamura T, Saitoh Y: Fibrin glue sealing for the prevention of pancreatic fistulas following distal pancreatectomy. *Arch*

- Surg 1995; 130: 952-955.
- 11 Kuroki T, Tajima Y, Tsutsumi R, Mishima T, Kitazato A, Kanematsu T: Inferior branch preserving superior head resection of the pancreas with gastric wall-covering method for intraductal papillary mucinous adenoma. *Am J Surg* 2006; 191: 823-826.
- 12 Kuroki T, Tajima Y, Tsutsumi R, Tsuneoka N, Fukuda K, Haraguchi M, Furui J, Kanematsu T: Gastric wall-covering method for the prevention of pancreatic fistula after pancreatic resection. *Hepatogastroenterology* 2007; 54: 935-936.
- 13 Bassi C, Dervenis C, Butturini G, Fingerhut A, Yeo C, Izbicki J, Neoptolemos J, Sarr M, Traverso W, Buchler M: Postoperative pancreatic fistula: an international study group (ISGPF) definition. *Surgery* 2005; 138: 8-13.
- 14 Kuroda Y, Tanioka Y, Matsumoto S, Kim Y, Fujita H, Ajiki T, Suzuki Y, Ku Y, Saitoh Y: A new surgical technique for pancreaticogastrointestinal anastomosis without suturing the pancreatic parenchyma. *J Am Coll Surg* 1995; 181: 311-314.

- 15 Tajima Y, Kuroki T, Tsutsumi R, Fukuda K, Kitasato A, Adachi T, Mishima T, Kanematsu T: Risk factors for pancreatic anastomotic leakage: the significance of preoperative dynamic magnetic resonance imaging of the pancreas as a predictor of leakage. *J Am Coll Surg* 2006; 202: 723-731.
- 16 Fujino Y, Suzuki Y, Ajiki T, Tanioka Y, Ku Y, Kuroda Y: Risk factors influencing pancreatic leakage and the mortality after pancreaticoduodenectomy in a medium-volume hospital. *Hepatogastroenterology* 2002; 49: 1124-1129.
- 17 Ridolfini MP, Alfieri S, Gourgiotis S, Miceli DD, Rotondi F, Quero G, Manghi R, Doglietto GB: Risk factors associated with pancreatic fistula after distal pancreatectomy, which technique of pancreatic stump closure is more beneficial? *World J Gastroenterol* 2007; 13: 5096-5100.
- 18 Hamanaka Y, Nishida K, Hamasaki T, Kawabata A, Yamamoto S, Tsurumi M, Ueno T, Suzuki T: Pancreatic juice output after pancreaticoduodenectomy in relation to pancreatic consistency, duct size, and leakage. *Surgery* 1996; 119: 281-287.



- 19 Sierzega M, Niekowal B, Kulig J, Popiela T: Nutritional status affects the rate of pancreatic fistula after distal pancreatectomy: a multivariate analysis of 132 patients. *J Am Coll Surg* 2007; 205: 52-59.
- 20 Bilimoria MM, Cormier JN, Mun Y, Lee JE, Evans DB, Pisters PW: Pancreatic leak after left pancreatectomy is reduced following main pancreatic duct ligation. *Br J Surg* 2003; 90: 190-196.
- 21 Balzano G, Zerbi A, Cristallo M, Carlo VD: The unsolved problem of fistula after left pancreatectomy: the benefit of cautious drain management. *J Gastrointest Surg* 2005; 9: 837-842.

**FIGURE LEGEND**

**Fig. 1.** Gastric wall-covering method after distal pancreatectomy.

**A)** The fixation is accomplished by suturing between the pancreatic parenchyma around the pancreatic stump and the seromuscular layer of the stomach. **B)** After distal pancreatectomy, the cut surface is completely covered by the gastric wall.

Fig. 1A

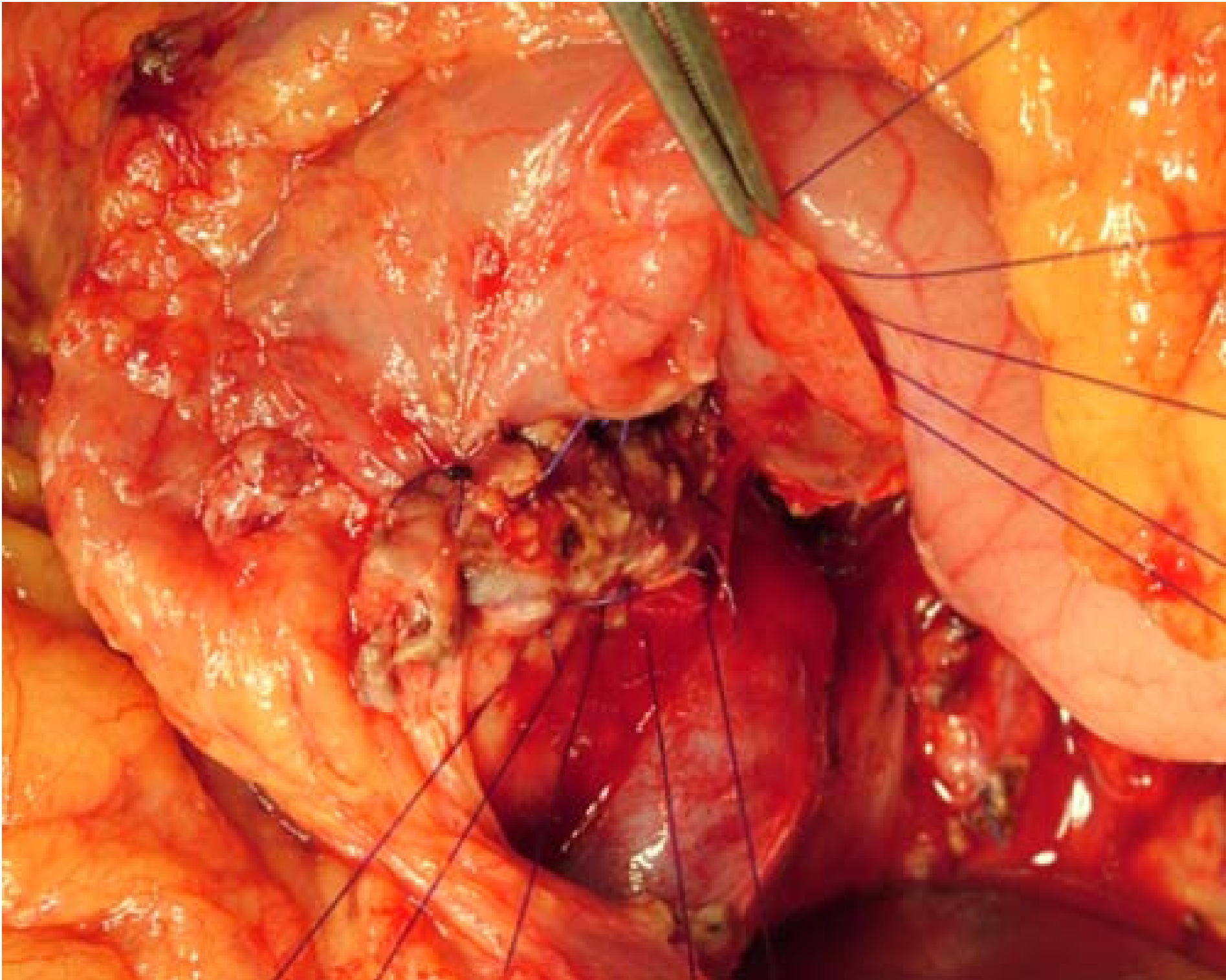


Fig. 1B

