

# Hepatitis B -Related Polyarteritis Nodosa Presenting Necrotizing Vasculitis in the Hepatobiliary System Successfully Treated with Lamivudine, Plasmapheresis and Glucocorticoid

Shigeyuki Takeshita<sup>1</sup>, Hideki Nakamura<sup>1</sup>, Atsushi Kawakami<sup>1</sup>, Tetsuya Fukushima<sup>1</sup>, Takashi Gotoh<sup>1</sup>, Tatsuki Ichikawa<sup>1</sup>, Akira Tsujino<sup>1</sup>, Hiroaki Ida<sup>1</sup>, Kan Toriyama<sup>2</sup>, Tomayoshi Hayashi<sup>3</sup> and Katsumi Eguchi<sup>1</sup>

---

## Abstract

---

A 64-year-old man was admitted for alithiasic cholecystitis. Necrotizing vasculitis was detected in a gallbladder obtained at the cholecystectomy. Slight elevation of transaminases, HBe antigens and hepatitis B-DNA (HBV-DNA) were detected in the patient. Intrahepatic necrotizing vasculitis was also detected in the liver biopsy specimen, and he also suffered from peripheral neuropathy of suddenly onset. Based on the diagnosis of hepatitis B-related polyarteritis nodosa, lamivudine was initially administered, followed by plasmapheresis and glucocorticoid steroid therapy. These treatments brought satisfactory improvement of polyarteritis nodosa without exacerbation of liver function.

**Key words:** Hepatitis B, polyarteritis nodosa, alithiasic cholecystitis, lamivudine, plasmapheresis, glucocorticoid therapy

(DOI: [10.2169/internalmedicine.45.1460](https://doi.org/10.2169/internalmedicine.45.1460))

---

## Introduction

---

Various extrahepatic manifestations of chronic hepatitis B infection have been reported (1-3). Polyarteritis nodosa (PAN) is the most typical extrahepatic manifestation. However, current estimates of hepatitis B-related PAN are now less than 10% among all PAN patients (4, 5). We encountered a case of hepatitis B-related PAN, diagnosed during the course of alithiasic cholecystitis. Necrotizing vasculitis was observed in the biopsy specimen of the gallbladder and liver, and mononeulitis multiplex was also complicated in the patient. The therapy of plasmapheresis and glucocorticoid with lamivudine exerted a significant effect without exacerbation of liver dysfunction.

---

## Case Report

---

A 64-year-old man, who had been previously treated for type 2 diabetes visited our hospital in March 2004 because of fever, elevation of C-reactive protein (CRP) and hepatobiliary enzymes. Diagnosis of alithiasic cholecystitis was made by abdominal ultrasonography and computed tomography (CT), however, antibiotics were not effective. Thus, laparoscopic cholecystectomy was performed and necrotizing vasculitis in the gall bladder was discovered after a pathological examination of the specimen taken at cholecystectomy, on May 18th. Since HBe antigen (Ag) as well as hepatitis B-DNA (HBV-DNA) was found in his serum (Table 1), we performed a liver biopsy, in which necrotizing vasculitis with fibrinoid degeneration of medial size arteries was demonstrated (Fig. 1). Although the liver parenchyma

---

<sup>1</sup> The First Department of Internal Medicine, Graduate School of Biomedical Sciences, Nagasaki University, Nagasaki, <sup>2</sup> Department of Pathology, Institute of Tropical Medicine, Nagasaki University, Nagasaki and <sup>3</sup> Department of Pathology, Nagasaki University Hospital, Nagasaki  
Received for publication June 13, 2005; Accepted for publication August 29, 2005

Reprint requests should be addressed to Hideki Nakamura, The First Department of Internal Medicine, Graduate School of Biomedical Sciences, Nagasaki University, 1-7-1 Sakamoto, Nagasaki 852-8501

was positively stained with anti-HBc antibody (DakoCytomation, Inc., Carpinteria, CA, USA) by the streptavidin-biotin (SAB) method, the vasculitis lesions of the gall bladder and liver were not positively stained for HBc antigen

**Table 1. Laboratory Findings Including HBV Markers and Viral Load.**

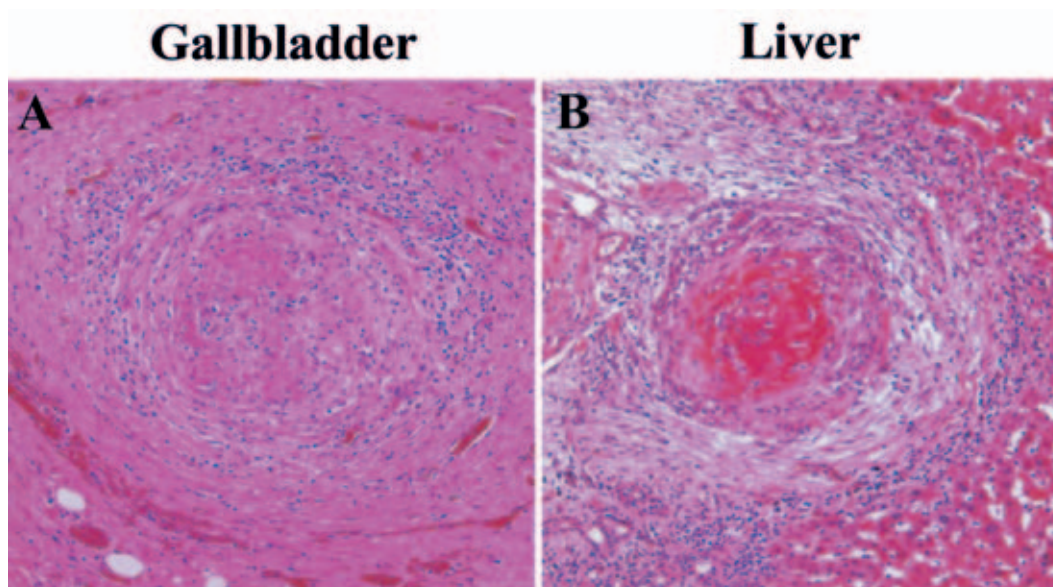
	On admission (May 18 2004)	On discharge (Sep. 14 2004)	Normal range	Unit
WBC	8800	7000	3500-9000	/ $\mu$ l
Hb	10.4	14.3	13.0-17.0	g/dl
Plt	$37.3 \times 10^4$	$16.1 \times 10^4$	$14 \times 10^4$ - $33 \times 10^4$	/ $\mu$ l
Total protein	6.5	6.0	6.7-8.3	g/dl
AST	35	18	13-33	IU/l
ALT	41	37	8-42	IU/l
$\gamma$ -GTP	112	58	10-47	IU/l
CRP	2.75	0.09	<0.17	mg/dl
HBsAg	>2000	NT	<1.0	COI
HBsAb	0.3	NT	<5.0	
HBeAg	+	+		
HBeAb	-	-		
HBV-DNA	7.8	4.5	<3.7	LGE/ml
Immune complex	1.3	NT	$\leq 2.9$	$\mu$ g/ml
MPO-ANCA	<10	<10	<20	EU
PR-3-ANCA	67	<10	<10	EU

Note NT; not tested, AST; aspartate aminotransferase, ALT; alanine aminotransferase, LGE; Log Genome Equivalent, MPO-ANCA; myeloperoxidase anti-neutrophil cytoplasmic antibody, PR3-ANCA; proteinase 3 anti-neutrophil cytoplasmic antibodies

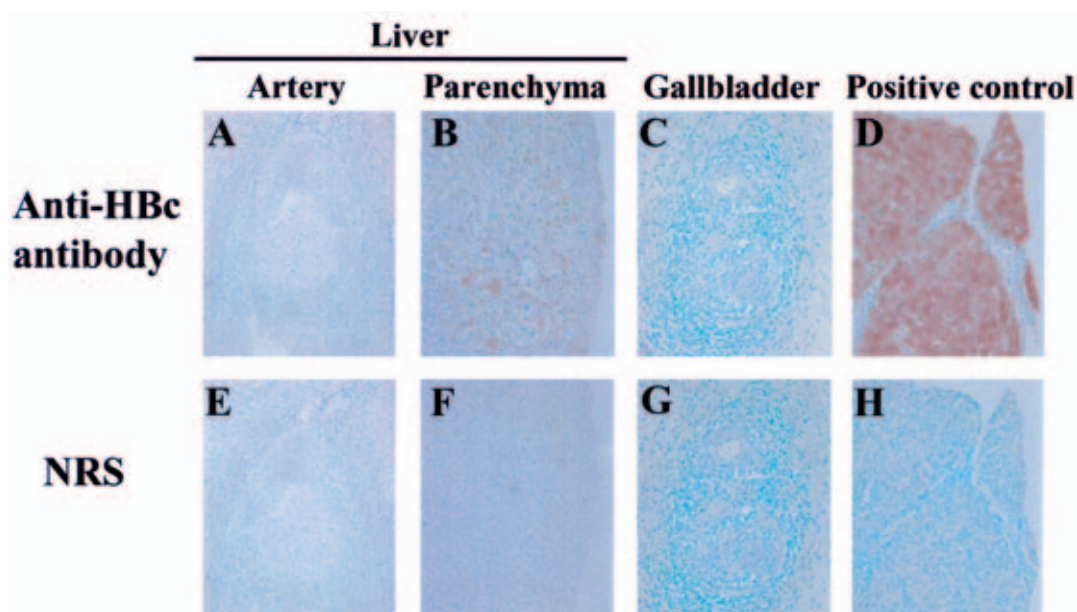
(Fig. 2). However, positive staining of complement 3 (C3) and IgG was observed in the inflamed vessels of the necrotizing lesion of both gallbladder and liver (Fig. 3) by the use of rabbit anti-human C3 antibody (DakoCytomation, Inc.) and MILAB ICC-kit IgG (MILAB, Arnhen, Netherlands) by the labeled streptavidin-biotin (LSAB) method.

On admission, the patient was febrile (37.5°C) and neurologically, he exhibited muscle weakness of the left lower leg. Numbness was also observed in both feet, more significant in the left foot, which was confirmed as mononeuritis multiplex by the nerve conduction velocity (NCV) study.

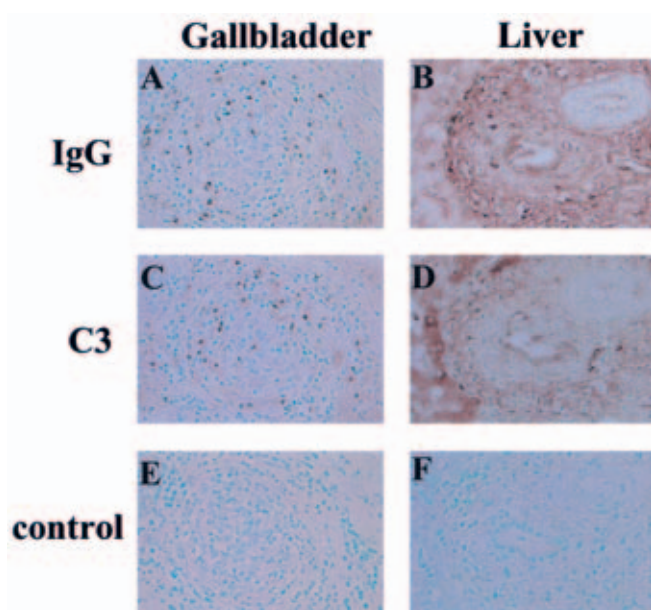
Laboratory findings on admission (Table 1) showed a hemoglobin level of 10.4 g/dl, total leukocyte count of 8,800/ $\text{mm}^3$ , and platelet count of  $37.3 \times 10^4/\text{mm}^3$ . Urinalysis was negative for both protein and occult blood. Blood chemistry showed normal BUN, creatinine, lactate dehydrogenase (LDH). There was a slight increase of serum transaminases (aspartate aminotransferase; AST 35 IU/l, alanine aminotransferase; ALT 41 IU/l) and  $\gamma$ -GTP (112 IU/l). Antinuclear antibody was negative. Furthermore, double-stranded anti-DNA antibody, anti-SS-A/SS-B antibody and myeloperoxidase anti-neutrophil cytoplasmic antibody (MPO-ANCA) were negative although the proteinase 3 antineutrophil cytoplasmic antibody (PR-3 ANCA) was slightly elevated at 67 EU. His serum CRP level was elevated at 2.75 mg/dl. As for HBV-associated markers, HBs antigens, HBe antigens, anti-IgM-HBc antibody and anti-HBc antibody were positively detected in the serum. Hepatitis B viremia was also found (Table 1). At this time HBV-YMDD mutation was not detected and HBV genotype was confirmed as type C. CT scan of the paranasal sinus and lung showed no evidence of Wegener's granulomatosis.



**Figure 1.** Necrotizing vasculitis was detected in both gallbladder and liver. Specimens were obtained from a liver biopsy and gall bladder sample taken during the cholecystectomy operation. In both the gallbladder and liver, necrotizing vasculitis with fibrinoid necrosis was observed in the inflamed medium-sized artery. Infiltration of neutrophils and granuloma formation were also observed. (Fig 1A and B). (HE stain,  $\times 100$ )



**Figure 2.** HBe antigen was not observed in the vasculitis lesion. Specimens obtained from the gallbladder and liver of the patient were immunostained with anti-HBe antibody. In the liver, positive staining was observed in the parenchyma (Fig 2B), however, there was no positive staining in the necrotizing lesion (Fig 2A). In the gallbladder, no positive staining was detected within the vasculitis lesion (Fig 2C). No positive staining was found in the negative control sections (Fig 2E-G). The positive control was the HBe antigen-positive patient with chronic hepatitis B (Fig 2D&H). NRS: normal rabbit serum ( $\times 100$ )



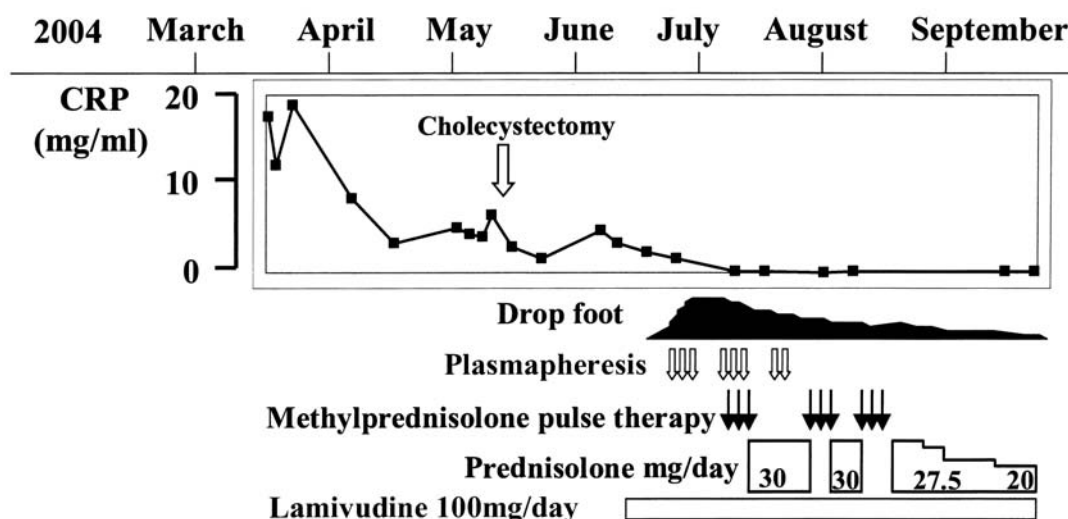
**Figure 3.** IgG and complement deposition was detected in the necrotizing vasculitis lesion. The specimens obtained from the gallbladder and liver of the patient were immunostained with antibodies against IgG and complement 3 (C3). Positive staining of IgG and C3 was observed in the inflamed vasculitis lesion of the gallbladder (Fig3 A&C). In the liver, strong IgG (Fig 3B) and slight C3 deposition (Fig 3D) were observed in the lesion of the necrotizing vasculitis, respectively. No positive staining was observed in the negative control sections (Fig 3E&F). ( $\times 100$ )

Since the diagnosis of hepatitis B-related PAN was made, we first administrated lamivudine on June 18. However, progression of peripheral neuropathy necessitated the addition of plasmapheresis (total 8 times during 3 weeks) glucocorticoid therapy including methylprednisolone pulse therapy (250 mg/day), followed by 30 mg of oral prednisolone, in accordance with insulin therapy for type 2 diabetes (Fig. 4). He was discharged on September 17 with a final prescription of 20 mg/day of oral prednisolone and lamivudine. As indicated in Fig. 4, these treatments brought improvement of neurological signs and inflammatory reactions without exacerbation of liver function. Hepatitis B viremia was also improved during the treatment (Table 1).

## Discussion

Immunohistochemically, HBe antigen was not observed in the inflamed vasculitis lesions. Previous reports suggest that circulating immune complex, consisting of hepatitis B antigens and antibodies plays an important role in the pathogenesis of vasculitic lesions of hepatitis B-related PAN (5). However, Dienstag (6) reported that circulating immune complexes does not appear to contribute to the pathogenesis of hepatitis B-related extrahepatic disorders. The present case did not show the elevation of circulating immune complex. Therefore, in the hepatitis B-related PAN of our case, either the direct effect of IgG or complement activation may play an important role in the pathogenesis of vasculitis lesions without the evidence of an immune complex-mediated





**Figure 4.** Clinical course of the patient. In March 2004, alithiasic cholecystitis occurred with elevation of CRP. Although laparoscopic cholecystectomy was performed, elevation of CRP was continuously observed. Lamivudine was initially administered, and repeated plasmapheresis followed by methylprednisolone pulse therapy improved both the inflammatory reactions and drop foot.

mechanism. It is possible to speculate that antibody-dependent cell-mediated cytotoxicity (ADCC) or complement-dependent cytotoxicity (CDC), triggered by HBV infection, might be involved in the pathologic process of the vascular damage in such a case.

Plasmapheresis is considered to be the pivotal therapy to improve hepatitis B-related PAN (7, 8). The apparent mechanism of plasmapheresis against hepatitis B-related PAN centers on the removal of viral components including circulating immune complex as well as blocking the replication and reactivation of HBV (9). In addition, some reports indicate that anti-viral agents such as interferon- $\alpha$ 2b, lamivudine or a combination of these compounds are effective for HBV-associated PAN (10). Recently, Guillevin *et al* reported the efficacy of short-term corticosteroids followed by lamivudine and plasma exchanges for hepatitis B-related

PAN (11). These observations strongly suggest the combination use of anti-inflammatory agents and anti-viral compounds for the treatment of hepatitis B-related PAN. In the present study, we successfully treated hepatitis B-related PAN with plasmapheresis and glucocorticoid by inhibiting HBV replication by lamivudine without exacerbation of liver dysfunction. Perhaps our treatment method will become an alternative in controlling the activity of hepatitis B-related PAN, especially in the case of HBe antigen-positive or high HBV viral load.

We thank Mr. Daniel Buckson for the critical reading and editing of our manuscript.

Shigeyuki Takeshita and Hideki Nakamura contributed equally to this work.

## References

- Han SH. Extrahepatic manifestations of chronic hepatitis B. *Clin Liver Dis* **8**: 403-418, 2004.
- Amarapurkar DN, Amarapurkar AD. Extrahepatic manifestations of viral hepatitis. *Ann Hepatol* **1**: 192-195, 2002.
- Chi ZC, Ma SZ. Rheumatologic manifestations of hepatic diseases. *Hepatobiliary Pancreat Dis Int* **2**: 32-37, 2003.
- Trepo C, Guillevin L. Polyarteritis nodosa and extrahepatic manifestations of HBV infection: the case against autoimmune intervention in pathogenesis. *J Autoimmun* **16**: 269-274, 2001.
- Janssen HL, van Zonneveld M, van Nunen AB, Niesters HG, Schalm SW, de Man RA. Polyarteritis nodosa associated with hepatitis B virus infection. The role of antiviral treatment and mutations in the hepatitis B virus genome. *Eur J Gastroenterol Hepatol* **16**: 801-807, 2004.
- Dienstag JL. Hepatitis B as an immune complex disease. *Semin Liver Dis* **1**: 45-57, 1981.
- Guillevin L. Treatment of polyarteritis nodosa and Churg-Strauss angiitis: indications of plasma exchange. Results of three prospective trials in 162 patients. The Cooperative Study Group for the Study of Polyarteritis Nodosa. *Prog Clin Biol Res* **337**: 309-317, 1990.
- Guillevin L, Lhote F. Treatment of polyarteritis nodosa and Churg-Strauss syndrome: indications of plasma exchanges. *Transfus Sci* **15**: 371-388, 1994.
- Deleaval P, Stadler P, Descombes E, et al. Life-threatening complications of hepatitis B virus-related polyarteritis nodosa developing despite interferon-alpha2b therapy: successful treatment with a combination of interferon, lamivudine, plasma exchanges and steroids. *Clin Rheumatol* **20**: 290-292, 2001.
- Erhardt A, Sagir A, Guillevin L, Neuen-Jacob E, Haussinger D. Successful treatment of hepatitis B virus associated polyarteritis nodosa with a combination of prednisolone, alpha-interferon and

- lamivudine. *J Hepatol* **33**: 677-683, 2000.
11. Guillevin L, Mahr A, Cohen P, et al. Short-term corticosteroids then lamivudine and plasma exchanges to treat hepatitis B virus-related polyarteritis nodosa. *Arthritis Rheum* **51**: 482-487, 2004.

---

© 2006 The Japanese Society of Internal Medicine  
<http://www.naika.or.jp/imindex.html>