

Acute thrombosis of everolimus-eluting platinum chromium stent caused by impaired prasugrel metabolism due to cytochrome P450 enzyme 2B6*2 (C64T) polymorphism: a case report

Yuki Yamagata, Seiji Koga *, Satoshi Ikeda , and Koji Maemura 

Department of Cardiovascular Medicine, Nagasaki University Graduate School of Biomedical Sciences, 1-7-1 Sakamoto, Nagasaki 852-8501, Japan

Received 1 November 2019; first decision 30 November 2019; accepted 30 April 2020; online publish-ahead-of-print 25 July 2020

Background

Dual antiplatelet therapy with aspirin and P2Y₁₂ receptor inhibitor is an important option for preventing acute stent thrombosis after percutaneous coronary intervention (PCI).

Case summary

A 72-year-old man was admitted to our hospital with ST-segment elevation myocardial infarction. Emergent coronary angiography identified the occlusion in the proximal left anterior descending artery. This lesion was successfully treated by thrombus aspiration and an everolimus-eluting platinum chromium stent implantation with loading of aspirin 200 mg and prasugrel 20 mg. However, acute closure of the stent occurred 1 h after PCI. P2Y₁₂ reaction units (PRU) measured using VerifyNow assay was 282, suggesting high platelet reactivity on prasugrel. After adding cilostazol 200 mg, recanalization was successfully obtained by thrombus aspiration and ballooning under intra-aortic balloon pump. Thereafter, PRU decreased to 266 at 4 h after PCI, and 49 the next day, implying full inhibition of platelet reactivity on prasugrel. Fortunately, no stent thrombosis has recurred since then. Genotype analysis of cytochrome P450 enzyme (CYP) demonstrated CYP2B6*1/*2 polymorphism leading to impaired metabolism of prasugrel. Based on these findings, acute stent thrombosis in the present case might have been caused by delayed expression of prasugrel effects due to CYP2B6*2 (C64T) polymorphism.

Discussion

In cases of stent thrombosis, we should consider the possibility of poor response to P2Y₁₂ receptor inhibitors due to CYP polymorphism. Assessment of platelet aggregation and CYP genotype may be warranted.

Keywords

Acute stent thrombosis • Prasugrel • Cytochrome P450 • High platelet reactivity • Case report

*Corresponding author. Tel: +81 95 819 7288, Fax: +81 95 819 7290, Email: kogase@nagasaki-u.ac.jp

Handling Editor: Mariama Akodad

Peer-reviewers: Alice Wood, Pierre Deharo, and Marco De Carlo

Compliance Editor: Christian Fielder Camm

© The Author(s) 2020. Published by Oxford University Press on behalf of the European Society of Cardiology.

This is an Open Access article distributed under the terms of the Creative Commons Attribution Non-Commercial License (<http://creativecommons.org/licenses/by-nc/4.0/>), which permits non-commercial re-use, distribution, and reproduction in any medium, provided the original work is properly cited. For commercial re-use, please contact journals.permissions@oup.com

Learning points

- Polymorphism of cytochrome P450 (CYP) gene is a key factor for poor metabolism of P2Y₁₂ receptor inhibitors, which can be related to high platelet reactivity and adverse cardiovascular events.
- CYP2B6*2 (C64T) is a rare genetic polymorphism. The association between this polymorphism and P2Y₁₂ receptor inhibitors has not been determined.
- In the present case, we showed that the patient's genotype of CYP2B6*1/*2 can be related to impaired prasugrel metabolism for the first time.

Introduction

Stent thrombosis is a serious complication leading to acute myocardial infarction and death. Dual antiplatelet therapy (DAPT) with aspirin and a P2Y₁₂ receptor inhibitor such as clopidogrel, prasugrel, or ticagrelor, is key to preventing this complication after implantation of a drug-eluting stent.¹ Although clopidogrel is the most widely used P2Y₁₂ inhibitor, clopidogrel resistance due to genetic variations in cytochrome P450 (CYP) 2C19 can lead to cardiovascular events.² Prasugrel was thus introduced as a P2Y₁₂ inhibitor with greater potency and quicker pharmacological effects than clopidogrel. Here, we report a case of acute stent thrombosis that might have been caused by delayed expression of the antiplatelet effects of prasugrel due to a very rare CYP2B6 polymorphism.

Timeline

Case presentation

A 72-year-old Japanese man was admitted to our hospital with ST-segment elevation myocardial infarction. He had a history of hypertension and was a current smoker. The electrocardiogram showed complete right bundle branch block (CRBBB) and ST-segment elevation in leads V1–V4 (Figure 1A). Transthoracic echocardiography showed a left ventricular ejection fraction (LVEF) of 30% with akinetic motion of the anteroseptal-apex wall (Supplementary material online, Video S1). Emergent coronary angiography (CAG) was performed 10 min after loading of DAPT with aspirin 200 mg and prasugrel 20 mg, revealing subtotal occlusion in the proximal left anterior descending artery (LAD) (Figure 2A, Supplementary material online, Video S2). Recanalization with coronary flow of Thrombolysis In Myocardial Infarction (TIMI) Grade 3 was successfully obtained without any complications by thrombectomy and implantation of an everolimus-eluting platinum chromium stent (Synergy, 4.0 × 24 mm; Boston Scientific, Natick, MA, USA) (Figure 2B, Supplementary

Time	Events
Day 1	
1 h before admission	First episode of chest pain.
Hospital admission	Electrocardiogram shows ST-segment elevation in anterolateral leads. Ventricular fibrillation occurs and is treated with cardioversion.
20 min after admission	Loading of aspirin 200 mg and prasugrel 20 mg.
30 min after admission	Emergent coronary angiography (CAG) reveals subtotal occlusion in the proximal left anterior descending (LAD) artery. Everolimus-eluting platinum chromium stent is implanted.
1 h after percutaneous coronary intervention (PCI)	Episode of recurrent chest pain. Electrocardiogram shows new ST-segment elevation in anterolateral leads. Emergent CAG reveals thrombotic re-occlusion in proximal LAD. VerifyNow [®] system reveals 282 P2Y ₁₂ reaction units (PRU). After adding cilostazol 200 mg, balloon dilatation and thrombectomy are performed.
4 h after re-PCI	266 PRU.
Day 2	49 PRU.
Day 24	Discharged on triple antiplatelets.
3-month follow-up	Asymptomatic. Coronary angiography shows no stent restenosis. 209 PRU. Cilostazol is stopped.
2 weeks after stopping cilostazol	179 PRU.
2-year follow-up	No recurrence of thrombotic events.

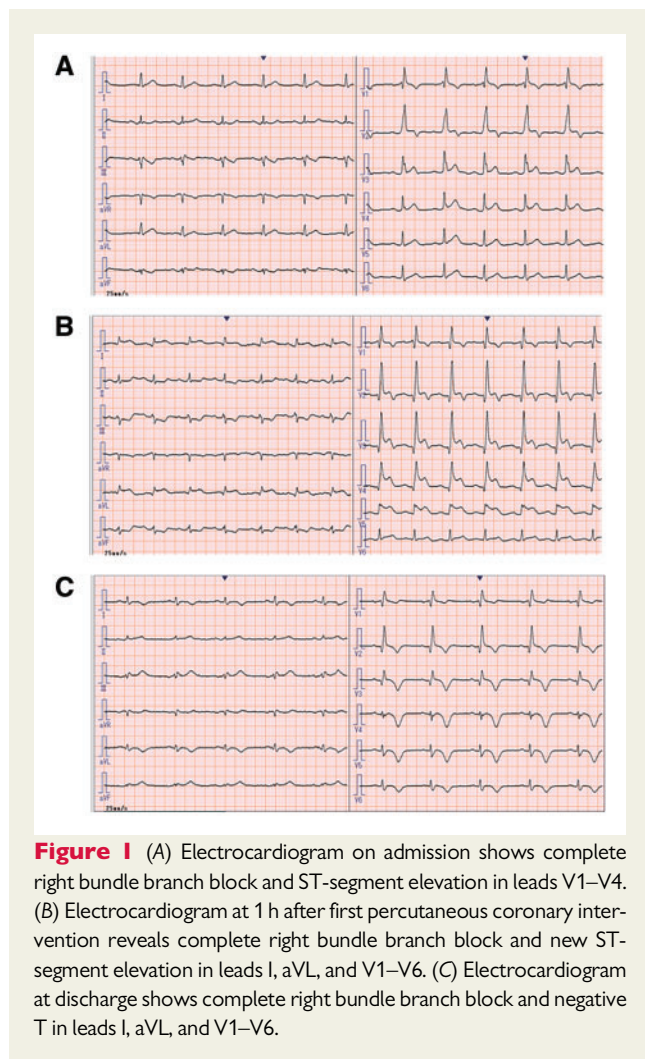


Figure 1 (A) Electrocardiogram on admission shows complete right bundle branch block and ST-segment elevation in leads V1–V4. (B) Electrocardiogram at 1 h after first percutaneous coronary intervention reveals complete right bundle branch block and new ST-segment elevation in leads I, aVL, and V1–V6. (C) Electrocardiogram at discharge shows complete right bundle branch block and negative T in leads I, aVL, and V1–V6.

material online, Video S3). Intravascular ultrasound (IVUS) after percutaneous coronary intervention (PCI) confirmed good stent apposition with slight tissue protrusion in the stent (Figure 2C–E).

One hour later, the patient developed sudden-onset severe chest pain. The electrocardiogram revealed new ST-segment elevation in leads I, aVL, and V1–V6 (Figure 1B). Emergent CAG revealed thrombotic re-occlusion of a stent in the proximal LAD, which was diagnosed as acute stent thrombosis (Figure 3A, Supplementary material online, Video S4). Platelet reactivities on aspirin and prasugrel were evaluated by the VerifyNow system (Accumetrics, San Diego, CA, USA) before PCI. This demonstrated 438 aspirin reaction units (ARU) (target range for sufficient platelet inhibition, <550 ARU³) and 282 P2Y12 reaction units (PRU) (target range for sufficient platelet inhibition, <230 PRU⁴), implying high platelet reactivity on prasugrel. Because prasugrel resistance was suspected, cilostazol 200 mg was added just before PCI. We used an intra-aortic balloon pump (IABP) because of cardiogenic shock (blood pressure, 83/56 mmHg) and low LVEF. After recanalization by thrombectomy, optical coherence tomography (OCT) was performed (Figure 3B). Optical coherence tomography revealed massive thrombi without stent malapposition or edge dissection (Figure 3C–E). Since balloon dilatation resulted in TIMI flow Grade 3 with only a small amount of thrombus, we did not

need additional stent implantation (Supplementary material online, Video S5). Thereafter, platelet reactivity decreased to 266 PRU at 4 h after PCI and 49 PRU at 1 day after PCI, implying delayed expression of prasugrel effects. At 2 days after PCI, CAG showed little thrombus in the stent and the IABP was removed. After 24 days of hospitalization, the patient was discharged without any cardiac events under aspirin (100 mg/day), prasugrel (3.75 mg/day), and cilostazol (200 mg/day). Electrocardiogram at discharge showed CRBBB and negative T in leads I, aVL, and V1–V6 (Figure 1C). Transthoracic echocardiography at discharge showed LVEF had improved to 50% with mild hypokinetic motion of the anteroseptal-apex wall (Supplementary material online, Video S6).

At 3 months after discharge, follow-up CAG showed no in-stent restenosis and OCT revealed almost full neointimal coverage of stent struts without thrombi. Since the antiplatelet effect of prasugrel was sufficient with platelet reactivity of 209 PRU, we stopped cilostazol and continued aspirin 100 mg/day and prasugrel 3.75 mg/day. At 2 weeks after stopping cilostazol, adequate inhibition of platelet reactivity on prasugrel was maintained with 179 PRU. As of the 2-year follow-up, no thrombotic events had recurred. Genotype analysis for CYP involved in the prasugrel metabolic pathway demonstrated CYP2B6*1/*2 polymorphism (Table 1).

Discussion

We presented a case of acute stent thrombosis possibly caused by delayed expression of the antiplatelet effect of prasugrel due to CYP2B6*2 (C64T) polymorphism.

Dual antiplatelet therapy with aspirin and P2Y12 blocker is the standard treatment for patients undergoing coronary stent implantation. Clopidogrel is a widely used P2Y12 blocker but shows wide interindividual variation in its antiplatelet effects. Such pharmacodynamic variability of clopidogrel between individuals is caused mainly by genetic variations in CYP2C19.⁵ In particular, CYP2C19*2 and/or *3 loss-of-function alleles, representing the main causes of poor-metabolizer status for patients on clopidogrel, are more frequent in Japanese populations than in European-Caucasians populations.⁵

Prasugrel is a next-generation P2Y12 receptor blocker providing quicker, more intensive, and more consistent platelet inhibition than clopidogrel. Because prasugrel is predominantly metabolized to its active form by CYP3A4 and CYP2B6, the antiplatelet effects are not influenced by CYP2C19 polymorphisms.⁶ In the PRASFIT-ACS study, the antiplatelet effect of prasugrel was sufficient in the acute phase, 2–4 h after PCI, compared to clopidogrel and irrespective of CYP2C19 status.⁷ In the present case, adequate antiplatelet effect of prasugrel was not obtained even 6 h after the initial loading dose of 20 mg. Sufficient antiplatelet effects were observed the next day, implying delayed expression of prasugrel effect. Compared to clopidogrel resistance, prasugrel resistance is less frequent, with a reported frequency of 0–11.5%.⁸ One possible cause of prasugrel resistance is CYP single-nucleotide polymorphisms, including CYP2B6. Recently, the influence of CYP2B6 polymorphisms on prasugrel metabolism has been reported. Franken *et al.*⁹ showed that CYP2B6*6 (G516T and A785G) polymorphisms were associated with low response to prasugrel. Fiore *et al.*¹⁰ reported a case of subacute stent thrombosis in a patient with prasugrel resistance due to CYP2B6*6.

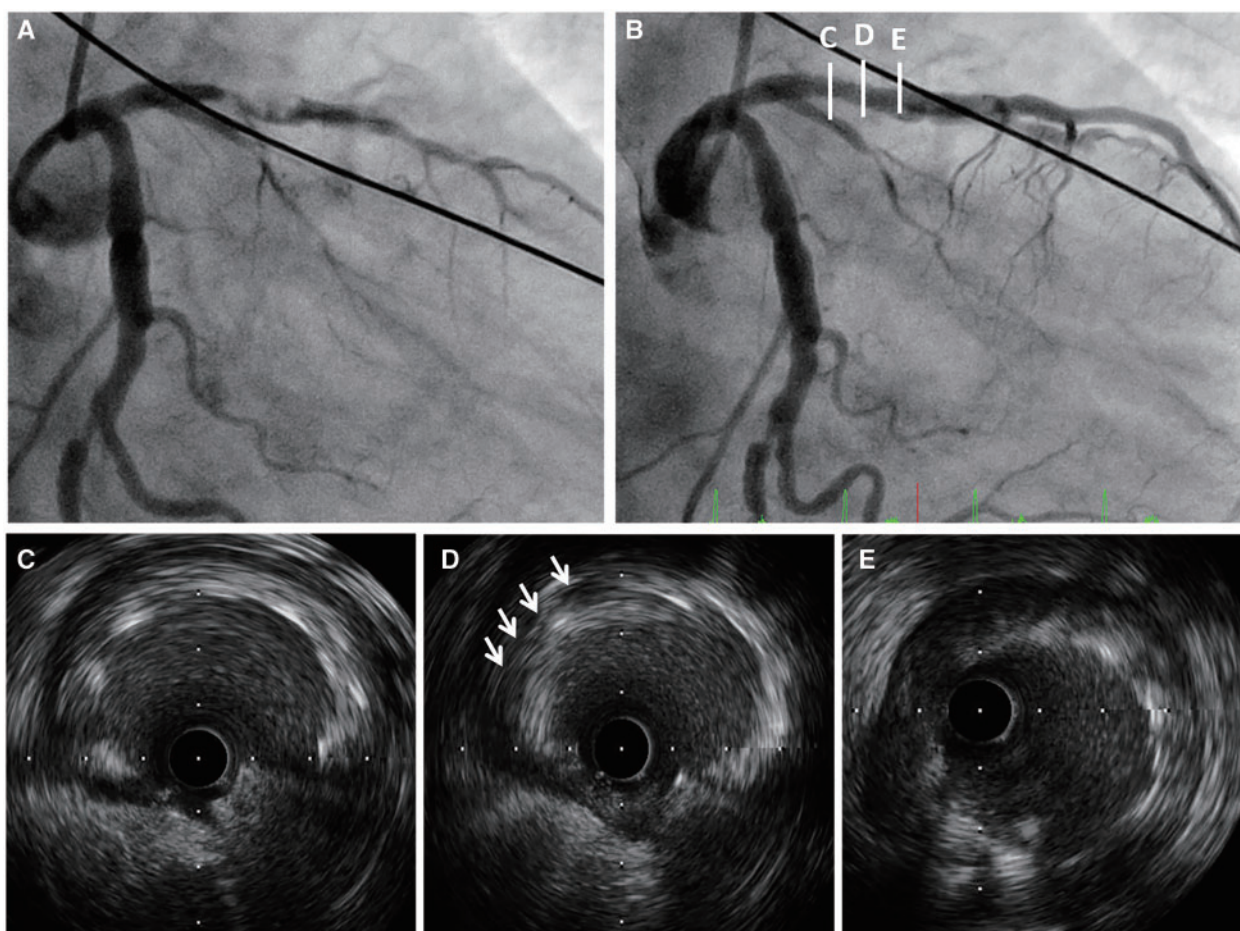


Figure 2 Coronary angiography and intravascular ultrasonography images before (A) and after (B–E) implantation of an everolimus-eluting platinum chromium stent. Intravascular ultrasonography demonstrates good apposition and stent expansion to the vessel wall. Only slight thrombi persist inside the stent (D, white arrows).

Inhibition of CYP2B6 function can thus affect the metabolism and effects of prasugrel. In the present case, the genotyping of CYP genes showed that the patient carried a genetic polymorphism of CYP2B6*1/*2, but not CYP2B6*6. Because CYP2B6*2 is a rare allele, no data describing the antiplatelet effects of prasugrel in patients carrying CYP2B6*2 polymorphism have been reported. Previous studies have shown the influence of variant alleles in CYP2B6 genes on response and toxicity under antiretroviral drugs and anticancer drugs. Usami et al.¹¹ reported that CYP2B6*2/*2 was related to the increased plasma concentration of the HIV non-nucleoside reverse transcriptase inhibitor efavirenz and the higher incidence of adverse central nervous system symptoms. Bray et al.¹² reported that variant allele CYP2B6*2 was associated with a higher incidence of dose delays with doxorubicin and cyclophosphamide, leading to higher toxicity in patients with breast cancer. These results suggest that the CYP2B6*2 allele has reduced metabolic function. The CYP2B6*2 allele with decreased function might thus cause delays in expression of the effects of prasugrel in the present patient. Taken together, CYP2B6*1/*2 possibly results in 'decreased function' rather than 'non-function' for metabolism of prasugrel. Although further

investigation is needed, the CYP2B6*2 polymorphism should be taken into account when patients appear resistant to prasugrel.

Japanese doses of prasugrel (20 mg for loading/3.75 mg for maintenance) are substantially lower than the recommended doses in Europe and the USA (60 mg for loading/10 mg for maintenance) (Table 2). The incidence of ischaemic events in East-Asian populations is similar to or lower than that in Western population, whereas East-Asian groups including Japanese display a higher risk of bleeding.¹³ As a result, the approved drugs and their doses/indications and clinical trial results differ between Japan and Western countries. In Western populations, prasugrel was associated with significantly reduced rates of ischaemic events, but with an increased risk of major bleeding at 15 months among patients with acute coronary syndrome (ACS) in the TRITON-TIMI 38 study.¹⁴ The PRASFIT-ACS study was therefore conducted to clarify the efficacy and safety of an adjusted dose of prasugrel (20 mg for loading/3.75 mg for maintenance) in Japanese ACS patients.¹⁵ In this study, an adjusted dose of prasugrel was associated with a tendency towards a lower frequency of major adverse cardiovascular events compared with clopidogrel (300 mg for loading/75 mg for maintenance) at 24 weeks (prasugrel 9.4% vs.

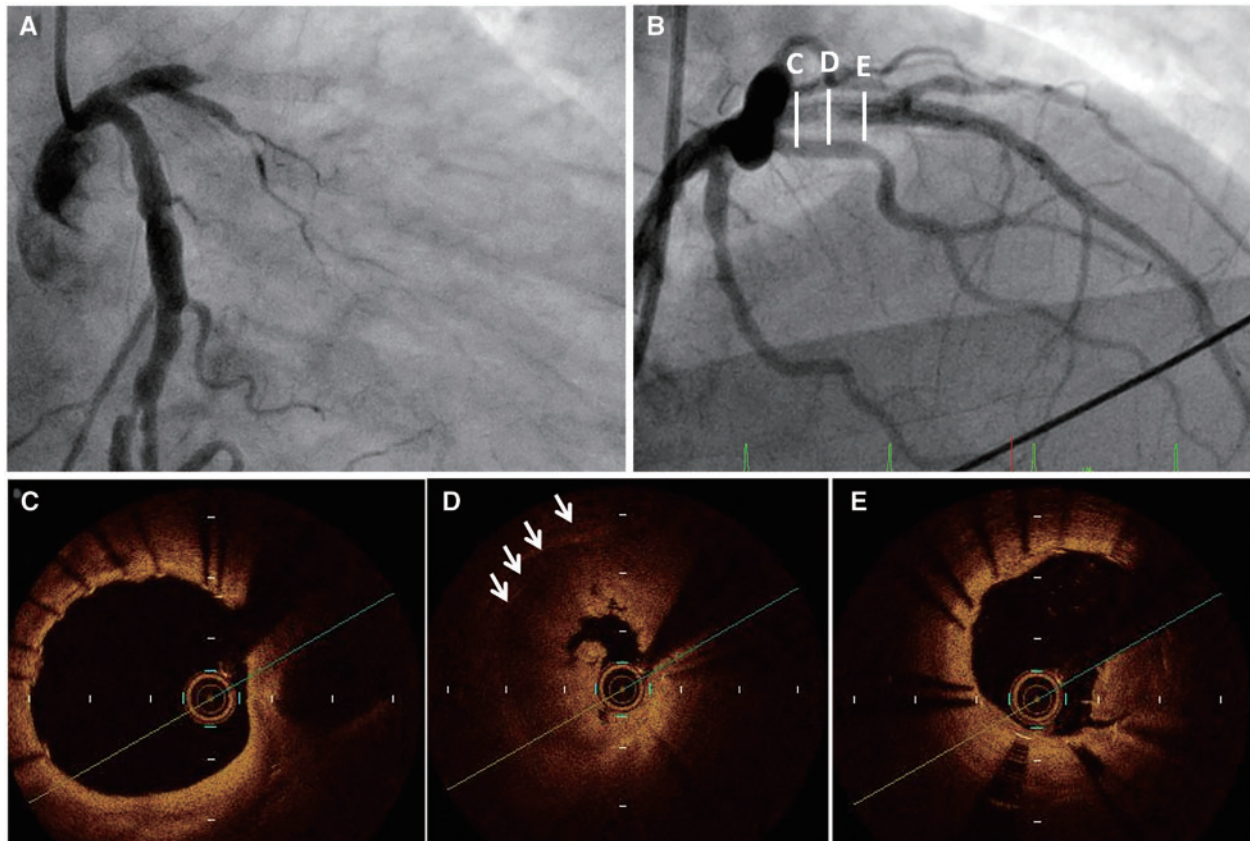


Figure 3 Coronary angiography and optical coherence tomography images in acute stent thrombosis before (A) and after aspiration thrombectomy (B–E). Optical coherence tomography demonstrates good apposition, stent expansion, and no stent edge dissection. Massive stent thrombi are apparent (D, white arrows).

Table 1 CYP genotype analysis

CYP-polymorphism	
CYP2B6 genotype	*1/*2
CYP2C9 genotype	*1/*1
CYP2C19 genotype	*1/*1

CYP, cytochrome P450.

clopidogrel 11.8%) without any increase in the incidence of major bleeding (prasugrel 1.9% vs. clopidogrel 2.2%). As a result, an adjusted dose of prasugrel (20 mg for loading/3.75 mg for maintenance) was approved in 2014 in Japan. We therefore do not think that the adjustment of prasugrel dose in Japanese ACS patients caused the lack of efficacy of prasugrel. In contrast, prasugrel at 3.75 mg/day did not show non-inferiority to clopidogrel at 75 mg/day in the prevention of ischaemic stroke, myocardial infarction, and death from other vascular causes in Japanese patients with non-cardioembolic stroke.¹⁶ Further studies are needed to confirm the efficacy and safety of adjusted doses of prasugrel for Japanese ACS patients.

In cases of prasugrel resistance, switching to ticagrelor, a novel P2Y₁₂ receptor inhibitor, is recommended.¹⁷ In the present case, the best antithrombotic strategy is likely switching from prasugrel to ticagrelor. However, ticagrelor was unavailable for clinical use in Japan when we encountered the present case. In addition, we cannot use cangrelor, which is considered for P2Y₁₂-inhibitor-naïve patients undergoing PCI.¹⁷ Cangrelor is also an effective option to warrant platelet inhibition while oral P2Y₁₂ inhibitors are still not effective. Alternatively, we added cilostazol on DAPT (aspirin and prasugrel). Several studies have demonstrated that addition of cilostazol to DAPT (aspirin and clopidogrel) resulted in greater platelet inhibition compared with DAPT.^{18,19} In line with these findings, we added cilostazol to aspirin and prasugrel. On the other hand, triple antiplatelet therapy can carry a risk of bleeding events. Recent studies in East-Asian populations, including Japanese populations, with ACS have shown no difference in the frequencies of clinically serious bleeding and adverse events between cilostazol plus DAPT and DAPT alone.^{18,19} Further study is needed to elucidate the influence of cilostazol on bleeding risk.

Some differences in not only doses of antithrombotic drugs but also interventional treatments and mechanical devices used in ACS

Table 2 Major differences in antithrombotic/interventional treatments and mechanical devices between Western countries and Japan in ACS

	Western countries	Japan
PCI		
Radial access use	Relatively low	Relatively high
IVUS/OCT use in PCI	Less prevalent	Predominant
Glycoprotein IIb/IIIa inhibitors	Available	Not available
Aspirin	Loading dose of 150–300 mg Maintenance dose of 75–100 mg/day	Loading dose of 162–200 mg Maintenance dose of 81–162 mg/day
P2Y12 inhibitors		
Clopidogrel	Loading dose of 600 mg Maintenance dose of 75 mg/day	Loading dose of 300 mg Maintenance dose of 75 mg/day
Prasugrel	Loading dose of 60 mg Maintenance dose of 10 mg/day	Loading dose of 20 mg Maintenance dose of 3.75 mg/day
Ticagrelor	Loading dose of 180 mg Maintenance dose of 90 mg twice daily	Same as in Western countries
Basic indication of ticagrelor	Acute coronary syndrome	Intolerance of clopidogrel and prasugrel
Cilostazol	Not available/recommended	Considered in intolerance of clopidogrel and prasugrel
Mechanical left ventricular assist devices	Intra-cardiac axial flow pump (i.e. Impella) and intra-aortic balloon pump are available	Intra-aortic balloon pump is used. Intra-cardiac axial flow pump (i.e. Impella) is not widely available but used in limited institutions

ACS, acute coronary syndrome; IVUS, intravascular ultrasonography; OCT, optical coherence tomography; PCI, percutaneous coronary intervention.

exist between Japan and Western countries (Table 2). With regard to intravascular imaging, IVUS and OCT during PCI are routinely reimbursed in Japan. In cases of stent thrombosis, the IVUS and/or OCT should be considered to identify and correct underlying mechanical problems.¹⁷ We therefore used OCT and IVUS during PCI. On the other hand, routine use of IABP in patients with cardiogenic shock complicating ACS is not recommended.¹⁷ In the Japanese guidelines, use of IABP is considered for patients with ACS complicated by refractory cardiogenic shock or prolonged myocardial ischaemia after revascularization.²⁰ In addition, intra-cardiac axial flow pumps (e.g., Impella) are not available in most institutions in Japan. We used IABP because of cardiogenic shock with prolonged myocardial ischaemia due to acute stent thrombosis after primary PCI for ACS.

In the present case, platelet aggregation was assessed only using the VerifyNow system. Although light transmittance aggregometry using adenosine diphosphate and vasodilator-stimulated phosphoprotein assay represent widely used and reliable platelet aggregation tests, we do not have access to these options in our institution.

Conclusion

This case demonstrated that the rare genetic polymorphism CYP2B6*1/*2 may lead to impaired prasugrel metabolism. In the present case, this mutation was one possible contributor to acute stent thrombosis after implantation of a drug-eluting stent under loading of aspirin and prasugrel.

Lead author biography



Yuki Yamagata is a graduate of the Nagasaki University School of Medicine in 2004. Currently, he is a coronary interventionist, and Assistant Professor in Department of Cardiovascular Medicine, Nagasaki University Graduate School of Biomedical Sciences, Japan.

Supplementary material

Supplementary material is available at *European Heart Journal - Case Reports* online.

Acknowledgements

We wish to thank Hiroaki Kawano for interpretation of data and Saori Usui for assistance with data and sample collection.

Slide sets: A fully edited slide set detailing this case and suitable for local presentation is available online as [Supplementary data](#).

Consent: The authors confirm that written consent for submission and publication of this case report including images and associated text has been obtained from the patient in line with COPE guidance.

Conflict of interest: none declared.

References

1. Finn AV, Joner M, Nakazawa G, Kolodgie F, Newell J, John MC et al. Pathological correlates of late drug-eluting stent thrombosis: strut coverage as a marker of endothelialization. *Circulation* 2007;**115**:2435–2441.
2. Brar SS, ten Berg J, Marcucci R, Price MJ, Valgimigli M, Kim HS et al. Impact of platelet reactivity on clinical outcomes after percutaneous coronary intervention. A collaborative meta-analysis of individual participant data. *J Am Coll Cardiol* 2011;**58**:1945–1954.
3. Chen WH, Lee PY, Ng W, Tse HF, Lau CP. Aspirin resistance is associated with a high incidence of myonecrosis after non-urgent percutaneous coronary intervention despite clopidogrel pretreatment. *J Am Coll Cardiol* 2004;**43**:1122–1126.
4. Price MJ, Berger PB, Teirstein PS, Tanguay JF, Angiolillo DJ, Spriggs D et al. GRAVITAS Investigators. Standard- vs high-dose clopidogrel based on platelet function testing after percutaneous coronary intervention: the GRAVITAS randomized trial. *JAMA* 2011;**16**:1097–1105.
5. Yamamoto K, Hokimoto S, Chitose T, Morita K, Ono T, Kaikita K et al. Impact of CYP2C19 polymorphism on residual platelet reactivity in patients with coronary heart disease during antiplatelet therapy. *J Cardiol* 2011;**57**:194–201.
6. Rehmel JL, Eckstein JA, Farid NA, Heim JB, Kasper SC, Kurihara A et al. Interactions of two major metabolites of prasugrel, a thienopyridine antiplatelet agent, with the cytochromes P450. *Drug Metab Dispos* 2006;**34**:600–607.
7. Nakamura M, Isshiki T, Kimura T, Ogawa H, Yokoi H, Nanto S et al. Optimal cut-off value of P2Y12 reaction units to prevent major adverse cardiovascular events in the acute periprocedural period: post-hoc analysis of the randomized PRASFIT-ACS study. *Int J Cardiol* 2015;**182**:541–548.
8. Alexopoulos D, Xanthopoulou I, Davlouros P, Plakomyti TE, Panagiotou A, Mavronasiou E et al. Prasugrel overcomes high on-clopidogrel platelet reactivity in chronic coronary artery disease patients more effectively than high dose (150 mg) clopidogrel. *Am Heart J* 2011;**162**:733–739.
9. Franken CC, Kaiser AF, Krüger JC, Overbeck K, Mügge A, Neubauer H. Cytochrome P450 2B6 and 2C9 genotype polymorphism—a possible cause of prasugrel low responsiveness. *Thromb Haemost* 2013;**110**:131–140.
10. Fiore M, Horovitz A, Pons AC, Leroux L, Casassus F. First report of a subacute stent thrombosis in a prasugrel resistant patient successfully managed with ticagrelor. *Platelets* 2014;**25**:636–638.
11. Usami O, Ashino Y, Komaki M, Irokawa T, Tamada T et al. Efavirenz-induced neurological symptoms in rare homozygote CYP2B6 *2/*2 (C64T). *Int J STD AIDS* 2007;**18**:575–576.
12. Bray J, Sludden J, Griffin MJ, Cole M, Verrill M, Jamieson D et al. Influence of pharmacogenetics on response and toxicity in breast cancer patients treated with doxorubicin and cyclophosphamide. *Br J Cancer* 2010;**102**:1003–1009.
13. Levine GN, Jeong YH, Goto S, Anderson JL, Huo Y, Mega JL et al. Expert consensus document: World Heart Federation expert consensus statement on antiplatelet therapy in East Asian patients with ACS or undergoing PCI. *Nat Rev Cardiol* 2014;**11**:597–606.
14. Wiviott SD, Braunwald E, McCabe CH, Montalescot G, Ruzyllo W, Gottlieb S et al. Prasugrel versus clopidogrel in patients with acute coronary syndromes. *N Engl J Med* 2007;**357**:2001–2015.
15. Saito S, Isshiki T, Kimura T, Ogawa H, Yokoi H, Nanto S et al. Efficacy and safety of adjusted-dose prasugrel compared with clopidogrel in Japanese patients with acute coronary syndrome: the PRASFIT-ACS study. *Circ J* 2014;**78**:1684–1692.
16. Ogawa A, Toyoda K, Kitagawa K, Kitazono T, Nagao T, Yamagami H et al.; Prastro-I Study Group. Comparison of prasugrel and clopidogrel in patients with non-cardioembolic ischaemic stroke: a phase 3, randomised, non-inferiority trial (PRASTRO-I). *Lancet Neurol* 2019;**18**:238–247.
17. Neumann F-J, Sousa-Uva M, Ahlsson A, Alfonso F, Banning AP, Benedetto U et al.; ESC Scientific Document Group. 2018 ESC/EACTS Guidelines on myocardial revascularization. *Eur Heart J* 2019;**40**:87–165.
18. Lee K, Yoo S-Y, Suh J, Park KH, Park Y, Tantry US et al. Efficacy of cilostazol on inhibition of platelet aggregation, inflammation and myonecrosis in acute coronary syndrome patients undergoing percutaneous coronary intervention: The ACCEL-LOADING-ACS (ACCElerrated Inhibition of Platelet Aggregation, Inflammation and Myonecrosis by Adjunctive Cilostazol Loading in Patients With Acute Coronary Syndrome) study. *Int J Cardiol* 2015;**190**:370–375.
19. Kaikita K, Yoshimura H, Ishii M, Kudoh T, Yamada Y, Yamamoto E et al.; for the CALDERA-GENE Investigators. Tailored adjunctive cilostazol therapy based on CYP2C19 genotyping in patients with acute myocardial infarction—the CALDERA-GENE study. *Circ J* 2018;**82**:1517–1525.
20. JCS 2018 Guideline on Guideline on Diagnosis and Treatment of Acute Coronary Syndrome. <https://doi.org/10.1253/circj.CJ-19-0133> (25 May 2020).