

Subjective visual vertical test in patients with chronic dizziness without abnormal findings in routine vestibular function tests

HIDETAKA KUMAGAMI, YUZURU SAINO, AKIKO BABA, DAISUKE FUJIYAMA,
KENJI TAKASAKI & HARUO TAKAHASHI

Department of Otolaryngology - Head and Neck Surgery, Nagasaki University Graduate
School of Biomedical Sciences,
Nagasaki, Japan

Correspondence: Hidetaka Kumagami MD, Department of Otolaryngology, Nagasaki
University, Sakamoto 1-7-1, Nagasaki 852-8501, Japan. Tel: +81 95
819 7349. Fax: +81 95 819 7352. E-mail: kumagami@nagasaki-u.ac.jp

Abstract

Conclusion: The subjective visual vertical (SVV) test can detect abnormality of the otolithic organs and the graviceptive pathways present in a considerable number of patients having dizziness but presenting no abnormal findings in conventional vestibular function tests. **Objective:** To evaluate whether the SVV test can detect dysfunction of the otolithic organs and perception of gravity in patients with dizziness having no abnormal finding on routine tests for the vestibular system. **Patients and methods:** Forty-four patients who complained of chronic dizziness but had no abnormal finding on routine tests for vestibular system and on brain MRI studies were selected between 2004 and 2006. SVV tests were performed on these patients. Patients with chronic dizziness caused by apparent psychogenic disorders, such as depression, were excluded. **Results:** Among the 44 patients, 3 showed abnormal tilts of SVV. The latter three patients had deep white matter hyperintensities on their MRI, probably due to aging. **Keywords:** Subjective visual vertical, SVV, dizziness, no abnormal finding, otolithic dysfunction, graviceptive pathway

Introduction

In the diagnosis of patients complaining of dizziness, observation of nystagmus with videonystagmoscope, electronystagmography, caloric testing, and rotator chair testing are widely used as routine tests. Patients suffering from dizziness but indicating no abnormal findings on routine tests such as those mentioned above may generally be diagnosed as having dizziness of unknown origin or psychogenic dizziness. However,

the above-mentioned tests are limited in that they mostly evaluate the function of the semicircular canal and, therefore, the possibility that such patients have disturbance in the otolithic organs and the graviceptive system cannot be excluded. The subjective visual vertical (SVV) is a highly reliable test for examining function of the otolithic organs and the graviceptive pathways [1,2]. SVV tends to indicate abnormal tilts to the affected side at the acute stages in peripheral disorders [3,4], and various abnormal tilts of SVV are observed in central disorders such as Wallenberg's syndrome [5]. However, SVV is not frequently used as a routine clinical test and, to date, there has been no study on SVV in patients who complain of dizziness but have no abnormal findings in routine clinical tests of the vestibular system. The aim of this study was to investigate whether SVV tests could detect dysfunction of the otolithic organs and perception of gravity in patients with dizziness who have no abnormal finding on routine tests for the vestibular system.

Patients and methods

Patients

Forty-four patients who met the following criteria were selected between 2004 and 2006. They consisted of 18 men and 26 women, ranging in age from 21 to 81 years, with an average age of 48.4. Patients who met all of the following criteria were enrolled: 1) patients complaining of dizziness over 3 months; 2) patients exhibiting no nystagmus and abnormal eye movements were observed in videonystagmoscope; 3) patients exhibiting no abnormal findings on electronystagmography, the caloric test, and VOR (vestibulo-ocular reflex) gain; 4) patients with no left and right difference in hearing; 5) patients showing no abnormal findings on the brain MRI except changes due to aging; 6) patients with no past history of middle and inner ear disease; 7) patients showing no abnormal findings on the other tests (i.e. blood pressure, blood, serum, neurological and ophthalmological examinations, and electrocardiography); 8) patients exhibiting no psychological and neurological problems (patients with apparent psychogenic disorders such as depression and with neurological disease such as Parkinson's disease were excluded.); 9) patients who could be observed for more than 6 months after the first examination.

Normal subjects

We studied 51 normal subjects as controls, including 32 men and 19 women ranging in age from 21 to 81 years, with a mean age of 44.7 years. Before inclusion in the study,

informed consent was obtained from all subjects. The procedures followed were in accordance with the ethical standards of the responsible committee on human experimentation and with the Helsinki Declaration of 1975, as revised in 1983.

Measurement of SVV

Subjects were seated on a chair in a completely dark square room where no other visual clues were present, with their head and chin fixed on chin forehead rests in an upright position. A luminous straight bar (80 mm in length and 10 mm in diameter) was back-projected to a large black screen that was placed 50 cm in front of the subject. The examinees were told to rotate the position of the bar with a joystick, and were instructed to use the joystick to bring the line to vertical. The true vertical orientation was set as 0°, and the initial orientation of the line was randomized before each trial. Tilts of SVV were indicated as angles and leftward and rightward tilts were represented by negative and positive angles, respectively. Tilts of SVV were measured 10 successive times for each patient, and were averaged. In normal subjects, SVV mean tilt was determined and in the patient group (n=44) the number of patients showing abnormal tilts of SVV was counted.

Measurement of ocular torsion

Ocular torsion (OT) was also measured in patients showing abnormal tilts of SVV. The OT was determined from a fundus photograph taken using a scanning laser ophthalmoscope (Rodentstock, Germany). The angle was measured by projecting a straight line through the center of the papilla and fovea against a horizontal line as a base. In the right eye counterclockwise rotation from the perspective of the examiner was defined as positive excyclotropia, while in the left eye clockwise rotation was defined as positive excyclotropia. Measurements were taken twice and averaged, and the OT [(right eye OT/2)-(left eye OT/2)] was calculated. Based on our data obtained from 53 normal healthy subjects an abnormal range of OT was defined as $>5.0^\circ$ or $<-5.0^\circ$, and an abnormal change in OT was defined as a difference of >2.58 between the two measurements [6].

Results

In normal subjects, SVV mean tilt was $0.22 \pm 1.26^\circ$ (mean \pm standard deviation), therefore, the mean \pm 2SD ranged from -2.30 to 2.74 (Figure 1). In the patient

group, 3 cases, corresponding to 6.8% of the subjects, showed abnormal tilts of SVV, while the other 41 cases showed normal values of tilt (Figure 2). Among the three cases, case 1 was a 69-year-old woman who suffered from chronic dizziness lasting for 2 years. In this case, the dizziness continued after some improvement, and abnormal tilts of SVV have also continued and deep white matter hyperintensity (DWMH) was observed around the basal ganglia on MRI (Figure 3). Cases 2 and 3 also showed DWMH. Table I provides a summary of the three cases showing abnormal tilts of SVV. The three cases with DWMH sometimes complained of lateral postural instability. In the patient group, 6 patients including the 3 cases had DWMH; however, the remaining 38 cases did not exhibit DWMH.

Discussion

In normal subjects, vertical perception is extremely accurate [7,8] and reproducibility of SVV is extremely high [3]. In previous studies on SVV, normal healthy subjects indicated angles of SVV tilts within 938 [9]. In the present study, values of tilt of SVV in normal healthy subjects (0.2291.268) correlated extremely well with the data in previous studies. Thus, in the present study, when abnormal values of SVV were observed in the SVV test, abnormalities of the otolithic organs or the graviceptive pathways were assumed to be highly indicated. The three cases showing abnormal tilts of SVV were elderly persons and DWMH was observed in their brain MRI. It is known that vestibular function gradually deteriorates with aging [10]; however, the tilts of static SVV in elderly individuals were not different from those observed in younger individuals [11]. In the present study, to prevent artefactual measurements of SVV, ocular torsion was further measured and the three cases showed abnormal tilts of ocular torsion as well. Thus, the three cases can be concluded to have disturbance in the otolithic organs and the graviceptive pathways. Since the three cases did not have an otologic disease, the possibility that the cases had abnormalities limited to only the otolithic organs is assumed to be low. Thus, the responsible site for abnormal tilts of SVV in the three cases may be present in the brain. However, since structural abnormalities of the brain such as DWMH are common in both dizzy and non-dizzy subjects over the age of 65, it should be considered whether DWMH always has a pathological meaning. However, it was recently suggested that DWMH was related to disequilibrium [12,13]. It is known that abnormal tilts of the SVV are observed in cerebral hemispheric stroke, and the responsible site is assumed to be present in lesions of the vestibular cortex, or subcortical afferences [14,15]. When DWMH is formed in the graviceptive pathways in the brain, abnormal tilts of SVV may be observed.

Further studies containing a large group of patients should be conducted to clarify the relationship between DWMH and graviceptive function. Clinical examination of the function of the otolithic organs is rudimentary. Also, a simple clinical test for unilateral otolithic function and the graviceptive pathways has not yet been established. However, the SVV test is easy to conduct and not invasive; it is a simple, quick otoneurological examination providing information on the tonic afferent balance or imbalance in the otolith organs and the graviceptive pathways. In the present study, the SVV test could indicate dysfunction of the otolithic organs and perception of gravity in patients with dizziness who had no abnormal finding on routine tests for the vestibular system. The SVV test should be involved in routine vestibular function tests for patients complaining of chronic dizziness.

Declaration of interest: The authors report no conflicts of interest. The authors alone are responsible for the content and writing of the paper.

References

- [1] Fetter M. Assessing vestibular function: which tests, when? *J Neurol* 2000; 247: 335-42.
- [2] Tabak S, Collewyn H, Boumans LJJM. Deviation of the subjective vertical in long-standing unilateral vestibular loss. *Acta Otolaryngol* 1997; 117: 1-6.
- [3] Go´mez Garcı´a A, Ja´uregui-Renaud K. Subjective assessment of visual verticality in follow-up of patients with acute vestibular disease. *Ear Nose Throat J* 2003; 82: 442-6.
- [4] Vibert D, Ha¨usler R. Long-term evolution of subjective visual vertical after vestibular neurectomy and labyrinthectomy. *Acta Otolaryngol* 2000; 120: 620-2.
- [5] Dieterich M, Brandt T. Wallenberg’s syndrome: lateropulsion, cyclorotation, and subjective visual vertical in thirty-six patients. *Ann Neurol* 1992; 31: 399-408.
- [6] Oku R, Shigeno K, Kumagami H, Takahashi H. Otolith dysfunction during vertiginous attacks in Menie`re’s disease. *Acta Otolaryngol* 2003; 123: 1035-9.
- [7] Gibson JJ. The relation between visual and postural determinants of the phenomenal vertical. *Psychol Rev* 1952; 59: 370-5.
- [8] Friedmann G. The judgement of the visual vertical and horizontal with peripheral and central vestibular lesions. *Brain* 1970; 93: 313-28.
- [9] Hafstro¨m A, Fransson P, Karlberg M, Magnusson M. Idiosyncratic compensation of the subjective visual horizontal and vertical in 60 patients after unilateral deafferentation. *Acta Otolaryngol* 2004; 124: 165-71.

- [10] Baloh RW, Ying SH, Jacobson KM. A longitudinal study of gait and balance dysfunction in normal older people. *Arch Neurol* 2003; 60: 835-9.
- [11] Kobayashi H, Hayashi Y, Higashino K, Saito A, Kunihiro T, Kanzaki J, et al. Dynamic and static subjective visual vertical with aging. *Auris Nasus Larynx* 2002; 29: 325-8.
- [12] Baloh RW, Yue Q, Socotch TM, Jacobson KM. White matter lesions and disequilibrium in older people. I. Casecontrol comparison. *Arch Neurol* 1995; 52: 970-4.
- [13] Baloh RW, Vinters HV. White matter lesions and disequilibrium in older people. II. Clinicopathologic correlation. *Arch Neurol* 1995; 52: 975-81.
- [14] Yelnik AP, Lebreton FO, Bonan IV, Colle FM, Guichard JP, Vicaud E. Perception of verticality after recent cerebral hemispheric stroke. *Stroke* 2002; 33: 2247-53.
- [15] Brandt T, Dieterich M, Daneck A. Vestibular cortex lesions affect the perception of verticality. *Ann Neurol* 1994; 35: 403-12.

Table 1. A summary of the three cases showing abnormal tilts of SVV.

| Case | Age/Gender | SVV (degree) | Ocular torsion | | DWMH |
|------|------------|-----------------|----------------|----------|------|
| | | | Right eye | Left eye | |
| 1 | 69/W | -14.0 | 4 Exc | -9 Exc | + |
| 2 | 72/M | -10.8 | 3 Exc | -9 Exc | + |
| 3 | 71/W | +7.2 | 8 Exc | 3 Exc | + |

M = Man, W = Woman, SVV = Subjective visual vertical, Exc = Excyclotropia, DWMH = Deep white matter hyperintensity, + = positive

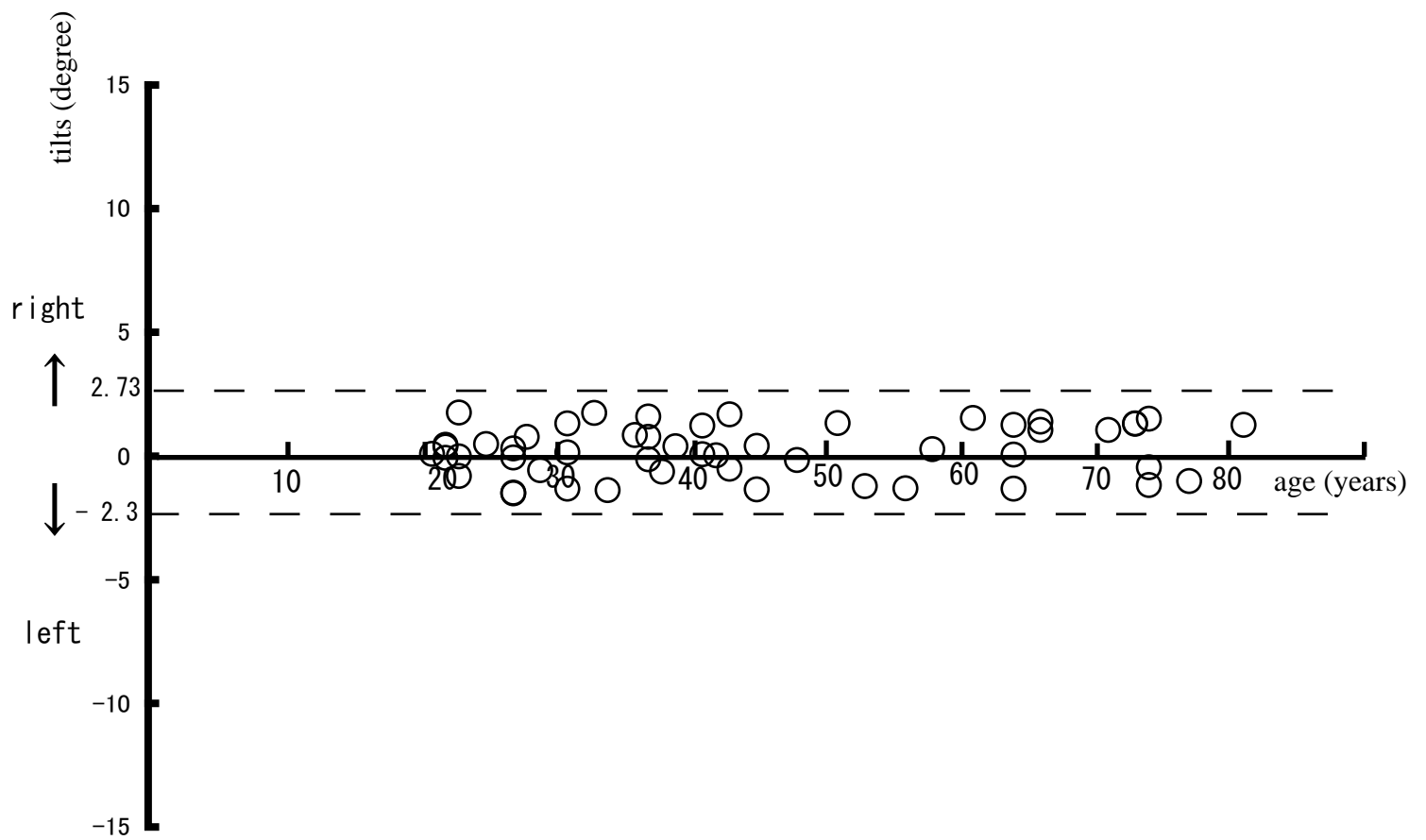


Figure. 1. SVV measurements in 51 normal subjects. An average of SVV tilts in each subject is indicated by a open circle. Note that the static SVV is stable among all subjects.

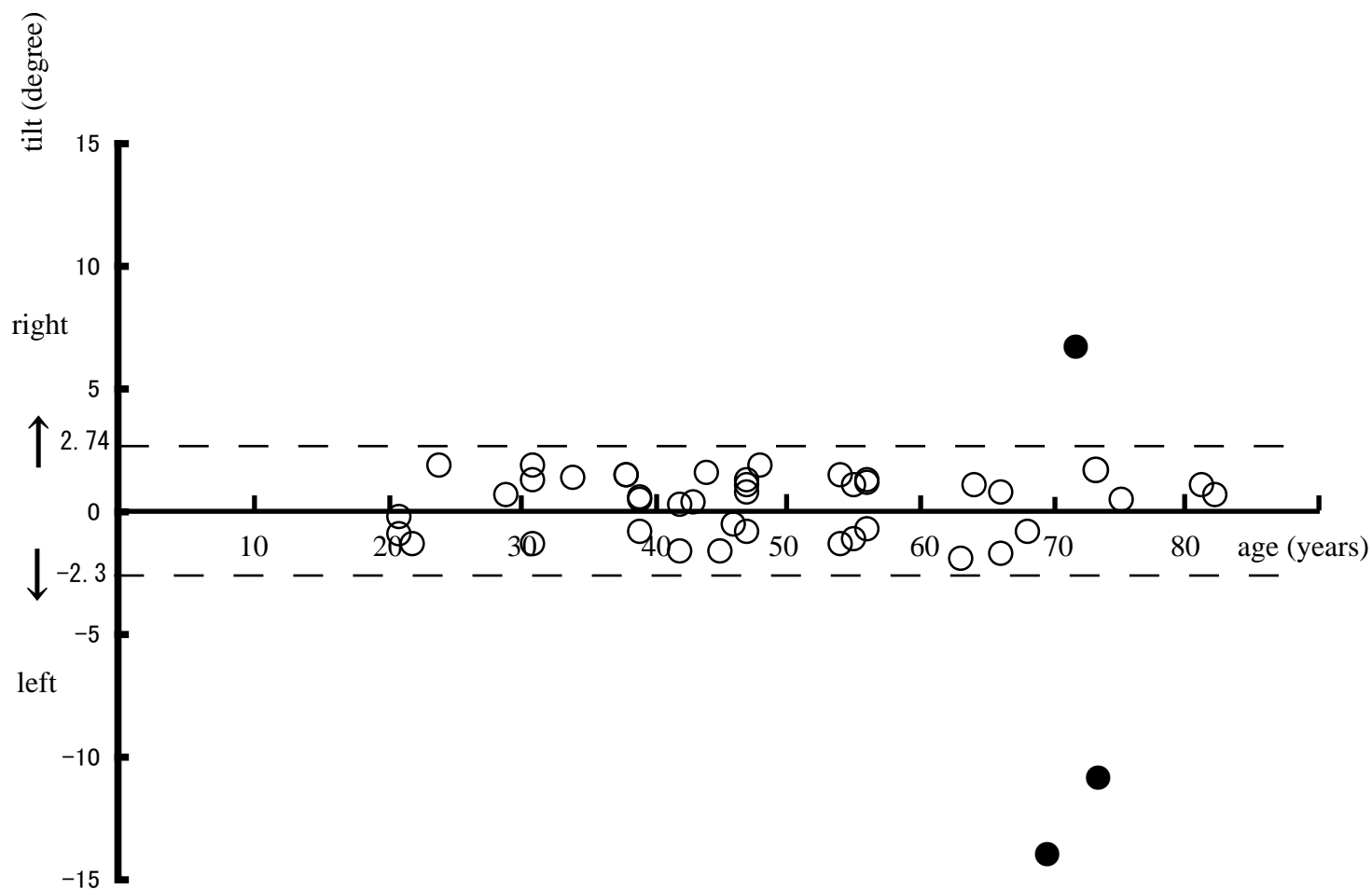


Figure 2. SVV measurements in 44 patients complaining of dizziness but having no abnormal findings. An average of SVV tilts in each patient is indicated by open circles. Three patients showed abnormal tilts of SVV (dark circles).

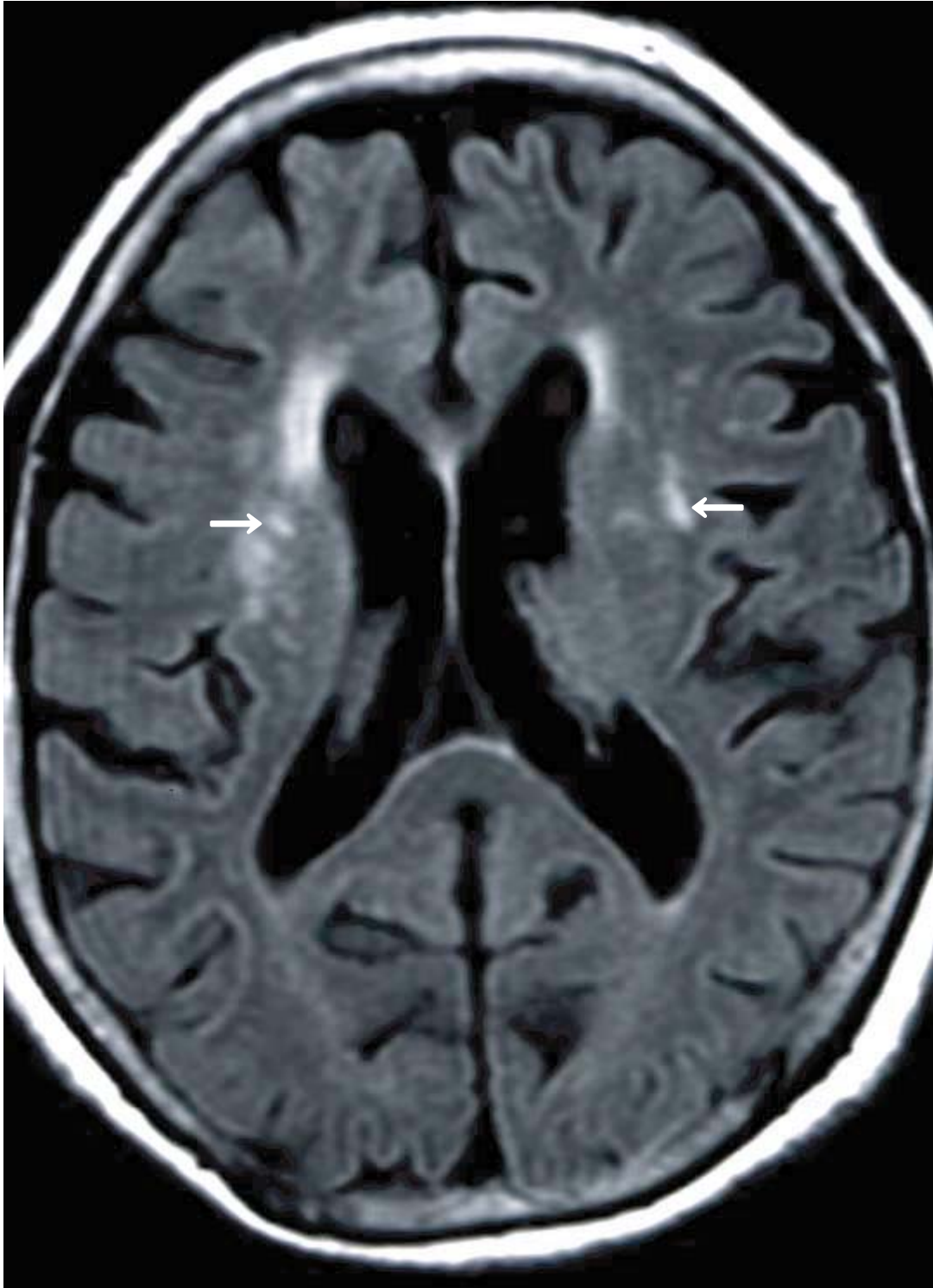

Figure 3. Brain MRI of case 1 (T2 FLAIR). Deep white matter hyperintensity is observed in bilateral basal ganglia (white arrows).

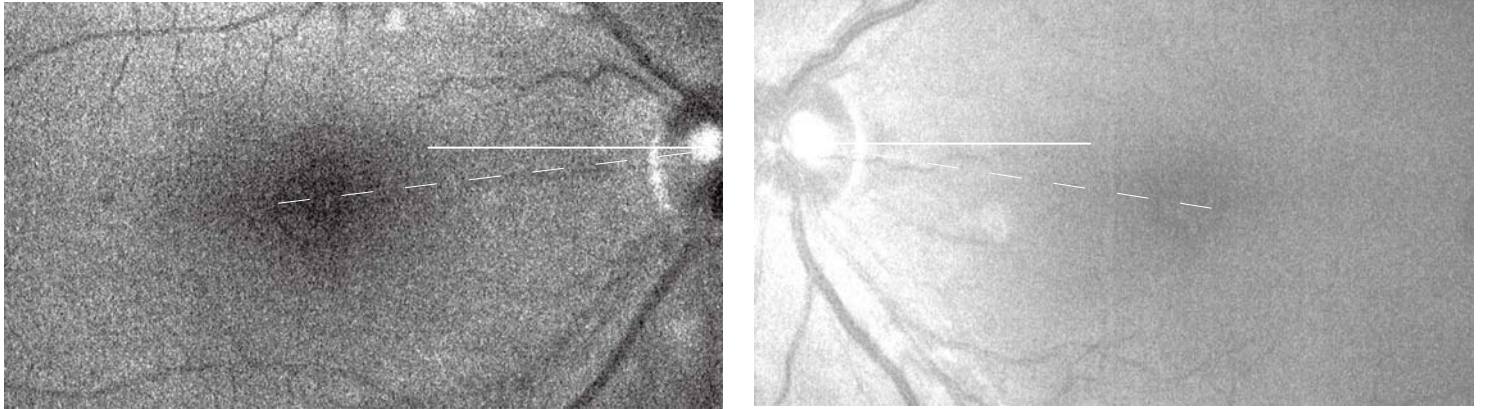


Figure 4. Fundus photographs taken by the scanning laser ophthalmoscope (case 1). The left eye shows a 9° OT (excyclotropia - that is, torsion of the papilla-fovea line clockwise from the viewpoint of the observer toward the left) and the right eye, a 4° excyclotropia.