

# Treatment of Hip and Knee Flexion Contracture in Spastic Cerebral Palsy

Tomitaro AKIYAMA<sup>1)</sup> and Yukiyoishi KAWAGUCHI<sup>2)</sup>

**Abstract** Soft tissue release operations to the hip and knee flexion contracture were performed on 108 extremities of 78 cerebral palsy patients including non-ambulatory cases.

A successful operation requires accurate assessment of contracture and complete elimination of flexion contracture. Furthermore, postoperative physiotherapy is essential for having the patient detach from the preoperative pathological postural reaction mainly involving hyperactivities of the flexors and acquiring normal postural reaction to a possible extent primarily initiated by the extensors.

The ability of locomotion was improved in 55 of 78 cases or in 71%. In severe cases, generalized hypertonia was alleviated. Improvement of the ability of locomotion after the operation required 6 months to 2 years in proportion to the severity of motor dysfunction. The most appropriate age for non-ambulatory groups (B and C groups) was 4 or 5 years.

Roentgenograms generally disclosed definite improvement of sacro-femoral angle, and in subluxation cases, CE angle and covered ratio of the femoral head.

Bull. Sch. Allied Med. Sci., Nagasaki Univ. 1 : 3-18, 1987

**Key Words :** Cerebral palsy ; Lower leg ; Flexion contracture ;  
Hip subluxation ; Operation

---

1) Department of Physical Therapy, The School of Allied Medical Sciences,  
Nagasaki University

2) Nagasaki Prefectural Crippled Children's Hospital

## Introduction

Flexor spasms as a sign of spasticity primarily consist of excessive contraction of biarticular flexors and, as they are aggravated, continuously act to restrict extension, impairing the development of co-contraction to hold anti-gravitic posture and coordinated motor function as well as resulting in flexion contracture. Further, the muscle imbalance about the hip induces structural deformities, subluxation and dislocation of the hip joint. The hip pain thus induced intensifies flexor spasms further.

Release operations were performed to the flexor muscles about the hip and knee joints for cerebral palsy children with hip and knee flexion contracture resulting from aggravated flexor spasms, including cases who were unable to maintain standing posture. It was aimed to acquire and improve the functions to maintain standing posture and to walk. The same operations were performed also for the cases with hip dislocation. Detorsio-varus osteotomy and acetabuloplasty were performed as indicated.

In cases with flexion contracture of the hip and knee, one may possibly pay attention only to spastic toe gait and perform lengthening of the calcaneal tendon. However, this surgery would intensify the crouching posture and reduce the ability of gait. The first choice in such cases would be an approach to the more proximal joint.

## Subjects and Methods

The operated subjects were 51 diplegia cases, 7 hemiplegia cases, 3 tri-plegia cases and 17 quadriplegia cases, totalling 78 cases involving 108 legs. Of the 17 quadriplegia cases, 4 cases were mixed (athetospastic) type while 13 cases were spastic cerebral palsy cases. The age at operation ranged from 4 to 28 years with the mean of 8 years. The postoperative period ranged from the minimum of 1 year and 4 months to the maximum of 8 years and 4 months, the mean being 3 years and 2 months.

The release and elongation of spastic hip flexor muscles are applicable when the structural contracture is  $15^{\circ}$  or more, or when the functional contracture is  $30^{\circ}$  or more. The elongation of spastic knee flexor muscles is available when the structural contracture is  $40^{\circ}$  or more, or when the functional contracture is  $60^{\circ}$  or more. In cases with hip dislocation or subluxation, the apparent flexion contracture angle is small despite the shortening of flexor muscles. Yet, the following soft tissue release operations are applicable to most of these cases. The functional and structural flexion contractures<sup>12)</sup> of the hip and knee were assessed upon measuring the joint extension limit angle

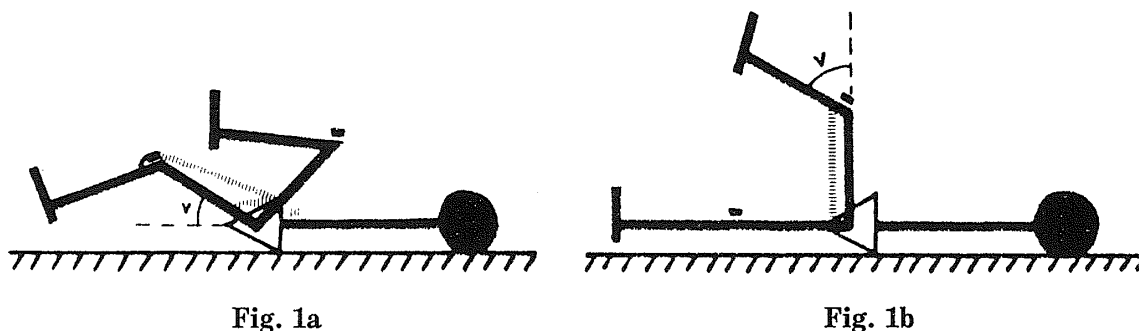


Fig. 1. Evaluation of contracture

Fig. 1a — The angle  $v$  indicates the degree of hip flexion deformity.

Fig. 1b — The angle  $v$  indicates the degree of contracture of the hamstrings.

(by J. Reimers 1974)

while giving fast stretch and slow stretch to the flexor muscles in the leg postures shown in Fig. 1a and b. The hip flexion contracture was assessed also in reference to lumbar lordosis and sacro-femoral angle.

The operation was performed in the supine position placing a pillow under the hip so as to facilitate extension of the hip during the operation.

The operation for hip flexion contracture was, as a rule, to elongate the rectus tendon and iliopsoas tendon and to release the sartorius, anterior part of the tensor fasciae latae, fascia of the gluteus medius, adductor longus and ligamentum iliofemorale. Although complete release of hip flexion contracture is essential for the efficiency of operation, the flexor muscles not participating in the contracture should be preserved to a possible extent so as to avoid weakening of hip flexion. The iliofemoral ligament is detached from the capsule by elevator and cut. In cases with severe flexion contracture, sometimes capsulectomy is required. The rectus tendon was given oblique elongation and the iliopsoas tendon Z elongation.

The iliopsoas tendon at suture was given such a tension that, in the hip extension position after release of the flexor muscles, a little finger could be inserted under the sutured tendon at an appropriate tension. The rectus tendon was elongated to an extent that the knee in the hip extension position would be easily flexed by  $90^\circ$  or more. Mean values of measured length of tendon elongation are shown in Table 1.

Table 1. Length of Tendon Elongation

	Number of cases	Mean (cm)	Standard deviation	Maximum	Minimum
Iliopsoas	88	3.84	0.88	7.0	2.0
Rectus femoris	88	2.54	0.68	4.0	1.0

Anthonsen's technique<sup>1)</sup> was used for elongation of the iliopsoas tendon and rectus tendon. The cut edge of the released sartorius was sutured with the proximal piece of the rectus tendon.

For knee flexion contracture, lengthening of the hamstrings was performed. The elongated tendons were maintained at a tension whereby, in the supine posture, the hip joint may be provided with 90° flexion and the knee joint may be easily extended to at least -30° (Fig. 1b). The inner hamstrings were elongated first and, in cases contracture could be released only by this procedure, the outer hamstring were not operated. Intramuscular elongation was performed for the semitendinosus and gracilis, and circumferential fasciotomy for the semimembranosus and biceps femoris. In elder children, the semitendinosus was provided with Z elongation. Since the semimembranosus contains tendon tissue in its anterior portion, this tendon tissue should be thoroughly separated.

In postoperative treatment, barred hip abduction plaster cast was provided from the femoral region to the foot, and the patient was placed in prone position all day from the second postoperative day to strengthen the gluteal and abdominal muscles. For cases who were unable to stand, a long-leg brace with a pelvic band was used, and it was cut off by stages to LLB and then to SLB as the standing function was acquired. These orthotic therapies were accompanied by aggressive physiotherapy. For complicated plantar flexion contracture, heel gait cast therapy<sup>2)</sup> was performed avoiding primary Achilles tendon elongation, except in elder children.

## Results

The results of treatment in terms of the ability of locomotion in 25 cases of ambulatory (independent walking) group (group A), 16 cases of propping

Table 2. Improvement of Locomotion

Group (Ability of Locomotion)	Pre-operation (cases)	Post-operation (cases)		
A (Ambulatory)	25	→	25	38
		↗	9	
		↘	4(2)	
B (Propping)	16	→	7	21
		↗	14	
C (Crawling)	28	→	10	13
		↗	3	
D (Confined to bed)	9	→	6	6
Total	78		78	78

(dependent walking) group (group B), 28 cases of creeping and crawling group (group C) and 9 cases of confined-to-bed group (group D) were as shown in Table 2.

All the cases of group A demonstrated improvement of locomotion. The most remarkable effect was that 7 cases of diplegia who were unable or had difficulty to stand still while walking due to spastic toe gait became able to stop walking and stand still by this operation. In group B, 9 of the 16 cases or 56% became ambulatory. In group C, 4 of the 28 cases or 14% became ambulatory and another 14 cases or 50% became propping. Two of the 4 cases in group C who became ambulatory were elder children with dislocation or subluxation of the hip who had been unable to walk due to pain at the hip. Except for these 2 cases, 8 of the 11 cases of group B and C who became ambulatory were 4 or 5 years of age. Six of these 8 cases became capable of outdoor walking. However, 3 elder cases over age 10 remained in indoor walking.

Even those severe cases who remained in group C or D became able to hold a standing position with the aid of brace, and also showed improvement of facial expression, lingual function and the function of the upper extremities along with the improvement of pathologic hypertone due to flexor spasms. For example, a case of triplegia (male, 24 years old) in group C with intensive flexor spasms due to pain of the right dislocated hip remained in group C even after the operation, but, in 2 years after the operation, ADL function improved remarkably and this case successfully took driver's license and is actively engaged in social activities. In this case, no treatment for hip dislocation was performed.

Usually the strength of hip and knee flexors is weakened after the operation, and hence, in the course of improvement of motor function, the ability of locomotion was temporarily reduced so as to experience difficulties in crawling, going up steps and stepping over the bathtub. The period of such a reduction ranged from 3 months to 12 months. In the cases of groups B and C whose ability of locomotion was improved so as to belong to group A, the period required for the improvement was 11 and 24 months on average, respectively. In 3 cases of group C, extensor spasms became remarkable after the operation and intensive physiotherapy was required for improvement of the motor function.

Now we would like to describe Sacro-femoral angle, CE angle and covered ratio of the femoral capital epiphysis in the acetabulum.

The Sacro-femoral angle in 31 cases without group D where pre- and post-operative measurements were available showed an improvement from the preoperative mean value of  $37.78^{\circ}$  to the postoperative mean value of  $47.00^{\circ}$  (Table 3). Bleck<sup>4)</sup> describes that the Sacro-femoral angle in normal

Table 3. Improvement of Sacro-femoral Angle

		Number of cases	Mean (degree)	Standard deviation	Maximum	Minimum
Total	Preop	31	37.78	11.49	65.0	10.0
	Postop		47.00	11.41	67.0	20.0
A	Preop	11	35.45	11.99	52.0	15.0
	Postop		49.09	13.48	67.0	20.0
B	Preop	4	35.75	5.32	40.0	29.0
	Postop		49.75	13.35	65.0	35.0
C	Preop	16	39.88	12.72	65.0	10.0
	Postop		44.88	10.11	59.0	30.0

children is in the range of  $45^{\circ}$  to  $65^{\circ}$ .

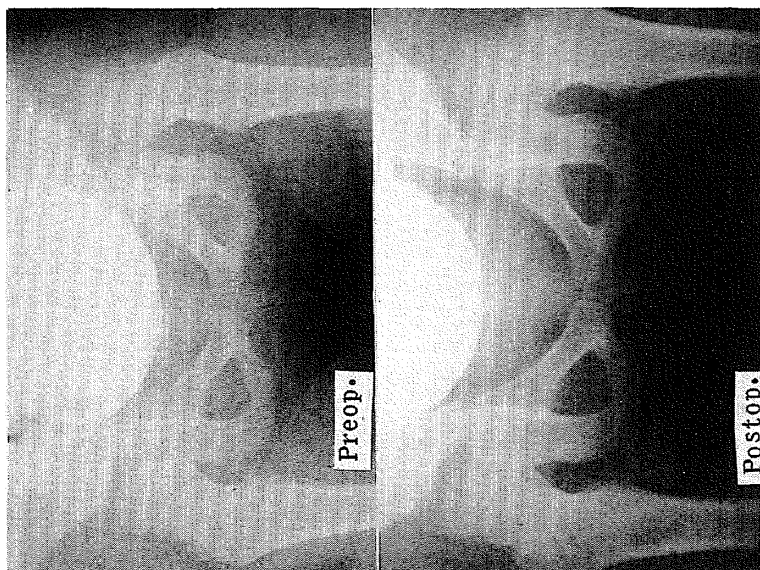
Excluding 4 cases of dislocation, 47 joints in 32 children where the preoperative CE angle was less than  $15^{\circ}$  showed improvement of CE angle from the preoperative mean value of  $3.72^{\circ}$  to the postoperative mean value of  $13.23^{\circ}$ , and 45 joints in 31 children showed improvement of covered ratio from the preoperative mean value of 55.13% to the postoperative mean value of 66.18% (Table 4). Subluxation was usually improved only by soft tissue operation (Fig. 2 a, b, c). For 2 of the 4 cases of dislocation, additional detorsiovarus osteotomy and acetabuloplasty were performed (Fig. 3). One case of old hip dislocation stated before was kept in dislocated condition, and one case soon after dislocation was provided only with flexor release and it makes satisfactory reduction. (Fig. 4).

Table 4. Improvement of CE-angle and Covered Ratio

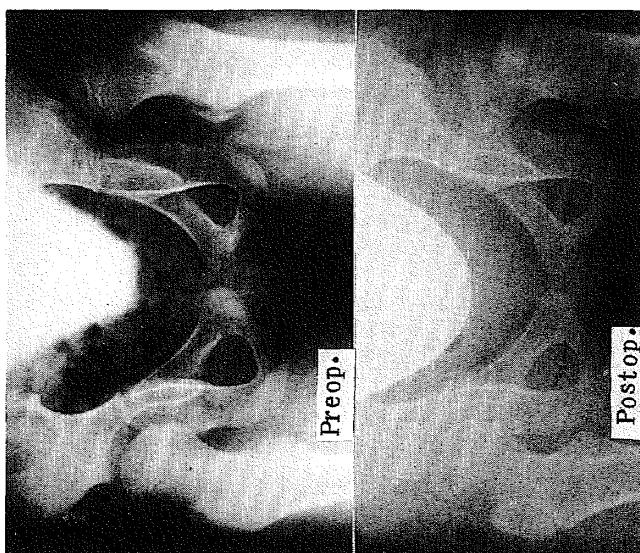
		Number of cases	Mean	Standard deviation	Maximum	Minimum
CE-angle	Preop	47	$3.72^{\circ}$	$13.94^{\circ}$	$15.0^{\circ}$	$-40.0^{\circ}$
	Postop		$13.23^{\circ}$	$6.67^{\circ}$	$28.0^{\circ}$	$0^{\circ}$
Covered ratio	Preop	45	55.13%	14.39%	72.0%	13.0%
	Postop		66.18%	11.05%	100.0%	43.0%

Equinus deformity for which tendocalcaneus lengthening was performed was observed in 21 legs of 16 children mostly over age 9. In children under age 9, the plantar flexion contracture was conservatively improved by heel gait cast.<sup>2)</sup>

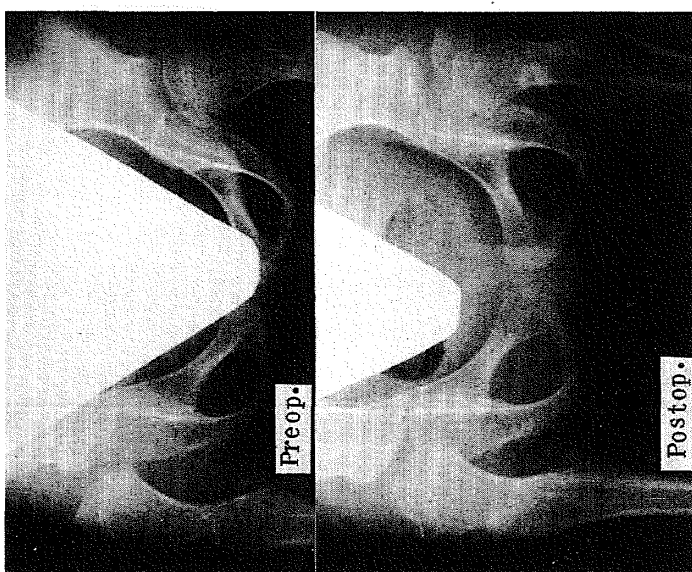
As a postoperative complication, transient dysuria was noted in the majority of cases throughout the period of postoperative 3 weeks with hip



c) Y. M. 5Y



b) N. A. 7Y



a) S. E. 9Y

Fig. 2. Roentgenogram of hip joint

- a) Quadriplegia (group D) ; CE-angle was improved from  $-40^{\circ}$  to  $10^{\circ}$  and covered ratio from 13% to 50%.
- b) Diplegia (group C) ; CE-angle was improved from  $-33^{\circ}$  to  $15^{\circ}$  and covered ratio from 22% to 50%.
- c) Diplegia (group B) ; CE-angle was improved from  $-8^{\circ}$  to  $0^{\circ}$  and covered ratio from 36% to 60%.

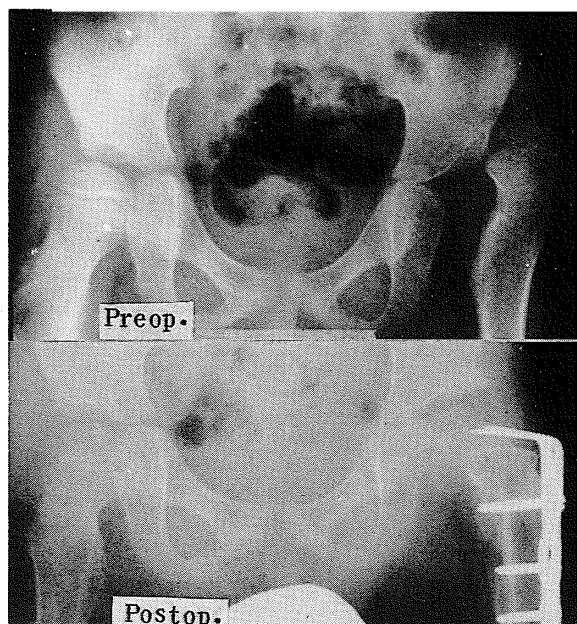


Fig. 3. S. T. 6Y

Detorsio-varus osteomy and acetabuloplasty

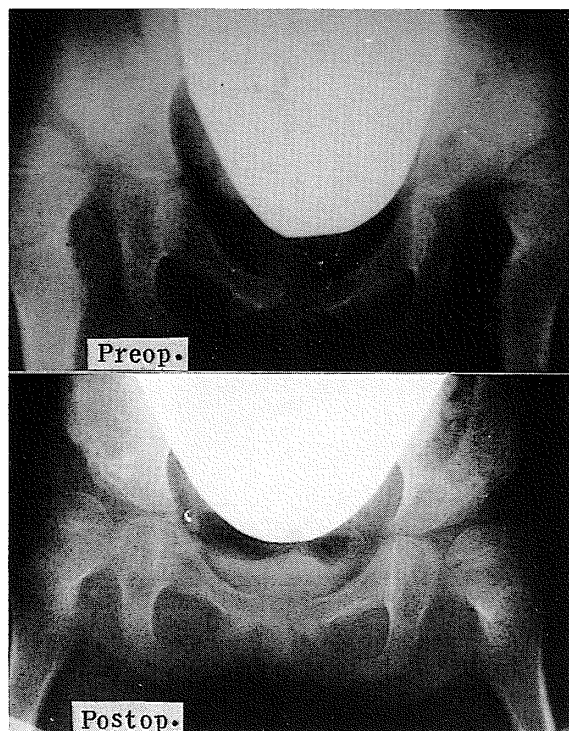


Fig. 4. N. I. 5Y

Soft tissue release operations

abduction plaster cast. In 31 children whose urination was thoroughly observed, catheterization was performed for all the cases for two days after the operation. During several days after the removal of catheter, incontinence was remarkable in 18 children or 58%, slight in 5 children or 16%, and recatheterization was required in 3 children or 10% due to dysuria. Slight dysuria persisted in about half of the children throughout the period of plaster cast application but it disappeared as the plaster cast was removed.

The results of treatment for 2 typical cases are described below. In these cases, hip flexion contracture was measured in lateral position.

[Case 1.] An 8-year-old boy, immature baby (AFD) weighing 1500 g at birth. He was of diplegic type and belonged to group A having become ambulatory at age 4. He had spastic toe gait with scissors posture and was unable to stop and stand still while walking. Flexion contracture of the hip and knee was evident in view of the intensified lumbar lordosis in supine position and backward inclination of the pelvis and kyphosis of the spine in sitting position. Elongation of the Achilles tendon had been recommended.

In the hip, the functional and organic flexion contracture at fast and slow stretch tests was bilaterally  $-30^{\circ}$  and  $-20^{\circ}$  respectively, and the Sacro-femoral angle was  $24^{\circ}$ . In the knee, it was  $-90^{\circ}$  and  $-60^{\circ}$  respectively. In the



ankle, the functional and organic extension contracture was  $-20^{\circ}$  and  $0^{\circ}$  respectively. Release and lengthening of the hip and knee flexors were performed for this case, and the flexion side of the hip joint including the iliofemoral ligament was completely divided transversely. For equinus deformity, heel gait cast therapy was performed.

At present, one and a half years after the operation, his walking ability has been heightened and even a pause while walking has become available. Organic contracture is eliminated and functional contracture is improved. The functional contracture of the ankle at fast stretch is  $-5^{\circ}$  for right and  $-10^{\circ}$  for left. Heel gait cast therapy is being continued. The Sacro-femoral angle has been improved to  $52^{\circ}$  (Fig. 5). This case became ambulatory in 2 months after the operation but required about 1 year for the complete recovery of the strength of the leg flexors.

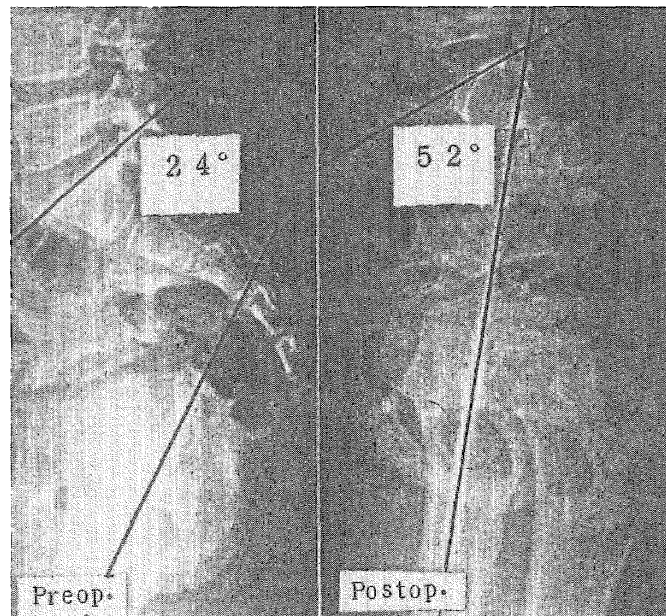


Fig. 5. Case 1

Improvement of sacro-femoral angle

[Case 2.] A 5-year-old boy, diplegic type. This boy was born immature (AFD) weighing 1420 g. Physiotherapy was commenced 6 months after the birth. He belonged to group B being unable to stand and walk. Though propping was available, flexion spasms resulted in marked crouching posture at each step of gait. Knee standing showed flexion of the hip and half knee standing was unstable. Locomotion depended mostly on crawling.

The functional and organic flexion contracture of the hip at fast and slow stretch was  $-30^{\circ}$  and  $-15^{\circ}$  for right and  $-20^{\circ}$  and  $-15^{\circ}$  for left, respectively. The SF angle was  $40^{\circ}$ . In the knee, the functional and organic flexion

contracture was bilaterally  $-60^{\circ}$  and  $-40^{\circ}$  respectively. In standing position, talipes equino-valgus was shown, and in the ankle, functional extension contracture at fast stretch was  $-20^{\circ}$  for right and  $-10^{\circ}$  for left, but organic extension contracture was not observed.

For elongation and release of the hip and knee flexors, soft tissue operation was performed and the flexion side of the hip joint was completely divided. In postoperative therapy, a long-leg brace with a pelvic band was used for exercise to acquire standing function. At first, the brace was set at the hip with slight hyperextension. As the standing function was acquired, it was set at midline and then removed gradually from the proximal joint. In this case, the pelvic band was removed 2 months after the operation, which was followed by SLB in 4 months, and walking became available in 6 months when the brace was completely removed. Postoperative drop of activity of the day living (ADL) was recovered in 3 months. However, 9 months were required to acquire sufficient strength of the hip flexors.

At present, 3 and a half years after the operation, gait is indefinitely available and going up and down stairways at school can be made as fast as normal children with the help of handrail. The extension of the hip shows  $10^{\circ}$  at both slow stretch and fast stretch, and thus flexion contracture has been eliminated completely. The SF angle has been improved to  $56^{\circ}$ . Knee extension at fast stretch shows  $-40^{\circ}$  for right and  $-30^{\circ}$  for left with a tendency of some recurrence. Fig. 6a, b, c show the pre- and post-operative conditions.

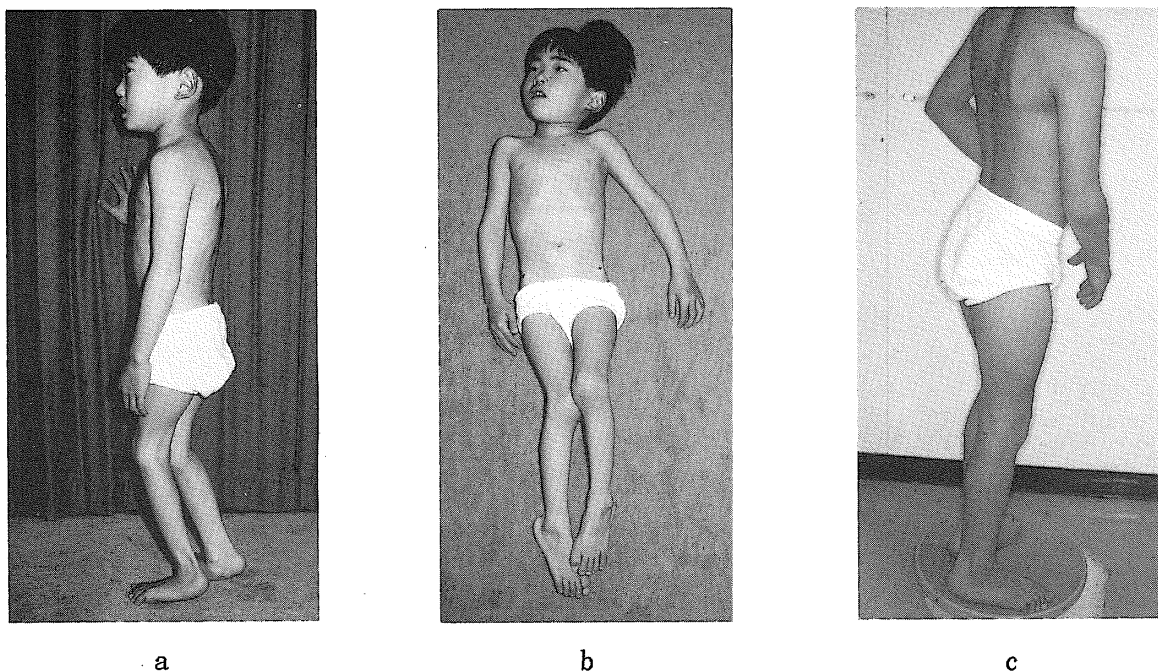


Fig. 6. Case 2

- a), b) Preoperation ; Crouching posture, Scissors posture.  
c) Postoperation ; Balance board exercise.

## Discussion

In the course of motor development in normal infants, antigravitative postural reaction develops favorably. Balance reaction (tilting reaction)<sup>11)</sup> in prone position is acquired in 5 months, in supine position in 7 months, in sitting position in 8 months, in all fours position in 10 months and in standing position in 15 months. In parallel to the development of postural reaction, immature and primitive total motor pattern develops to more mature and refined selective motor pattern.

The presence of spasms in cerebral palsy children not only disturbs the development of postural reaction but also causes the children to acquire a stereotyped primitive motor pattern in various degrees being affected by the tonic reflexes<sup>5)</sup> (tonic labyrinthine reflex, tonic neck reflex, associated reaction, positive and negative supporting reactions). Once contracture and deformity are caused in growing children, no matter how slight they may be, they are steadily intensified as the children grow and the motor function is further impaired.

The gait of spastic diplegia is represented by scissors gait. In standing position, total extension pattern of the whole legs accompanied with plantar flexion is induced. Since the ground contacting area is small, the pressure of forefoot against the floor results in leaning the whole body backwards. However, by bending forward the head and body where voluntary control is possible and thus applying total flexion pattern to the whole body, balance in standing position becomes possible.<sup>6)</sup> Such a combination of extensor and flexor spasms induces typical scissors posture. When spasticity is more intensive, the chance of taking standing position decreases while the time of taking sitting position increases, and thus total flexion pattern becomes dominant. Even if one potentially has the ability to walk, extensor muscles are affected by reciprocal inhibition due to flexion spasms and the development of co-contraction is further inhibited developing into flexion contracture with the lapse of time.

Such contracture should be prevented by conservative treatment. However, once it is caused, correction by operation is necessary. Reimers<sup>13)</sup> took up static and dynamic problems in spastic cerebral palsy with hip and knee flexion contractures and plantar flexion contracture, emphasizing the importance of adequate correction in appropriate procedure and warning against faulty treatment. For example, primary lengthening of the knee flexors in a case with combined contractures in the hip and knee results in forward inclination of the pelvis, and consequently in increased lumbar lordosis or resumption of flexion posture, and thus motor function is further deteriorated. If the

contracted hip flexors are then lengthened as a secondary procedure, the hamstrings become loose and weak, and if the gluteal muscles are not strong enough, the patient still stands and walks with hip and knee flexion as warned by Reimers. In order to avoid such faulty treatment, it is essential to assess the contracture accurately while paying attention so as not to overlook the contracture of more proximal joints. The crouching posture is intensified after elongation of the Achilles tendon for a case of toe gait with hip and knee flexion contracture.

Treatment for hip flexion contracture has been reported by many investigators.<sup>1)4)9)10)14)</sup> The purpose of this treatment is to improve the muscle imbalance about the hip by eliminating flexion contracture and controlling flexor spasms, and, after the operation, to enhance antigravitic co-contraction pattern (stabilizing function)<sup>16)</sup> by strengthening the activity of extensors, so that the patient may acquire more normal posture and the ability of locomotion. Complete release of flexion contracture is essential for successful operation. For example, in operation for hip flexion contracture, if the contracture of the tensor fasciae latae or iliofemoral ligament is not released even though the iliopsoas tendon and rectus tendon are adequately elongated, hip extension will be unavailable and thus stabilizing function will be difficult to acquire.

Reimers released the hip flexors primarily and the knee flexors secondarily for combined contractures of the hip and knee. However, as long as the knee flexion contracture is assessed accurately, simultaneous release of hip and knee joints would not result in excessive elongation and it is rather advantageous to postoperative treatment. All but one of our operated cases had combined contractures of the hip and knee, and simultaneous operation of the hip and knee was performed for all but two of these cases. In patients with hip dislocation or subluxation, the hip flexors and knee flexors should be elongated simultaneously. One case with flexion contracture only in the hip belonging to group B had weak gluteus medius. For this case Barr's operation<sup>7)</sup> was also performed in addition to elongation of hip flexors. This patient became ambulatory in one year after the operation.

Operation for talipes equinus was required for 21 legs in 16 cases out of 108 legs in 78 cases, but heel gait cast therapy resulted in improvement of plantar flexion contracture in many other cases. The structural contracture of the triceps surae muscle in children up to age 8 cannot be said true contracture but the muscle is in a pre-contracture state with reversibility. Hence this technique is applicable to the cases in which dorsiflexion of the ankle to 0° at slow stretch was available. The first application of cast at the rectangular position resulted in reduced spasms and contracture, and then, from the second

application, heel gait cast in 5–15° dorsiflexed position was available.

For non-ambulatory groups (B, C and D), primary Achilles tendon elongation was avoided, because the plantar flexion of the ankle acts favorably in strengthening stabilizing function of the hip and knee. For cases with difficulty in ground contact of heel due to spasticity of the triceps surae muscle, standing exercise by the use of brace with high heel helped ground contact of the heel. Secondary elongation of the Achilles tendon was performed as required after the patient acquired co-contraction of the muscles about the hip and knee and became able to support the body weight.

For 5 cases of equinus deformity with calcaneovarus in the ambulatory group (group A), Dwyer's operation<sup>8)</sup> was performed in addition to the operation for the hip and knee flexors.

The indication of release and lengthening of the hip and knee flexors was extensive from the point of view of ability of locomotion as stated above, but the effect of operation was most remarkable in 4- to 5-year-old children in groups B and C. In elder children also, standing function was acquired and, even though independent walking was unavailable, the ability of locomotion and ADL were improved.

The cases in group D confined to bed are usually forced to assume a certain posture for a long time and are often complicated with Schräglageschaden<sup>9)</sup> resulting from the asymmetry of posture. As they grow older, it develops into deformity of joints, hip dislocation and scoliosis, and the occurrence of pain further increases flexor spasms and aggravates the handicap. However, even for these serious cases, motor function can be elevated by timely and appropriate treatment.

It is needless to say that physiotherapy is essential for promoted effect of operation. The acquisition of balance reaction in standing posture with small supporting area is particularly difficult for the patients who have pathologic symptoms such as spasticity, athetosis and ataxia. However, since postural reaction is learned by experience, giving them as many chances of experience as possible is a clue to activating their potential ability. The release operation of hip and knee flexion contractures is to provide chances for assuming normal standing posture to a possible extent. Hence thorough postoperative treatment is desirable. In our physiotherapy, emphasis was placed on enhancement of postural reaction and on training to strengthen the abdominal and gluteal muscles.

It required 6 months to 2 years for the improvement of the ability of locomotion. The period required for improvement was proportional to the severity of motor function impairment. This fact should be explained thoroughly to the patients and/or parents before operation.

The stronger is the spasticity, the greater is the effect of the two super-powers, namely, extensor spasms and flexor spasms, resulting in either total extension or total flexion while the motility in the intermediate area is restrained. In these severe cases, flexor release is followed by a rise of extensor spasms. However, the latter is reduced as the stabilizing function is promoted by physiotherapy.

After the operation, thorough consideration should be given to the control of urination since operation is often followed by dysuria though it is transient.

## Conclusions

1. All the 25 cases of group A demonstrated improvement of locomotion. In group B (16 cases), 56% became ambulatory. In groups C (28 cases) and D (9 cases), 64% and 33% respectively showed improvement of locomotion by 1 or more grades.

2. In the non-ambulatory groups (B and C), the most appropriate age for operation was 4 or 5 years old.

3. It required 6 months to 2 years for improvement of the ability of locomotion. The period required for improvement was proportional to the severity of impairment.

4. This treatment was effective also for the prevention of secondary hip dislocation due to spasticity.

5. In spastic cerebral palsy with scissors posture or toe gait, operation for knee and ankle contractures is apt to be performed primarily. Accurate preoperative assessment of hip flexion contracture is important since faulty treatment results in reduced motor function.

6. Partial release and elongation of hip flexion contracture is ineffective. Complete division of the anterior part of the hip is essential.

7. For plantar flexion contracture, conservative treatment should be performed to a possible extent avoiding primary elongation of the Achilles tendon.

The summary of this paper was reported at the 56th Meeting of the Japanese Orthopedics Society (Kyoto).

## References

- 1) Anthonsen, W. : Treatment of Hip Flexion Contracture in Cerebral Palsy Patients. *Acta Orthop. Scand.*, 37 : 387-393, 1966.

- 2) Akiyama, T and Kawaguchi, Y. : Heel Gait Cast Therapy. *Seikeigeka (Orthopaedics) Mook No. 20* : 141–154, 1981. (Japanese)
- 3) Bernbeck, R and Sinios, A. : *Vorsorgeuntersuchungen des Bewegungsapparates im Kindesalter-Orthopadische und neuromotorische Diagnostik*. 1st. edition Urban & Schwarzenberg, München-Berlin-Wien, 55–58, 1975.
- 4) Bleck, E.E. : Postural and Gait Abnormalities Caused by Hip-Flexion Deformity in Spastic Cerebral Palsy. *J. Bone and Joint Surg.*, 53-A : 1468–1488, 1971.
- 5) Bobath, K. : The Motor Deficit in Patients with Cerebral Palsy. *Clinics in Developmental Medicine No. 23*, William Heinemann Medical Books Ltd., London, 27–35, 1966.
- 6) Bobath, B. : Abnormal Postural Reflex Activity Caused by Brain Lesions. William Heinemann Medical Books Ltd., London, 34–41, 1971.
- 7) Barr J.S. : Muscle Transplantation for Combined Flexion-Internal Rotation Deformity of the Thigh in Spastic Paralysis. : *Arch. Surg.*, 46 : 605–607, 1943.
- 8) Dwyer F.C. : The Treatment of Relapsed Club Foot by the Insertion of a Wedge into the Calcaneum. *J. Bone and Joint Surg.*, 45-B : 67–75, 1963.
- 9) Frost, H.M. : *Orthopaedic Surgery in Spasticity*. Charles C Thomas, Illinois, 1972, 132–145.
- 10) Keats, S. : *Operative Orthopedics in Cerebral Palsy*. Charles C Thomas, Illinois, 1970, 110–168.
- 11) Milani-Comparetti, A. and Gidoni, E.A. : Routine Developmental Examination in Normal and Retarded Children. *Dev. Med. Child Neurol.*, 9 : 631–638, 1967.
- 12) Reimers, J. : Contracture of the Hamstrings in Spastic Cerebral Palsy. *J. Bone and Joint Surg.*, 56-B : 102–109, 1974.
- 13) Reimers, J. : Static and Dynamic Problems in Spastic Cerebral Palsy. *J. Bone and Joint Surg.*, 55-B : 822–827, 1973.
- 14) Roosth H.P. : Flexion Deformity of the Hip and Knee in Spastic Cerebral Palsy : Treatment by Early Release of Spastic Hip-Flexor Muscles. *J. Bone and Joint Surg.*, 53-A : 1489–1510, 1971.
- 15) Stockmeyer, M.A. : An Interpretation of the Approach of Rood to the Treatment of Neuromuscular Dysfunction. *Am. J. Phys. Med.*, 46 : 900–956, 1967.

(Received Dec. 28, 1987)

## 脳性麻痺股，膝関節屈曲拘縮に対する 治療効果

穂山富太郎<sup>1)</sup> 川口 幸義<sup>2)</sup>

1) 長崎大学医療技術短期大学部理学療法学科

2) 長崎県立整肢療育園

**要 旨** 歩行不能例を含めた脳性麻痺患者 78 例 108 肢の股，膝関節屈曲拘縮に対し，腸腰筋，ハムストリングを含めた屈筋群および他の軟部組織の解離，延長術を施行した。

手術目的は，屈曲拘縮の除去，屈筋共同収縮の抑制および伸筋群の機能強化により，股関節周囲筋のインバランスを改善し，股関節の求心性を改善すると同時に立位姿勢保持機能および移動能力を高めることにあった。

78 例中 55 例 71% に立位姿勢保持機能および移動能力に改善をみた。移動能力の改善には術後 6 カ月～2 年間かかり，重度であればあるほど長期間を要した。B, C 群において，手術の最もよい適応年齢は 4～5 歳であった。股関節亜脱臼例においてレ線上 SF 角，CE 角，骨頭被覆率に明らかな改善を得た。

長大医短紀要 1 : 3-18, 1987