

# Long-term Outcome of Percutaneous Treatment and Surgery for Postoperative Benign Biliary Stricture

Yoshitsugu TAJIMA, Tamotsu KUROKI, Noritsugu TSUNEOKA, Tomohiko ADACHI, Takehiro MISHIMA, Taiichiro KOSAKA, Takashi KANEMATSU

Department of Surgery, Nagasaki University Graduate School of Biomedical Sciences, Nagasaki, Japan

The aim of this study was to assess the therapeutic efficacy and long-term outcome of percutaneous and surgical treatment in patients with postoperative biliary stricture. The subjects consisted of 19 patients with postoperative benign biliary stricture secondary to bile duct injury or fibrosis at the bilioenterostomy. All of the patients were initially managed by percutaneous transhepatic biliary drainage. Five patients failed to achieve internalization across the stricture and then underwent a wide hilar hepaticojejunostomy. An additional 4 patients required surgery because of a complex injury involving the right hepatic artery in one and the occurrence of so-called "blind-loop syndrome" in 3. Hepatobiliary scintigraphy clearly demonstrated a functional obstacle in the bile flow in these patients. Percutaneous management with an internal/external catheter placement was accomplished in 10 patients. A successful outcome was achieved in all patients with a mean follow-up 6.7 (range 2-12) and 5.2 (range 1-12) years for the surgical and percutaneous treatment, respectively. Conclusively, postoperative biliary stricture requires multidisciplinary management. The surgical repair should therefore be carefully considered for cases with tight stricture, a complex injury, or blind-loop syndrome. In order to accurately characterize the biliary flow and to select the optimal treatment, hepatobiliary scintigraphy may thus provide us with helpful information.

ACTA MEDICA NAGASAKIENSIA 53: 23 - 28, 2008

**Keywords:** Postoperative biliary stricture; Bile duct injury; Surgical management; Percutaneous management; Hepatobiliary scintigraphy

## Introduction

Postoperative benign biliary stricture usually occurs after surgical manipulations involving the biliary tree, most notably a cholecystectomy.<sup>1-5</sup> The causes of postoperative biliary strictures may include direct injury to the bile duct, indirect injury secondary to interruption of vascular supply to a segment of the biliary tree, or fibrosis at the site of biliary-enteric anastomosis for various benign and malignant diseases. Unfortunately, the widespread use of laparoscopic cholecystectomies in the 1990s resulted in an increased frequency of bile duct injuries and associated biliary stricture. The estimated incidence of bile duct injuries, which was 0.2% to 0.3% in a large series of open cholecystectomies,<sup>1,2</sup> has risen to 0.3% to 0.5% for laparoscopic cholecystectomies.<sup>3-5</sup> The reported data have shown that postoperative benign biliary stricture can occur up to 2.7% after laparoscopic cholecystectomies.<sup>6</sup> On the other hand, House *et al.*<sup>7</sup> demonstrated that 42 of the 1595 patients (2.6%) who underwent

a pancreaticoduodenectomy developed postoperative jaundice secondary to a fibrotic stricture at the bilioenteric anastomosis. Therefore, postoperative biliary stricture can be a significant disorder that can occur after various procedures. However, the management of postoperative biliary stricture remains a difficult challenge because it can lead to life-threatening complications, such as recurrent cholangitis, ductal stones, biliary cirrhosis and portal hypertension<sup>8-10</sup> even if managed properly. The purpose of this retrospective study was to evaluate the long-term outcome achieved by the percutaneous and surgical treatment in patients with postoperative benign biliary strictures.

## Patients

From March 1991 to December 2007, a total of 19 patients underwent percutaneous and/or surgical management for postoperative benign biliary strictures at this department (Table 1). Any patients with postoperative biliary stricture due to malignant causes

**Address correspondence:** Yoshitsugu Tajima, M.D., Department of Surgery, Nagasaki University Graduate School of Biomedical Sciences, 1-7-1 Sakamoto, Nagasaki 852-8501 JAPAN

TEL: +81-(0)95-819-7316, FAX: +81-(0)95-819-7319, E-mail: ytajima@nagasaki-u.ac.jp

Received April 1, 2008; Accepted May 2, 2008

**Table 1.** Clinical features of patients who received percutaneous and/or surgical management for postoperative benign biliary strictures

Case no.	Age (years)	Sex	Primary diseases	Original surgery	Cause of biliary stricture	Type of biliary stricture	Clinical symptoms	Duration of symptoms (months)	Time from original surgery to definitive repair (months)	Passage through the stricture	Definitive repair *	Outcome	Follow-up (months)
1	39	F	Cholecystolithiasis	Laparoscopic cholecystectomy	Bile duct injury	IV	Cholangitis, jaundice	4	4	No	Hepaticojejunostomy	successful	21
2	55	M	Cholecystolithiasis	Open cholecystectomy	Bile duct injury	III	Cholangitis, jaundice	132	156	No	Hepaticojejunostomy	successful	49
3	47	M	Cholecystolithiasis	Laparoscopic cholecystectomy	Bile duct injury	II	Cholangitis, jaundice	35	35	No	Hepaticojejunostomy	successful	66
4	53	F	Cholecystolithiasis	Laparoscopic cholecystectomy	Bile duct injury	II	Jaundice	3	3	No	Hepaticojejunostomy	successful	71
5	45	F	Cholecystolithiasis	Open cholecystectomy	Bile duct injury	IV	Cholangitis, jaundice	3	3	No	Hepaticojejunostomy	successful	149
6	72	M	Cholecystolithiasis	Laparoscopic cholecystectomy	Bile duct injury	IV	Cholangitis	30	56	Yes	Percutaneous (16F, 30M)	successful	30
7	74	F	Cholecystolithiasis	Laparoscopic cholecystectomy	Bile duct injury	II	Cholangitis	4	12	Yes	Percutaneous (16F, 12M)	successful	63
8	60	M	Gastric ulcer	Distal gastrectomy	Bile duct injury	III	Cholangitis, jaundice	4	4	Yes	Percutaneous (10F, 8M)	successful	57
9	37	M	Cholecystolithiasis	Laparoscopic cholecystectomy	Bile duct injury	IV	Cholangitis	80	108	Yes	Right hepatectomy	successful	69
10	51	F	CBD	Hepaticojejunostomy	Stomal fibrosis	III	Cholangitis	26	26	Yes	Hepaticojejunostomy	successful	44
11	53	F	Hepaticolithiasis	Hepaticojejunostomy	Stomal fibrosis	II	Cholangitis	24	276	Yes	Hepaticojejunostomy	successful	123
12	50	F	CBD	Hepaticojejunostomy	Stomal fibrosis	II	Cholangitis	58	62	Yes	Hepaticojejunostomy	successful	125
13	57	M	Cholangioma	Left hepatectomy	Stomal fibrosis	IV	Cholangitis	2	6	Yes	Percutaneous (10F, 8M)	successful	12
14	71	F	Gallbladder carcinoma	Pancreaticoduodenectomy	Stomal fibrosis	III	Jaundice	11	11	Yes	Percutaneous (14F, 12M)	successful	47
15	61	F	Hepaticolithiasis	Hepaticojejunostomy	Stomal fibrosis	IV	Cholangitis	93	96	Yes	Percutaneous (14F, 14M)	successful	52
16	68	F	Gallbladder carcinoma	Right hepatic trisegmentectomy	Stomal fibrosis	IV	Cholangitis, pneumonia	14	84	Yes	Percutaneous (14F, 14M)	successful	53
17	60	M	IPMN of the pancreas	Pancreaticoduodenectomy	Stomal fibrosis	IV	Cholangitis	4	24	Yes	Percutaneous (10F, 12M)	successful	64
18	56	M	Hepaticolithiasis	Left hepatectomy	Stomal fibrosis	IV	Cholangitis	189	192	Yes	Percutaneous (16F, 8M)	successful	92
19	66	F	Hepaticolithiasis	Choledochoduodenostomy	Stomal fibrosis	IV	Cholangitis	250	252	Yes	Percutaneous (16F, 11M)	successful	152

CBD: Congenital biliary dilatation, IPMN: intraductal papillary mucinous neoplasia

\* In parentheses are the size (F: French) and the duration (M: month) of catheter left in place for biliary stricture.

were excluded. All patients presented with clinical symptoms; recurrent cholangitis in 17, obstructive jaundice in 7, or relapsing pneumonia due to bronchobiliary fistula in one, and were therefore prepared to undergo treatment. The duration of their symptoms ranged from 2 months to 21 years. The subjects consisted of 8 men and 11 women with a mean age 57 (range, 37-74) years. In 7 patients, the original surgery resulting in a bile duct injury or stricture was performed at this hospital. The remaining 12 patients were referred from outside hospitals after undergoing their original surgery. The stricture of the bile duct secondary to bile duct injury included 9 patients, in whom the original operations were a laparoscopic cholecystectomy for cholecystolithiasis in 6, an open cholecystectomy for severe acute cholecystitis in 2, and a distal gastrectomy for gastric ulcer in one. The bile duct injuries were identified during the original surgery in only 3 cases. Although these patients underwent an immediate repair during the same operation by performing a Roux-en-Y hepaticojejunostomy in 2 and a primary suture of the bile duct in one, they resulted in postoperative biliary strictures. Meanwhile, the stricture at the site of the biliary-enteric anastomoses performed as an elective operation for various benign and malignant hepato-biliary pancreatic diseases were recognized in 10 patients, i.e., the end-to-side hepaticojejunostomy in 9 and the side-to-side choledochoduodenostomy in one. According to Bismuth's classification,<sup>11</sup> the level of biliary stricture was classified as type 2 in 5 patients, type 3 in 4, and type 4 in 10.

#### Percutaneous transhepatic management

Percutaneous management included the transhepatic direct puncture of an intrahepatic bile duct, contrast injection, guide wire insertion across the stricture, stricture dilation, and placement of an internal/external percutaneous catheter. After an evaluation of the patient's

general condition, as well as the biliary tree with imaging studies, a percutaneous transhepatic cholangiography and subsequent placement of a 7-Fr percutaneous transhepatic biliary drainage (PTBD) catheter (Akita Sumitomo Bakelite, Tokyo, Japan) were performed. The PTBD was always carried out under the guidance of ultrasonography. At the initial catheter drainage procedure or during the subsequent sessions, attempts were made to cross and dilate the stricture. The stricture was dilated in a stepwise fashion with dilators (Cook, Bloomington, IN) under the cholangiography, together with or without balloon dilation. An internal/external catheter (Akita Sumitomo Bakelite, Tokyo, Japan) was then placed across the stricture. The dilation procedure was performed during a period of 1-3 weeks with 1-4 sessions for each patient. Biliary stones, if present, were removed by using a basket or were pushed through the bilioenteric anastomosis. The final internal/external catheter was selected according to the grade and condition of the biliary stricture, and then cut at the skin level, capped on, and left in place for internal biliary drainage. Routinely, patients were discharged and returned on an outpatient basis for follow-up cholangiography and biliary catheter exchange at 3- to 4-month intervals as indicated. A patient's treatment was considered to be complete at the time all biliary catheters were removed. The duration of treatment was defined as the time from the initial percutaneous procedure until catheter removal.

#### Surgical management

The surgical management was indicated for the patients whose percutaneous treatment resulted in failure. The surgical repair consisted of a wide hilar Roux-en-Y hepaticojejunostomy in all patients. After the identification and mobilization of the proximal hepatic duct, the strictured ductal tissue was resected back to the normal duct in order to obtain a healthy bile duct (nonscarred, noninflamed,

nonischemic) for a high-quality bilioenteric anastomosis. A Roux-en Y jejunal limb, approximately 40 cm in length, was prepared in a retrocolic position for the tension-free anastomosis. The hepaticojejunostomies were performed routinely at the hepatic hilar in a wide opening, by using a single layer of interrupted absorbable 4-0 sutures. Individual anastomoses were performed in the cases involving more than one major duct.

## Follow-up study

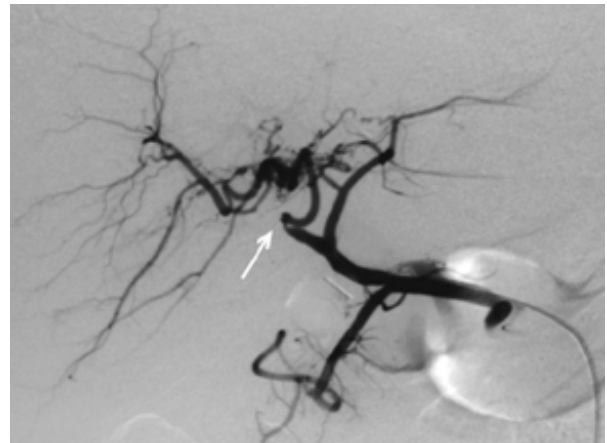
After definitive treatment, a follow-up was obtained in all patients as outpatients at this hospital. The patient's status was considered as successful if there were no symptoms or transitory mild symptoms related to biliary tract disease, requiring neither invasive radiologic nor surgical treatment, were present. The patients were considered to be treatment failures when an invasive radiologic or surgical management was necessary to treat any ongoing symptoms or stricture recurrence.

## Results

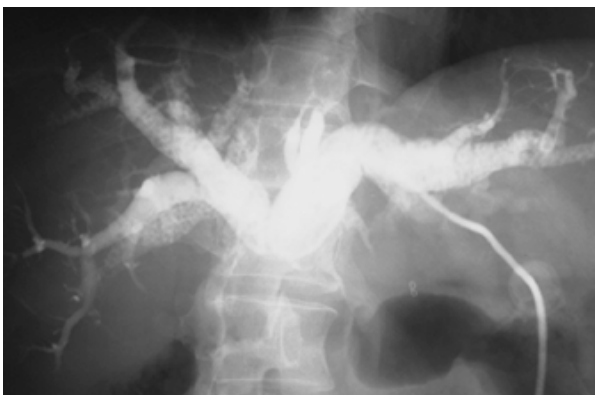All patients were initially managed with a PTBD and the placement of a transhepatic catheter to control ongoing cholangitis or to decompress biliary obstruction, or both, and to define the proximal bile duct anatomy. The PTBD was performed via the left side of the liver in 8 patients, the right side in 5, and both sides in 6.

At the initial cholangiography or during the subsequent sessions, the passage of neither a guide wire nor the contrast material through the stricture to the distal bile duct or the anastomosed intestinal tract was recognized in 5 patients due to tight strictures (Figure 1). All of these cases had been referred from outside hospitals after presenting with biliary strictures secondary to bile duct injuries during a laparoscopic cholecystectomy in 3 and an open cholecystectomy in 2. Subsequently, an endoscopic approach was employed for these

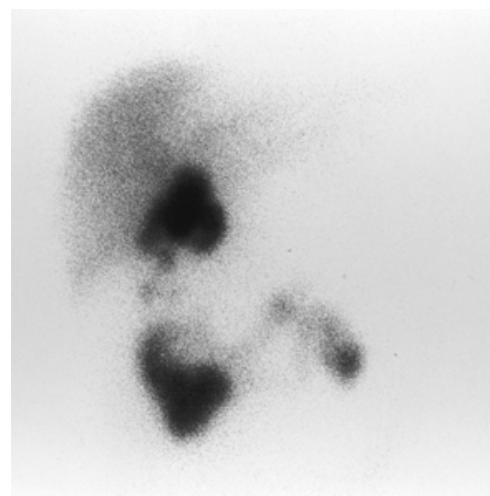
patients, however, these attempts failed. They were therefore prepared for surgical management by means of a wide hilar hepaticojejunostomy. The remaining 14 patients underwent a percutaneous dilation of the strictures with an internal/external biliary drainage catheter. Of these, 4 patients with a hepaticojejunostomy finally required a surgical repair because of recurrent stricture in one and severe cholestasis presenting with recurrent cholangitis in 3. In the former, a hepaticojejunostomy for a bile duct injury during a laparoscopic cholecystectomy resulted in a recurrent anastomotic stricture despite repeated percutaneous treatment for 9 years. In this patient, moreover, injury to the right hepatic artery was discovered 8 years after the initial operation (Figure 2) and a delayed bile excretion in the right liver was prominent on the hepatobiliary scintigraphy with Tc-99m Sn-N-pyridoxyl-5-methyltryptophan (99mTc-PMT) (Figure 3). A right hepatectomy along with a left sided hepaticojejunostomy was necessary for this patient, and a histological examination of the



**Figure 2.** Selective hepatic arteriography demonstrates a right hepatic arterial obstruction (arrow). The right anterior and posterior hepatic arteries communicate with the middle hepatic artery through intrahepatic collateral vessels.



**Figure 1.** A tight anastomotic stricture after a hepaticojejunostomy for an intraoperative bile duct injury. Cholangiography via the initial percutaneous transhepatic catheter shows no passage of contrast material through the stricture. Numerous biliary stones are seen in the intrahepatic bile ducts.



**Figure 3.** Hepatobiliary scintigraphy with Tc-99m Sn-N-pyridoxyl-5-methyltryptophan (99mTc-PMT) demonstrates residual activity in the right hepatic lobe 120 min after the injection of the tracer.

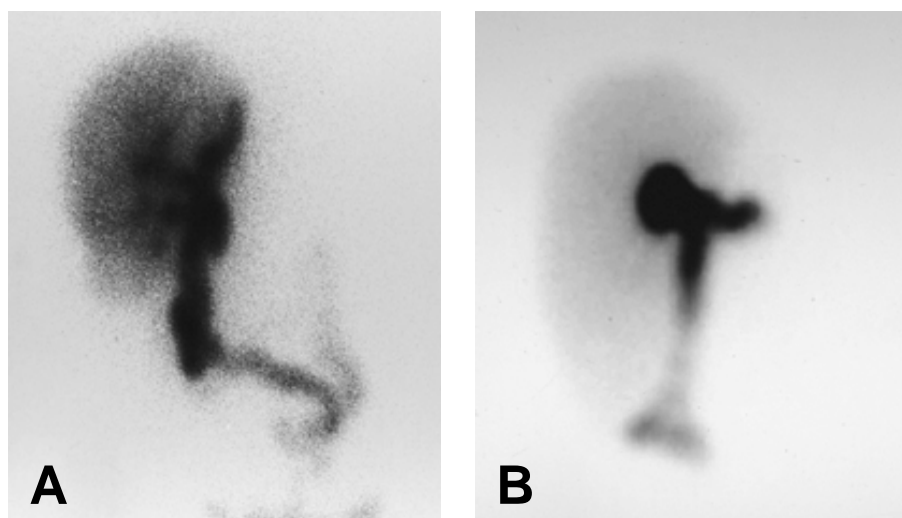
resected liver revealed evidence of periportal and periductal fibrosis. In the latter, a delayed hepatic clearance and stagnancy of the tracer in the proximal jejunal loop were demonstrated on the hepatobiliary scintigraphy even after a completion of percutaneous stricture dilation, thus suggesting a functional disorder of the proximal jejunal loop for a Roux-en Y hepaticojejunostomy. Following the surgical removal of the jejunal loop, a wide hilar hepaticojejunostomy with a newly created Roux-en Y limb was performed in these patients, and resulted in a normal hepatic clearance and a normal bile transit through the jejunal loop on the postoperative hepatobiliary scintigraphy (Figure 4). There were no operative deaths and a successful outcome was achieved in all 9 patients who underwent a definitive surgical repair with a mean postoperative follow-up 6.7 (range 2-12) years.

Percutaneous transhepatic management was accomplished in 10 patients, including a case with a bronchobiliary fistula detected by hepatobiliary scintigraphy.<sup>12</sup> The final internal/external biliary drainage catheter ranged 10- to 16-Fr in size. Balloon dilation was simul-

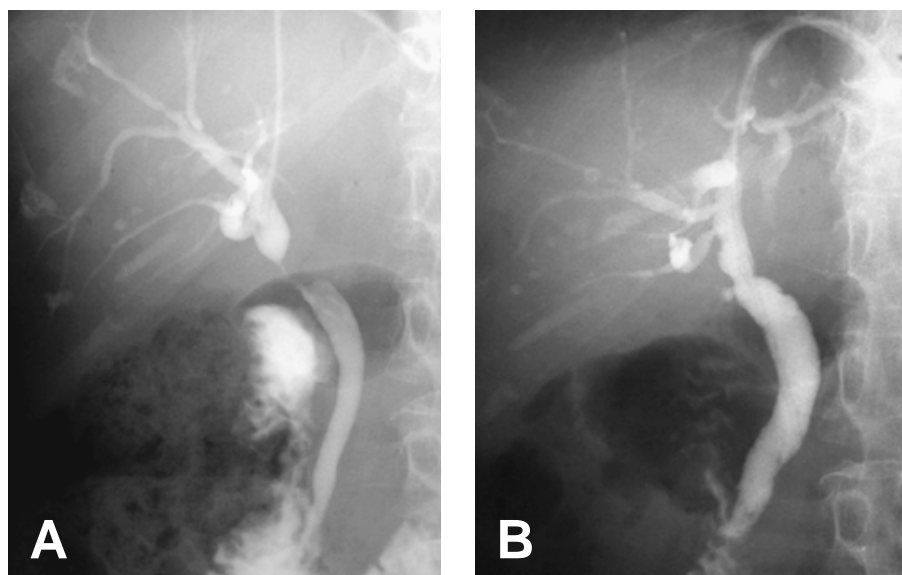
taneously performed in 9 cases. Biliary stones were recognized in 5 patients and they were completely removed using a basket or were pushed through the bilioenteric anastomosis. The lengths of catheter placement were 8, 8, 8, 11, 12, 12, 12, 14, 14, and 30 months with a mean duration of 13.6 months (Figure 5). During the catheter treatment, a high quality of life was reported in all patients. After the removal of percutaneous catheters, neither recurrence of the biliary stricture nor stricture-related clinical symptoms requiring invasive radiologic or surgical treatment were found with a mean follow-up of 5.2 (range 1-12) years.

## Discussion

Injuries to the bile ducts and subsequent biliary strictures associated with laparoscopic cholecystectomies are serious and potentially life-threatening complications and the incidence of bile duct inju-



**Figure 4.** **A.** Hepatobiliary scintigraphy shows a delayed hepatic clearance and a residual activity of the tracer in the proximal jejunal loop (100 min after injection of the tracer). **B.** Hepatobiliary scintigraphy after a definitive surgery in the same patient as in Figure 4A demonstrates a normal hepatic clearance and a normal bile transit through the newly created jejunal loop (80 min after injection of the tracer).



**Figure 5.** **A.** Bile duct stricture after a primary suture for a bile duct injury during a laparoscopic cholecystectomy. The passage of contrast material through the stricture was possible. **B.** A cholangiogram just before the removal of percutaneous transhepatic catheter. The stricture is well resolved. In this patient, a 16-Fr percutaneous transhepatic catheter was placed for 12 months.

ries during laparoscopic cholecystectomy remains constant even after overcoming the "learning curve". In addition, biliary injuries sustained during laparoscopic cholecystectomies tend to be more complex, often involving major vessels, in comparison to the open procedure.<sup>1,13</sup> In the present series of 19 patients with postoperative biliary strictures, 6 cases were associated with bile duct injuries during a laparoscopic cholecystectomy and one of them suffered a concomitant right hepatic arterial occlusion. This resulted in a recurrent stricture at the site of hepaticojejunostomy and then required a right hepatectomy 9 years after the initial operation to resolve. There are some reports of such patients with complex injuries during a laparoscopic cholecystectomy, requiring a hepatectomy<sup>14-16</sup> and even liver transplantation.<sup>17,18</sup> Schmidt *et al.*<sup>19</sup> demonstrated that 11 of the 54 patients (20.4%) with bile duct injuries during a laparoscopic cholecystectomy had a concomitant right hepatic arterial injury and the outcome of the bile duct reconstruction was worse in these patients. Bachellier *et al.*<sup>20</sup> also stated that a concomitant hepatic arterial injury is a crucial risk factor for postoperative liver abscess, stenosis of a hepaticojejunostomy, and stricture in the intrahepatic biliary tree in the long-term outcome. An assessment for concomitant vascular injuries is therefore essential in managing the patients with major bile duct injuries. Hepatic arterial revascularization may therefore be an ideal approach for early recognized injuries.<sup>19,20</sup>

Fibrotic stricture at the bilioenteric anastomosis is another leading cause of postoperative biliary strictures.<sup>7</sup> In the present study, biliary stricture at the site of the bilioenteric anastomosis occurred in 10 of the 19 patients. Following percutaneous management, 3 of these patients required a surgical repair because of bile stasis secondary to a functional disorder of the previous jejunal loop. To elucidate the pathogenesis of recurrent cholangitis in these patients and to select the optimal treatment strategy, hepatobiliary scintigraphy was useful since it provided helpful information indicating a so-called "blind-loop syndrome" i.e., a delayed hepatic clearance and a prominent stasis of 99mTc in the proximal jejunum loop. In this study, we conducted hepatobiliary scintigraphy on 6 patients who presented with recurrent cholangitis even after the removal of biliary stricture and the presence of a unilobar delay of bile excretion in the liver and a bronchobiliary fistula<sup>12</sup> was observed, as well as the presence of blind-loop syndrome. The efficacy of hepatobiliary scintigraphy in the assessment of the surgical outcome regarding biliary flow after bilioenteric anastomosis has been reported,<sup>21-23</sup> and the surgical removal of the previous jejunal loop and the creation of a new Roux-en Y limb for a wide hilar hepaticojejunostomy resulted in a favorable outcome. The possibility of a functional obstacle responsible for recurrent cholangitis<sup>24</sup> should therefore be considered when no mechanical obstructions are observed after percutaneous treatment, and hepatobiliary scintigraphy is therefore recommended for the assessment of such a disorder because it is noninvasive and can visualize the functional efficacy of bile secretion and excretion after biliary-enteric anastomosis.

An alternative to surgical management is an interventional approach including percutaneous and endoscopic techniques. The principal advantage of interventional treatment is that repetitive stepwise

larger size catheters can achieve an adequate dilation of biliary stricture in individual patients. In the current series, all patients were initially managed with PTBD and the placement of a transhepatic catheter, irrespective of the type and the degree of biliary stricture, because the use of a percutaneous catheter not only allowed us to effectively control the ongoing cholangitis while also managing biliary stricture, but it also enabled us to elucidate the anatomy of the injury. Although 9 patients who had a tight stricture, a complex injury, or a blind-loop syndrome required surgical repair, the remaining 10 patients were successfully managed using the percutaneous approach. The outcome of percutaneous management for postoperative biliary strictures tends to vary,<sup>25-27</sup> however, the percutaneous approach should be the first step in management because it is effective in selected cases and the importance of preoperative delineation of the biliary anatomy has been clearly demonstrated.<sup>28</sup> One controversial aspect about percutaneous treatment is the duration of percutaneous catheter maintenance necessary to obtain an adequate dilation of biliary strictures. Kim *et al.*<sup>25</sup> recommended catheter maintenance of more than 6 months. Kocher *et al.*<sup>26</sup> reported that the mean duration of percutaneous catheter treatment was 7.5 months with a 3 years primary clinical success rate of 77%. Based on the present results, it was thought that the percutaneous catheter should be maintained for longer than 8 months. Such a long-term percutaneous treatment is feasible because the majority of patients can be followed up as outpatients with a good quality of life. Although an endoscopic approach resulted in treatment failure in our series, the successful endoscopic treatment of postoperative biliary stricture has been reported in selected patients.<sup>29-32</sup>

In conclusion, postoperative biliary stricture requires multidisciplinary approach for their resolution. A complete workup of the patient should be done to plan an optimal treatment strategy. The percutaneous transhepatic approach is the first step in management to delineate the biliary anatomy and to relieve ongoing cholangitis and stricture. A surgical repair should be considered for cases with a tight stricture, a complex injury, or a functional disorder of the previous jejunal loop for bilioenterostomy. Hepatobiliary scintigraphy may provide helpful information to determine the precise condition of biliary flow and thereby take appropriate subsequent measures.

## References

1. Strasberg SM, Hertl M, Soper NJ. An analysis of the problem of biliary injury during laparoscopic cholecystectomy. *J Am Coll Surg* 180: 101-125, 1995
2. Roslyn JJ, Binns GS, Hughes EF, Saunders-Kirkwood K, Zinner MJ, Cates JA. Open cholecystectomy. A contemporary analysis of 42,474 patients. *Ann Surg* 218: 129-137, 1993
3. Fletcher DR, Hobbs MS, Tan P. et al. Complications of cholecystectomy: risks of the laparoscopic approach and protective effects of operative cholangiography: a population-based study. *Ann Surg* 229: 449-457, 1999
4. Nuzzo G, Giuliani F, Giovannini I. et al. Bile duct injury during laparoscopic cholecystectomy: results of an Italian national survey on 56 591 cholecystectomies. *Arch Surg* 140: 986-992, 2005
5. MacFadyen BV Jr, Vecchio R, Ricardo AE, Mathis CR. Bile duct injury after laparoscopic cholecystectomy. The United States experience. *Surg Endosc* 12: 315-321, 1998
6. Deziel DJ, Millikan KW, Economou SG, Doolas A, Ko ST, Airan MC. Complications of laparoscopic cholecystectomy: a national survey of 4,292 hospitals and an

- analysis of 77,604 cases. *Am J Surg* 165: 9-14, 1993
7. House MG, Cameron JL, Schulick RD. et al. Incidence and outcome of biliary strictures after pancreaticoduodenectomy. *Ann Surg* 243: 571-576, 2006
  8. Blumgart LH, Kelley CJ, Benjamin IS. Benign bile duct stricture following cholecystectomy: critical factors in management. *Br J Surg* 71: 836-843, 1984
  9. Schweizer WP, Matthews JB, Baer HU. et al. Combined surgical and interventional radiological approach for complex benign biliary tract obstruction. *Br J Surg* 78: 559-563, 1991
  10. Tocchi A, Costa G, Lepre L, Liotta G, Mazzoni G, Sita A. The long-term outcome of hepaticojejunostomy in the treatment of benign bile duct strictures. *Ann Surg* 224: 162-167, 1996
  11. Bismuth H. Postoperative stricture of the biliary tract. In: The biliary tract. *Clinical surgery international*, vol 5. (Blumgart LH, eds.: Churchill Livingstone, Edinburgh). pp. 209-18, 1982.
  12. Adachi T, Tajima Y, Kuroki T. et al. Demonstration of a biliobronchial fistula with a hepatoinodiacetic acid scan. *Am J Surg* 191: 794-796, 2006
  13. Chaudhary A, Manisegran M, Chandra A, Agarwal AK, Sachdev AK. How do bile duct injuries sustained during laparoscopic cholecystectomy differ from those during open cholecystectomy? *J Laparoendosc Adv Surg Tech A* 11: 187-191, 2001
  14. Uenishi T, Hirohashi K, Tanaka H, Fujio N, Kubo S, Kinoshita H. Right hepatic lobectomy for recurrent cholangitis after bile duct and hepatic artery injury during laparoscopic cholecystectomy: report of a case. *Hepatogastroenterology* 46: 2296-2298, 1999
  15. Wong MD, Lucas CE. Liver infarction after laparoscopic cholecystectomy injury to the right hepatic artery and portal vein. *Am Surg* 67: 410-1, 2001
  16. Kayaalp C, Nessar G, Kaman S, Akoglu M. Right liver necrosis: complication of laparoscopic cholecystectomy. *Hepatogastroenterology* 48: 1727-1729, 2001
  17. Schmidt SC, Langrehr JM, Raakow R, Klupp J, Steinmuller T, Neuhaus P. Right hepatic lobectomy for recurrent cholangitis after combined bile duct and right hepatic artery injury during laparoscopic cholecystectomy: a report of two cases. *Langenbecks Arch Surg* 387: 183-187, 2002
  18. Bacha EA, Stieber AC, Galloway JR, Hunter JG. Non-biliary complication of laparoscopic cholecystectomy. *Lancet* 344: 896-897, 1994
  19. Robertson AJ, Rela M, Karani J, Steger AC, Benjamin IS, Heaton ND. Laparoscopic cholecystectomy injury: an unusual indication for liver transplantation. *Transpl Int* 11: 449-451, 1998
  20. Schmidt SC, Settmacher U, Langrehr JM, Neuhaus P. Management and outcome of patients with combined bile duct and hepatic arterial injuries after laparoscopic cholecystectomy. *Surgery* 135: 613-618, 2004
  21. Bachellier P, Nakano H, Weber JC. et al. Surgical repair after bile duct and vascular injuries during laparoscopic cholecystectomy: when and how? *World J Surg* 25: 1335-1345, 2001
  22. Sarkari A, Gambhir S, Kumar A, Saxena R, Kapoor VK, Sikora SS. Evaluation of bilioenteric anastomosis using quantitative hepatobiliary scintigraphy. *Hepatogastroenterology* 51: 1267-1270, 2004
  23. Kim JS, Moon DH, Lee SG. et al. Hepatobiliary scintigraphy in the assessment of biliary obstruction after hepatic resection with biliary-enteric anastomosis. *Eur J Nucl Med* 27: 170-175, 2000
  24. Nakano H, Kumada K, Takekuma Y. et al. Perioperative hepatic functional risk assessed with technetium-99m diethylenetriamine pentaacetic acid-galactosyl human serum albumin liver scintigraphy in patients undergoing pancreaticoduodenectomy complicated by obstructive jaundice. *Int J Pancreatol* 25: 3-9, 1999
  25. Bismuth H, Franco D, Corlette MB, Hepp J. Long term results of Roux-en-Y hepaticojejunostomy. *Surg Gynecol Obstet* 146: 161-167, 1978
  26. Kim JH, Lee SK, Kim MH. et al. Percutaneous transhepatic cholangioscopic treatment of patients with benign bilio-enteric anastomotic strictures. *Gastrointest Endosc* 58: 733-738, 2003
  27. Kocher M, Cerna M, Havlik R, Kral V, Gryga A, Duda M. Percutaneous treatment of benign bile duct strictures. *Eur J Radiol* 62: 170-174, 2007
  28. Misra S, Melton GB, Geschwind JF, Venbrux AC, Cameron JL, Lillemoe KD. Percutaneous management of bile duct strictures and injuries associated with laparoscopic cholecystectomy: a decade of experience. *J Am Coll Surg* 198: 218-226, 2004.
  29. Stewart L, Way LW. Bile duct injuries during laparoscopic cholecystectomy. Factors that influence the results of treatment. *Arch Surg* 130: 1123-1128, 1995
  30. Kapoor VK. Bile duct injury repair: when? what? who? *J Hepatobiliary Pancreat Surg* 14: 476-479, 2007
  31. Costamagna G, Familiari P, Tringali A, Mutignani M. Multidisciplinary approach to benign biliary strictures. *Curr Treat Options Gastroenterol* 10: 90-101, 2007.
  32. von Renteln D, Riecken B, Ulmer M, Caca K. Biliary stenting and successful intentional stent retrieval after 6 months in a benign stricture following hepaticojejunostomy. *Endoscopy* 39: Suppl 1,335-336, 2007
  33. Vandenbroucke F, Plasse M, Dagenais M, Lapointe R, Letourneau R, Roy A. Treatment of post liver transplantation bile duct stricture with self-expandable metallic stent. *HPB* 8: 202-205, 2006.