

On the Human Obliquus Abdominis Externus Profundus

Ryosuke MIYAUCHI, Kazushige KURIHARA
and Gen TACHIBANA

*Department of Anatomy, Medical College of Oita,
Oita 879-56, Japan*

Received for publication, February 14, 1986

ABSTRACT

The Obliquus abdominis externus profundus was found to be present in eleven cases among 50 sides examined in Japanese adult cadavers (frequency of occurrence 22%).

This muscle originated at a level ranging from the fifth to seventh rib either by a single slip from one of these ribs (nine cases) or by two slips from two ribs (two cases), and ran medialwards almost horizontally to insert into the anterior lamina of the sheath of the Rectus abdominis. There was a fusion between this muscle and the Obliquus externus abdominis in four of the eleven cases. This muscle was supplied from its inner surface by the Ramus muscularis externus from the intercostal nerve of the corresponding segment.

The identification, origin and insertion, nerve supply, and frequency of occurrence of this muscle were discussed.

Key words : gross anatomy, Obliquus abdominis externus profundus, Obliquus externus abdominis, lateral cutaneous branch of the intercostal nerve, Ramus muscularis externus of the intercostal nerve.

INTRODUCTION

The presence of an anomalous muscle, located between the Obliquus externus abdominis and internus abdominis, has been reported in man by many investigators. These reports, excepting those of EISLER (1912) and KODAMA (1986), do not include any remarkable description about the nerve supply to this muscle. Thus, most reports are not

clear with regard to whether this muscle should be considered to be the *Obliquus abdominis externus profundus* or to be an aberrant bundle of the *Obliquus externus abdominis*.

Gross anatomical examinations were therefore made by the present authors on the anterolateral muscles of the abdominal wall in a comparatively large number of human adult cadavers in order to determine the morphology and also the frequency of occurrence of the *Obliquus abdominis externus profundus*.

MATERIAL AND METHOD

Examinations were made on the anterolateral muscles of the abdominal wall on both sides of 25 human adult cadavers, which had been available to students of the Medical College of Oita for anatomical dissection studies during the 1982 academic year.

Inspection was first made on the nerve supply to the *Obliquus externus abdominis*. Next, each slip of the *Obliquus externus abdominis* was separated from the ribs. At the same time, each *Intercostalis externus* was severed along the lower edge of the respective ribs and reflected downwards. The *Ramus muscularis externus* (according to the nomenclature by FUJITA, 1963) of the intercostal nerve which passes between the *Intercostalis externus* and *internus* was traced distally in order to clear the muscle supplied by it as well as to examine the fasciculi of the dorsal (inner) layer of the *Obliquus externus abdominis*.

The inspections were made using magnifying lenses with an illuminating attachment, and stereomicroscopic examinations were made as necessary.

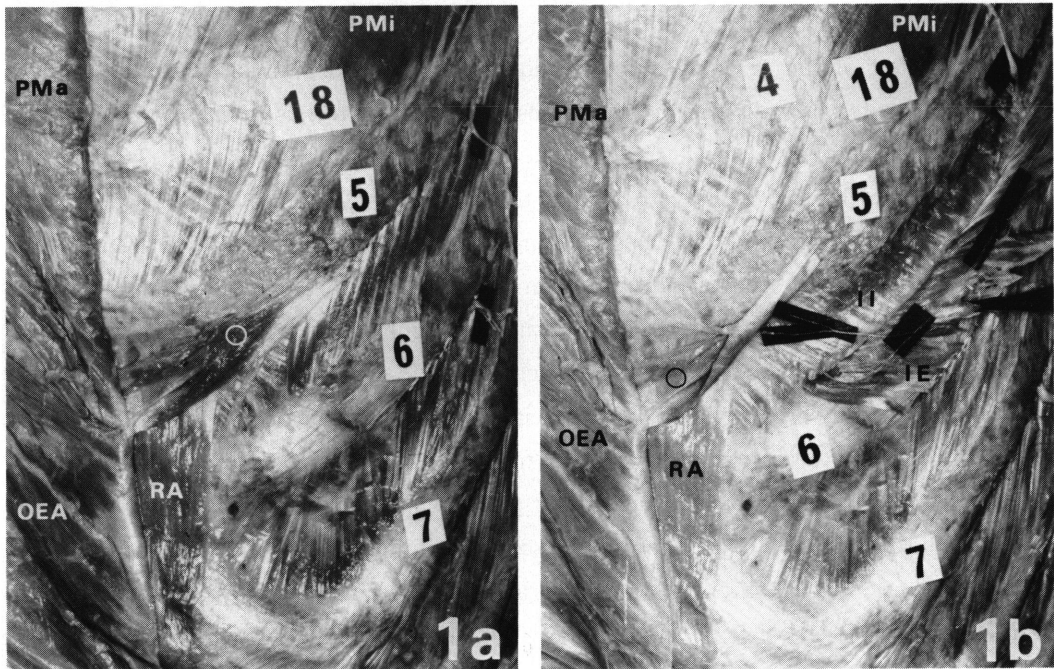
FINDINGS

The following muscle and fasciculus were considered to be the *Obliquus abdominis externus profundus* based upon the reports by EISLER (1912), MYSBERG (1917) and NISHI (1938) concerning its intrinsic nature. That is, the muscle present independently on the dorsal side of the *Obliquus externus abdominis* and supplied by *Ramus muscularis externus* of the intercostal nerve and the dorsal fasciculus of the *Obliquus externus abdominis* that is supplied by the same nerve branch (the identification of this muscle will be described in detail in the Discussion section).

Among the 50 sides of the 25 cadavers examined, this muscle was found on 11 sides of eight cadavers (22%). These 11 cases of this muscle were classified by the number of

Table : Number of Slips of Origin of the Obliquus Abdominis Externus Profundus and the Rib from Which the Slip Takes Origin

Number of Slips (cases)	Rib of Origin		
	5th rib	6th rib	7th rib
One (9 cases)	2	6	1
Two (2 cases)	2		



Figs. 1a and b. Anterolateral view. The locations of the lateral cutaneous branches and the Ramus muscularis externus have been indicated with the small pieces of black paper. a: The Pectoralis major and Obliquus externus abdominis have been reflected medialwards. b: The Obliquus abdominis externus profundus and the fifth Intercostalis externus have been reflected medialwards and downwards respectively so as to expose the Ramus muscularis externus of the fifth intercostal nerve.

slips of origin and the location of their attachment (*Table*).

1. Obliquus Abdominis Externus Profundus Originating from a Rib by a Single Slip.

In nine of the 11 cases, this muscle originated by a single slip from one of the ribs ranging from the fifth to seventh rib (*Table*).

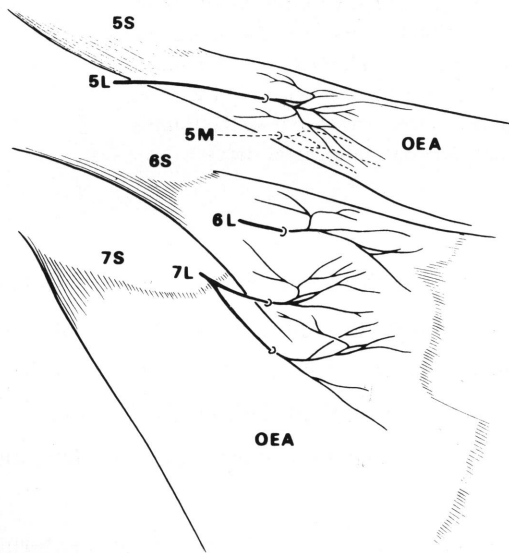
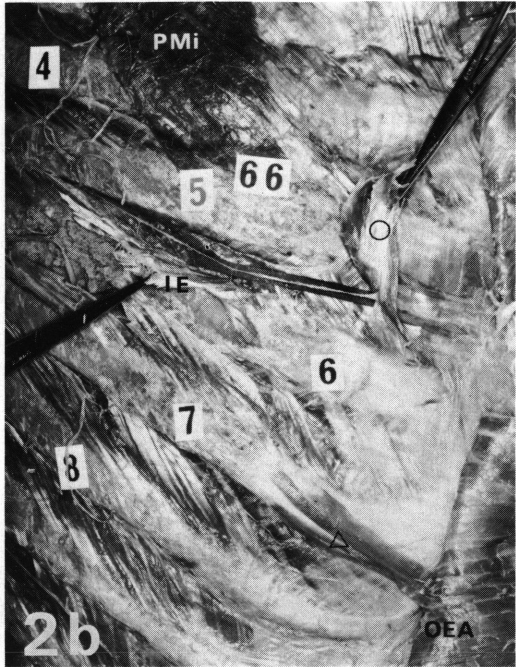
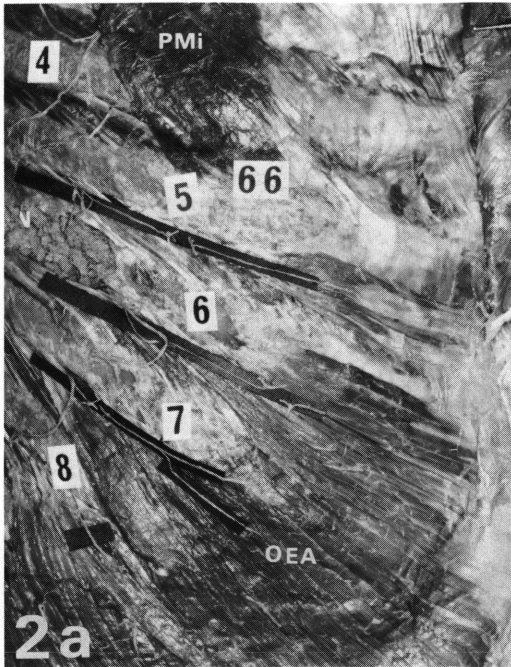
(1) Two cases with origin from the fifth rib :

In one case, this muscle found on left side had aponeurotic origin from the fifth rib at almost the same location as the origin of the Obliquus externus abdominis. It had a flat, membrane-like form, and it gradually increased in width as it ran horizontally medialwards to the aponeurotic insertion into the anterior lamina of the sheath of the Rectus abdominis. The lateral portion of this muscle was covered ventrally by the Obliquus externus abdominis. A small amount of connective tissue was present between this muscle and the Obliquus externus abdominis. The direction of the course of this muscle differed considerably from that of the fasciculi of the Obliquus externus abdominis. This muscle was supplied from its inner surface by the Ramus muscularis externus of the fifth intercostal nerve (*Figs. 1a and b*).

On the right side of the other case, the slip of the Obliquus externus abdominis arising from the fifth rib was supplied from its outer surface by the lateral cutaneous branch of the fifth intercostal nerve and, in addition, its inner layer (dorsal layer) was innervated from the inner surface by the Ramus muscularis externus of the same nerve. The fasciculus of the inner layer (dorsal layer) of this slip was considered to be the Obliquus abdominis externus profundus. Therefore, it was assumed that the Obliquus abdominis externus profundus arising from the fifth rib to insert into the anterior lamina of the sheath of the Rectus abdominis had become fused to the dorsal surface (inner surface) of the Obliquus externus abdominis. Stereomicroscopic examination was made on the intramuscular distribution of the lateral cutaneous branch of the fifth intercostal nerve and of the Ramus muscularis externus of the same nerve. Although there was overlapping in innervation of this slip by these two nerve branches from both surfaces, there was no anastomosis between two nerve branches (*Figs. 2a-c*).

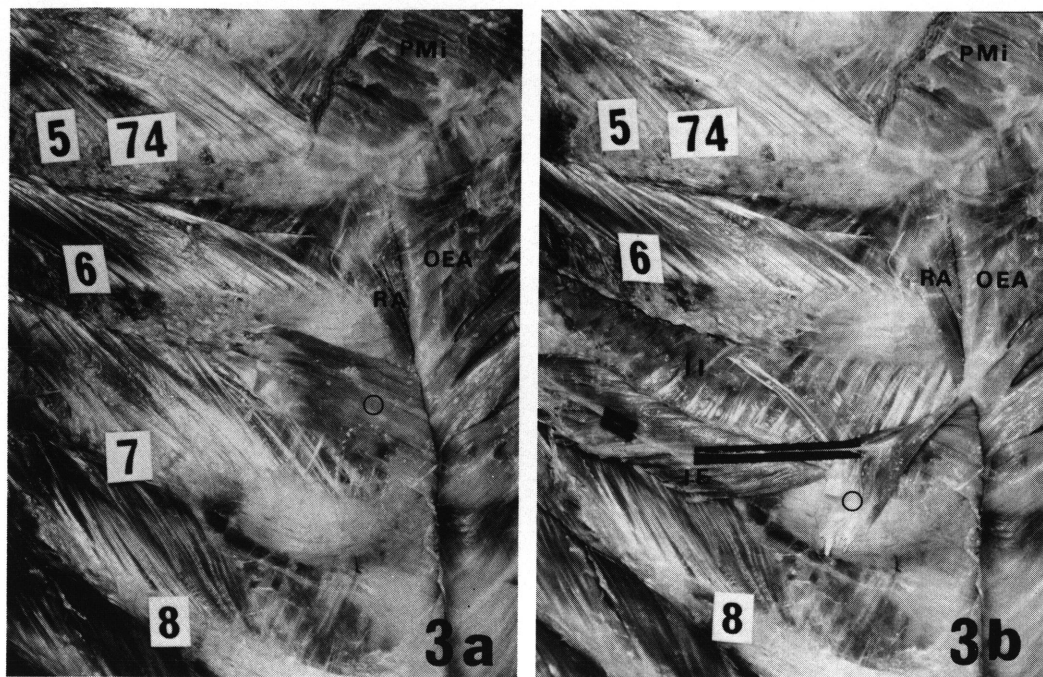
(2) Six cases with origin from the sixth rib :

Six cases of this muscle were noted on the dorsal side of the Obliquus externus abdominis. Although they varied in width, they were very similar in their condition of origin, insertion, course, topographical relationship to other adjacent muscles, and nerve



2c

Figs. 2a-c. Anterolateral view. The locations of the lateral cutaneous branches and the Ramus muscularis externus have been indicated with the small pieces of black paper. **b:** The Obliquus externus abdominis having been reflected medialwards, the fifth Intercostalis externus has been reflected downwards to expose the Ramus muscularis externus of the fifth intercostal nerve. **c:** Intramuscular distribution of the nerves.



Figs. 3a and b. Anterolateral view. The location of the Ramus muscularis externus has been indicated with the small pieces of black paper. a: The Obliquus externus abdominis has been reflected medialwards. b: The Obliquus abdominis externus profundus and the sixth Intercostalis externus have been reflected downwards so as to expose the Ramus muscularis externus of the sixth intercostal nerve.

supply.

This muscle, which arose aponeurotically from the sixth rib at a location slightly medial to the origin of the Obliquus externus abdominis, gradually increased in width as it ran medio-downwards in the same direction as the fasciculi of the Obliquus externus abdominis, and inserted into the anterior lamina of the sheath of the Rectus abdominis. A small amount of connective tissue was present between this muscle and the Obliquus externus abdominis.

This muscle was supplied from its inner surface by the Ramus muscularis externus of the sixth intercostal nerve (*Figs. 3a and b*).

(3) A case with origin from the seventh rib :

On the right side, the outer layer of the slip of the Obliquus externus abdominis arising from the seventh rib was supplied from the outer surface by lateral cutaneous

branches of both the seventh and eighth intercostal nerves, and further its inner layer was innervated from the inner surface by Ramus muscularis externus of the seventh. The fasciculus of the inner layer of this slip was considered to be the Obliquus abdominis externus profundus.

Stereomicroscopically overlapping was found in the areas supplied by the lateral cutaneous branches and by the Ramus muscularis externus, but no anastomosis was seen between these nerve branches (*Figs. 4a-c*).

2. Two Cases Originating from Two Ribs by Two Slips

The muscle was found to arise by two slips from the fifth and sixth ribs on one side in two cases (*Table*).

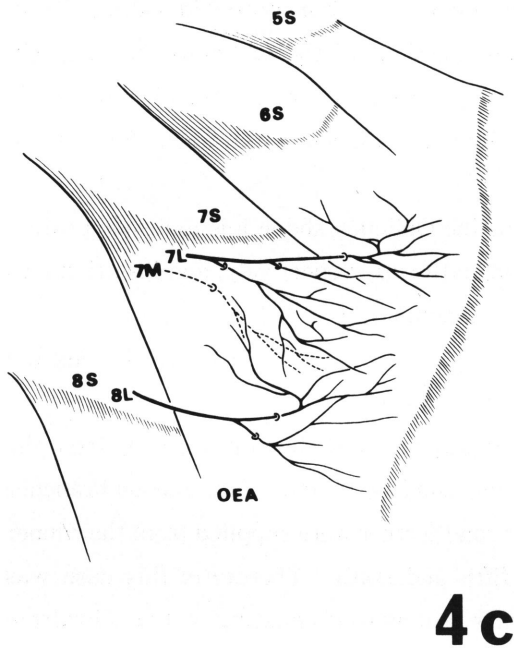
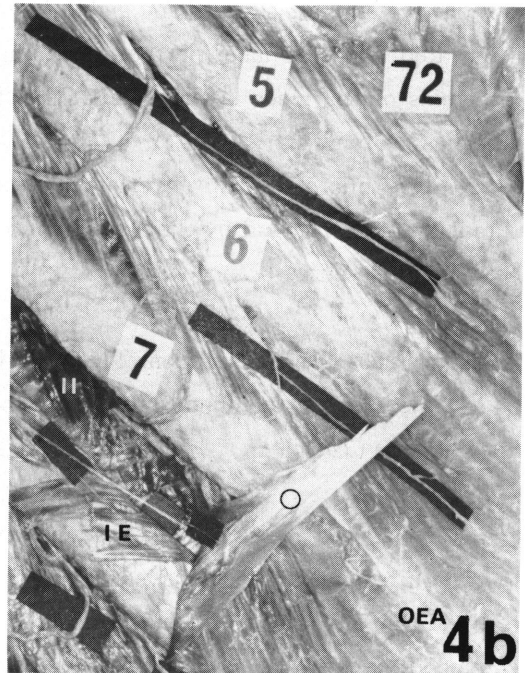
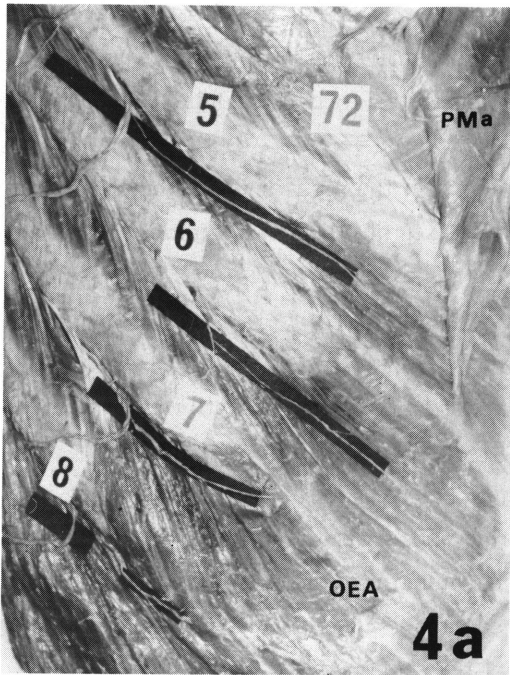
In one case, the slip of the Obliquus externus abdominis originating from the fifth rib received from its outer surface a slender branch coming from the lateral cutaneous branch of the fifth intercostal nerve and further received from its inner surface the terminal twig coming from the Ramus muscularis externus of the same nerve.

In addition, an independent membrane-like muscle arising from the sixth rib was found on the dorsal side of the Obliquus externus abdominis. It increased in width as it ran medio-downwards in the same direction as the fasciculi of the Obliquus externus abdominis, and inserted into the anterior lamina of the sheath of the Rectus abdominis. It was supplied from the inner surface by the Ramus muscularis externus of the sixth intercostal nerve.

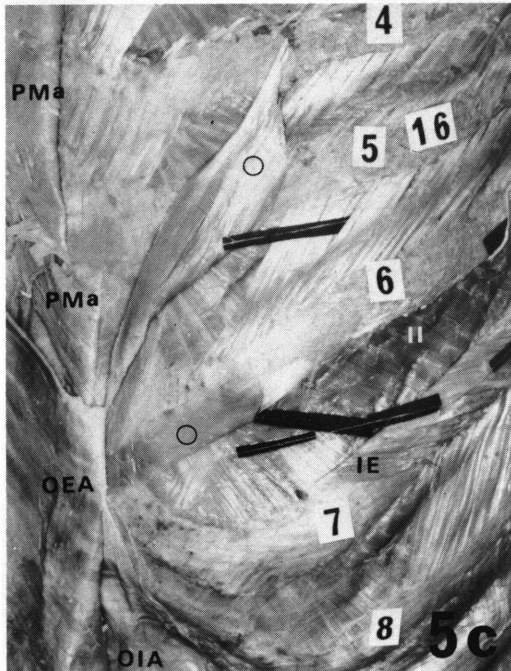
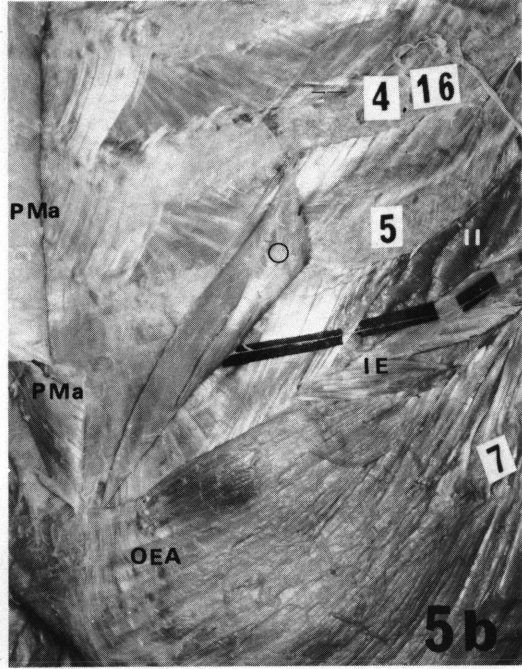
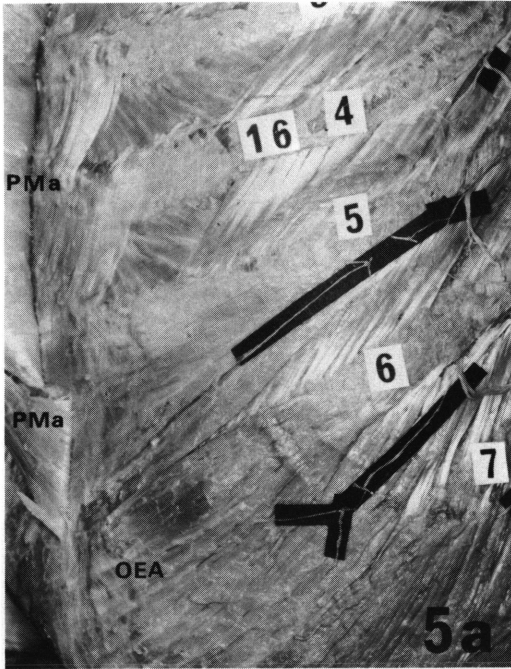
Therefore, this case was considered to be the Obliquus abdominis externus profundus with two originating slips from the fifth and sixth ribs, respectively, and insertion into the anterior lamina of the sheath of the Rectus abdominis.

The description and illustration of the stereomicroscopic findings will be omitted since they were very similar to the results mentioned earlier (*Figs. 5a-c*).

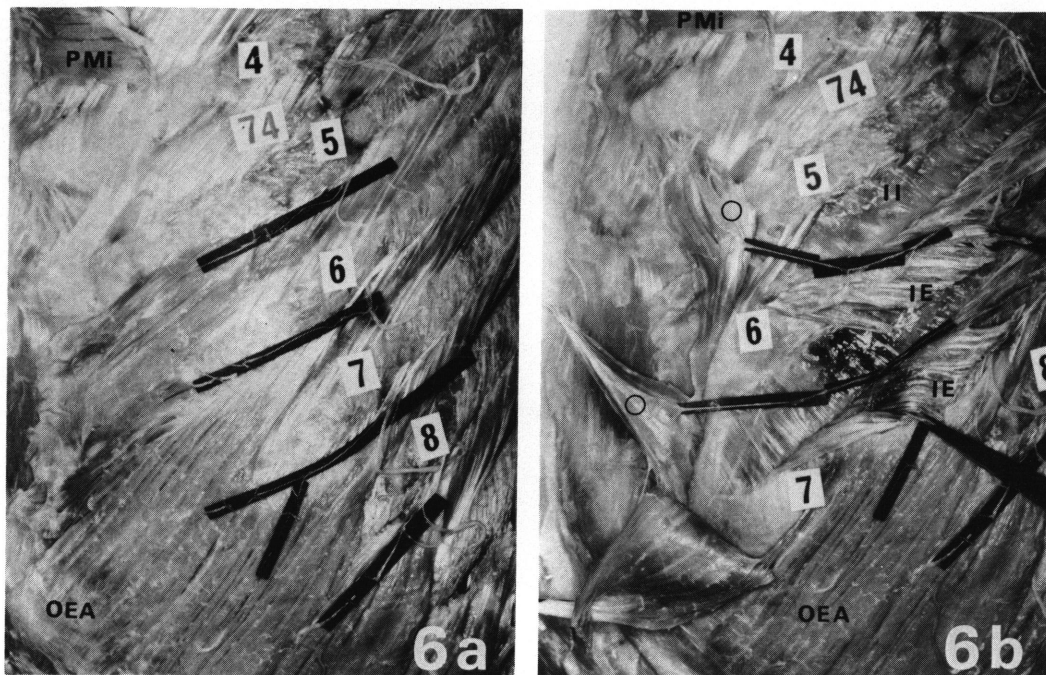
In the other case, the two slips of the Obliquus externus abdominis arising from the fifth and sixth ribs were supplied from their outer surface by lateral cutaneous branches of the fifth, sixth and seventh intercostal nerves, and further were supplied from their inner surface by Rami musculares interni of the fifth and sixth. Therefore, this case was considered to be the Obliquus abdominis externus profundus originating by two slips from the fifth and sixth ribs and inserting into the anterior lamina of the sheath of the Rectus abdominis, and moreover it was considered that this muscle had become fused to the inner surface (dorsal surface) of the Obliquus externus abdominis.



Figs. 4a-c. Anterolateral view. The locations of the lateral cutaneous branches and the Ramus muscularis externus have been indicated with the small pieces of black paper. a: The Pectoralis major has been reflected medialwards. b: The slip of the Obliquus externus abdominis arising from the seventh rib and the seventh Intercostalis externus have been reflected medialwards and downwards respectively so as to expose the Ramus muscularis externus of the seventh intercostal nerve. c: Intramuscular distribution of the nerves.



Figs. 5a-c. Anterolateral view. The locations of the lateral cutaneous branches and the Ramus muscularis externus have been indicated with the small pieces of black paper. a: The Pectoralis major has been reflected medialwards. b: The slip of the Obliquus externus abdominis originating from the fifth rib and the fifth Intercostalis externus have been reflected medialwards and downwards respectively to expose the Ramus muscularis externus of the fifth intercostal nerve. c: The Obliquus externus abdominis having been reflected medialwards, the sixth Intercostalis externus has been downwards to expose the Ramus muscularis externus of the sixth intercostal nerve.



Figs. 6a and b. Anterolateral view. The locations of the lateral cutaneous branches and the Rami musculares externi have been indicated with the small pieces of black paper. b: The upper slips of the Obliquus externus abdominis having been reflected medialwards, the fifth and sixth Intercostales externi have been downwards to expose the Rami musculares externi.

The description and illustration of the stereomicroscopic findings will be omitted since they were very similar to the results described earlier (*Figs. 6a and b*).

DISCUSSION

1. Identification of the Obliquus Abdominis Externus Profundus

EISLER (1912) discussed the differentiation of the ventral trunk muscles from the standpoint of phylogeny and nerve supply, and reported that the "Obliq. ext. + Serrati postt. + Supracostales (Var.)" of man was homologous with the "Schicht des Obliq. ext. superficialis trunci" of amphibian (*urodela*) while the "Intercost. ext. + tiefe Zacke des Obliq. ext. abd." of the former was homologous with the "Schicht des Obliq. ext. profun-

dus" of the latter.

MYSBERG (1917) observed a membrane composed of connective tissue between the Obliquus externus abdominis and internus abdominis in primates, and he regarded this membrane (*Membrana abdominis intermedia*: MYSBERG, 1917) as being the retrogressed rudiment of the Obliquus abdominis externus profundus. He further considered the *Membrana abdominis intermedia* and *Intercostales externi* of primates to be homologous with the Obliquus externus profundus (MAURER, 1892 and 1895) of *urodela*.

NISHI (1938) reported that the ventral trunk muscles of mammals were phylogenically directly derived from those of reptiles. He stated that the muscle corresponding to the Obliquus externus profundus of reptiles was present on the mammalian thoracic wall as the *Levator costarum* and *Intercostales externi*, but that on the abdominal wall the corresponding muscle had usually retrogressed and disappeared, and was present only in rare cases as the Obliquus externus profundus.

In view of these earlier reports, it seems that the *Intercostalis externus* is serially homologous with the Obliquus abdominis externus profundus in mammals.

The muscle found by the present authors was innervated from its inner surface by the *Ramus muscularis externus* of the intercostal nerve. The nerve supply to our muscle and its pattern are analogous to those to the *Intercostalis externus*. Thus, from the standpoint of the nerve supply and its pattern, our muscle seems to belong to the same musculature system as the *Intercostalis externus*, and moreover topographically it seems appropriate to consider it to be the Obliquus abdominis externus profundus. Furthermore, that part of the slip of the Obliquus externus abdominis, which was supplied by both the lateral cutaneous branch and *Ramus muscularis externus*, appears to be the result of fusion of the Obliquus abdominis externus profundus to the dorsal surface (inner surface) of the Obliquus externus abdominis.

According to EISLER (1912) it is not rare that there may be found an additional slip (*zweite Zacken am einzelnen Rippen*: EISLER, 1912) arising slightly medial to the origin of one of the slips of the Obliquus externus abdominis from one of the ribs (in the range of the eighth to eleventh rib), and that it is supplied from its inner surface by *Ramus muscularis externus*. He did not give a specific name to this additional slip, but did regard it as being a muscle bundle homologous with the Obliquus abdominis externus profundus. During the study by the present authors, a muscle bundle grossly similar to this additional slip was frequently found (indicated by the triangular mark in *Fig. 2b*). The muscle bundle was supplied not by the *Ramus muscularis externus*, but by the lateral cutaneous branch. Therefore, it should be considered to be an aberrant bundle from the Obliquus externus

abdominis.

Many investigators had previously observed a muscle which was largely independent on the dorsal side of the human Obliquus externus abdominis. However, EISLER (1912), SUGIURA (1935), NAKAYAMA *et al.* (1952), ODAKI (1963), and KODAMA (1986) are the only investigators who described the nerve supply to the muscle.

Odaki encountered a muscle located between the Obliquus externus abdominis and internus abdominis which he called the Obliquus abdominis externus profundus. He mentioned that his muscle was innervated by the eleventh and twelfth intercostal nerves, but it is not clear which branch of the intercostal nerve supplied his muscle so that it is not possible to immediately make any assumption concerning to which muscular system it belongs.

NAKAYAMA *et al.* used the nomenclature of Obliquus abdominis externus profundus for a muscle located independently between the Obliquus externus abdominis and internus abdominis, and innervated by the lateral cutaneous branch. Sugiura also found a muscle which was very similar in its topographical condition and nerve supply, but he regarded it as belonging to the same musculature system as the Obliquus externus abdominis. In view of the nerve supply, the muscle found by NAKAYAMA *et al.* seems to be more appropriately considered to be an aberrant bundle of the Obliquus externus abdominis.

2. The External Appearance and Nerve Supply of the Obliquus Abdominis Externus Profundus

Muscles with different external appearances have been reported as being located independently between the Obliquus externus abdominis and internus abdominis. That is, there have been reports of muscles arising from the ribs in the range of the eighth to twelfth rib by one slip (PYE-SMITH *et al.*, 1870-'71; KUDO *et al.*, 1952; YONEKURA, 1954), by two slips (KNOTT, 1883; SHIMAZAKI, 1959; ODAKI, 1963), by three slips (MACALISTER, 1871; LOTH, 1912), or by four slips (LOTH, 1912), and inserting into the fascia of the Obliquus internus abdominis (LOTH, YONEKURA), into the aponeurosis of the Obliquus externus abdominis (KUDO *et al.*, ODAKI), into the inguinal ligament (KNOTT), into the vicinity of the anterior superior iliac spine (PYE-SMITH *et al.*, SHIMAZAKI) or into the iliac crest (MACALISTER, LOTH). As mentioned earlier, however, the nerve supply of the muscle in these reports is not clearly described so that they can not all be considered to be the Obliquus abdominis externus profundus.

EISLER (1912) reported that the Obliquus abdominis externus profundus arose from the rib or fascia of the Intercostalis externus at a level between the fifth to seventh rib and

passed almost horizontally medialwards to insert into the anterior lamina of the sheath of the Rectus abdominis. Most of the findings of the present authors were very similar to his description. However, there is no mention in his report about the origin of Obliquus abdominis externus profundus by two slips from two ribs such as found by KODAMA (1986) and the present authors. It seems appropriate to consider that the human Obliquus abdominis externus profundus originates in general at a level between the fifth to seventh rib by a single slip from one rib or occasionally by two slips from two ribs and inserts into the anterior lamina of the sheath of the Rectus abdominis.

There are no remarkable reports except those by EISLER (1912) and by KODAMA (1986) in which the nerve supply of the Obliquus abdominis externus profundus of man is described. No reports are made on the nerve supply of this muscle in other mammals (Kassianenko, 1927; John, 1928; Bogorodsky, 1929). Even EISLER simply mentioned that this muscle was supplied by a nerve for the Intercostalis externus (the nerve corresponding to the Ramus muscularis externus of FUJITA, 1963). The findings of the present authors indicated that the slip of this muscle could be regarded as being innervated without exception by the Ramus muscularis externus of the intercostal nerve of the corresponding segment. This is homologous with the description of KODAMA (1986).

3. Frequency of the Occurrence of the Obliquus Abdominis Externus Profundus in Man

This muscle has been reported at a considerably low frequency by LOTH (1912 and 1931, 3.8% in negroes and 7% in Europeans), NAKAYAMA *et al.* (1952, 1.9%), KUDO *et al.* (1952, 3%), and YONEKURA (1954, 2%). In contrast to this, Eisler (1912) and KODAMA (1986) mentioned that this muscle was frequently found, while we, as reported above, experienced its occurrence at a frequency of 22%. Thus, there is a significant difference between the results of EISLER, KODAMA and the present authors and those of other investigators.

The location of the origin of this muscle lies adjacent to that of the Obliquus externus abdominis, and furthermore the aponeurosis of insertion of the former is fused with the dorsal surface of that of the latter. Although connective tissue is present between these two muscles, there are differences in the amount of connective tissue among individuals. Therefore, if the amount of connective tissue were small, it would seem possible that this muscle may be mistaken for the dorsal part of the Obliquus externus abdominis. Furthermore, examinations made by severing the belly of the Obliquus externus abdominis may result in inadvertently cutting this muscle at the same time. When both muscles are severed together by this method of examination, it would be difficult to clearly identify this muscle or its nerve supply. Therefore, if a bold assumption is permitted, it is suspected that

this muscle had been overlooked in previous studies when only a little connective tissue was present between this muscle and the Obliquus externus abdominis or when there was fusion between these two muscles. It is felt that the tracing distally of the Ramus muscularis externus to determine which muscle it innervates would make it possible to determine the accurate frequency of occurrence of the Obliquus abdominis externus profundus.

SUMMARY

Gross anatomical inspection was made on the Obliquus abdominis externus profundus using 25 Japanese adult cadavers in order to determine its frequency of occurrence, origin, insertion, relationship to other adjacent muscles, and nerve supply. The findings and discussions were as follows:

1. This muscle was present on eleven sides in eight cadavers (frequency of occurrence 22%). The eleven cases of this muscle were very similar except for differences in the number of slips of origin, the location of the origin, and the relationship to the Obliquus externus abdominis. That is, this muscle arose either by a single slip from the fifth rib (two cases), sixth rib (six cases) or seventh rib (one case), or by two slips from the fifth and sixth ribs (two cases), and ran in almost the same direction as that of the fasciculi of the Obliquus externus abdominis to its aponeurotic insertion into the anterior lamina of the sheath of the Rectus abdominis. The muscle was located dorsal to the Obliquus externus abdominis, and although connective tissue was present between these two muscles in the majority of cases (seven cases), some cases were found in which there was fusion between the two muscles (four cases).

This muscle was supplied from its inner surface by the Ramus muscularis externus from the intercostal nerve of the corresponding segment without exception. In other words, this muscle was supplied by the fifth intercostal nerve when it arose by a single slip from the fifth rib, and was supplied by the fifth and sixth intercostal nerves when it arose by two slips from the fifth and sixth ribs (Table and Figures).

2. Discussion was made on the identification of this muscle. Taking into account the views of EISLER (1912), MYSBERG (1917), and NISHI (1938) concerning the differentiation of the ventral trunk muscles, the Intercostalis externus of the thoracic wall and the Obliquus abdominis externus profundus of the abdominal wall were considered to be serially

homologous in mammals. The Intercostalis externus is supplied from its inner surface by the Ramus muscularis externus of the intercostal nerve. Consequently, it seems that the muscle of the abdominal wall which is supplied from its inner surface by the Ramus muscularis externus should be regarded as being the Obliquus abdominis externus profundus.

It was indicated that previously reported cases of the Obliquus abdominis externus profundus included some muscles which should be regarded as being aberrant bundles of the Obliquus externus abdominis in view of their nerve supply.

3. This muscle has been reported to be of varying form, but the results of the present study can support the descriptions by EISLER (1912) and by KODAMA (1986).

Furthermore, the description that has been made of the nerve supply by EISLER should be supplemented by the following statement. That is, this muscle is supplied by the Ramus muscularis externus coming from the intercostal nerve of the corresponding segment.

4. The frequency at which this muscle has been reported to occur by previous investigators (1.9%-7%) except EISLER (1912) and KODAMA (1981) is considerably lower than that obtained by the present authors (22%). Previous studies had simply given attention to the independence of the muscle, and little attention was directed to the nerve supply. Therefore, if a bold assumption is permitted, it is suspected that this muscle had been overlooked in previous studies when only a little connective tissue was present between this muscle and the Obliquus externus abdominis or when there was fusion between these two muscles.

ABBREVIATIONS FOR ALL FIGURES

O mark : Obliquus abdominis externus profundus, IE : Intercostalis externus, II : Intercostalis internus, OEA : Obliquus externus abdominis, OIA : Obliquus internus abdominis, PMa : Pectoralis major, PMi : Pectoralis minor, RA : Rectus abdominis, 4-11 : fourth-eleventh rib, 5L-8L : lateral cutaneous branch of the numbered intercostal nerve, 5M-7M : Ramus muscularis externus of the numbered intercostal nerve, 5S-7S : slip of the Obliquus externus abdominis originating from the numbered rib.

REFERENCES

- 1) BOGORODSKY, B. W. (1929). Der M. obliquus abdominis externus profundus beim Känguruh. *Anat. Anz.* 67 : 229-232.
- 2) EISLER, P. (1912). Die Muskeln des Stammes. In: Bardelebens Handbuch der Anatomie des Menschen. 575-585, 645-653. Gustav Fischer, Jena.
- 3) FUJITA, T. (1963). Ist der "M. intercostalis intermedius" Eisler anatomisch selbständig? *Folia anat. Jpn.* 39 : 15-30.
- 4) JOHN, M. (1928). Beobachtungen an der Bauch-und Zwischenrippenmuskulatur des Löwen und der Hauskatze. *Anat. Anz.* 65 : 145-154.
- 5) KASSIANENKO, W. (1927). Der M. obliquus abdominis externus profundus beim Hunde. *Anat. Anz.* 64 : 298-303.
- 6) KNOTT, J. F. (1883). Muscular anomalies, including those of the diaphragm, and subdiaphragmatic regions of the human body. *Proc. Roy. Irish Acad.* 2(3) : 627-641.
- 7) KODAMA, K. (1986). Morphological significance of the supracostal muscles, and the superficial intercostal nerve-A new definition. *Acta Anat. Nippon.* 61 : 107-129.
- 8) KUDO, K. and OTOBE, I. (1952). Statistics on the anatomy of Northern Chinese. XIII The lateral abdominal muscles and others. *Hirosaki Igaku.* 3 : 103-108 (in Japanese).
- 9) LOTH, E. (1912). Beiträge zur Anthropologie der Negerweichteile (Muskelsystem). 84-87. Strecker & Schröder, Stuttgart.
- 10) LOTH, E. (1931). Anthropologie des parties molles. 138. Masson & Cie, Paris.
- 11) MACALISTER, A. (1872). Additional observations on muscular anomalies in human anatomy (Third Series), with a catalogue of the principal muscular variations hitherto published. *Transact. Roy. Irish Acad.* 25 : 1-134.
- 12) MAURER, F. (1892). Der Aufbau und die Entwicklung der ventralen Rumpfmuskulatur bei den urodelen Amphibien und deren Beziehung zu den gleichen Muskeln der Selachier und Teleostier. *Morphol. Jahrb.* 18 : 76-179.
- 13) MAURER, F. (1895). Die ventrale Rumpfmuskulatur der anulen Amphibien. *Morphol. Jahrb.* 22 : 225-262.
- 14) MYSBERG, W. A. (1917). Die Homologie der Brust-und Bauchmuskeln der Primaten. *Anat. Anz.* 50 : 121-128.
- 15) NAKAYAMA, T. kaj Okuda, S. (1952). Pri la malofta muskola vario: M. obliquus abdominis externus profundus ĉe homoj. *Acta Anat. Nippon.* 27 : 89-94 (in Japanese).
- 16) NISHI, S. (1938). Muskeln des Rumpfes. In: Bolks Handbuch der vergleichenden Anatomie der Wirbeltiere. 5 Bd. 140-145. Urban und Schwarzenberg, Berlin u. Wien.
- 17) ODAKI, N. (1963). On a case of the M. obliquus abdominis externus profundus. *Acta Anat. Nippon.* 38 : 2 (Abstract in Japanese).
- 18) PYE-SMITH, P. H., HOWSE, H. G. and DAVIES-COLLEY, J. N. C. (1870-71). Notes of abnormalities observed in the dissecting room during the winter sessions of 1868-9 and 1869-70. *Guy's Hosp. Reports* 16 : 147-163.
- 19) SHIMAZAKI, H. (1959). A case of M. obliquus abdominis externus profundus. *Shinshu Med. J.* 8 : 1436-1438 (in Japanese).
- 20) SUGIURA, R. (1935). On a superfluous pair of muscles accompanying the M. obliquus externus abdominis sinister. *Nagoya J. Med. Sci.* 8 : 139-143.

- 21) YONEKURA, S. (1954). A study of the muscles of the neck, chest, abdomen and back in Japanese fetuses. *Igaku Kenkyu* 24 : 1604-1700 (in Japanese).