

Influence of Short-term Steroid Therapy on Bronchial Anastomosis

Chia-Ming HSIEH, M.D.

*From the First Department of Surgery, Nagasaki University
School of Medicine, Nagasaki, Japan*

Address for reprints : Chia-Ming Hsieh, M. D. The First Department of Surgery,
Nagasaki University School of Medicine, 7-1 Sakamoto-Machi, Nagasaki Japan

Received for publication, June 2, 1986

ABSTRACT

Suture granulation is one of the postoperative complications following bronchoplastic procedures. To assess the preventive effect of suppressing suture granulation with short-term use of corticosteroid, left upper sleeve lobectomy was performed on 42 dogs. Prednisolone (2mg/kg) was used in 19 dogs from the operation day for 7 days. Postoperative serial bronchoscopies were performed at intervals. The animals were sacrificed at 4, 7, 14 and 28 days postoperatively and bronchial breaking strength measurement and post-mortem bronchial angiography were carried out. Contraction index of anastomotic line was evaluated in 10 dogs at 28 days. Endoscopically, the steroid-treated animals showed lesser inflammatory changes and low incidence of stenosis at the bronchial anastomosis. Slight decrease of bronchial breaking strength in the steroid-treated group was recognized at 7, 14 days postoperatively, but was not significantly different from their untreated counterparts. In the steroid-treated dogs, restoration of bronchial circulation at the anastomosis was delayed only in the early postoperative period and contraction at the anastomotic line occurred in a lesser tendency than the controls in the late healing phase. These results suggest that short-term administration of corticosteroid decreases inflammation and excessive granulation at anastomotic site and only has a little inhibition on the early phase of bronchial healing.

INTRODUCTION

Postoperative complications following bronchoplastic procedures include granuloma formation, stenosis, persistent atelectasis, broncho-vascular fistula, bronchopleural fistula, and bronchial ectatic change (1, 2, 3, 4). Previous report from our department (2) indicates that the bronchial stenosis resulting from granulation at anastomotic site is 8.8% in spite of using nylon or absorbable suture. In Jensik's series, the incidence is 7% (3). In Naruke's series, four of 20 cases develop postoperative stenosis because of granulation at the anastomotic sites in which consequent pneumonectomy is inevitable in one case (6).

Suture granulation may be corrected by dilation or bronchoscopic removal of sutures and granulation tissues (3, 6). In canine model of lung autotransplantation, it has been demonstrated that steroids may prevent stenosis at bronchial anastomosis (11, 12). Since long-term use of corticosteroid decreases bronchial breaking strength, the following experiment was designed to evaluate whether a short-term use of prednisolone may benefit bronchial anastomosis. To monitor the inhibitory action of corticosteroid on wound healing, bronchial neovascularization and breaking strength at anastomosis were also studied.

MATERIALS AND METHODS

Under intravenous anesthesia (Nembutal, 25mg/kg) and positive ventilation (Harvard respirator), left upper sleeve lobectomy and hilar stripping were performed on 42 mongrel dogs weighing between 10 and 16 kg. Bronchial continuity was reestablished with a running stitch of nylon suture (4-0 or 5-0). And the mucosal approximation was carried out carefully. On the operative and following day, aminobenzyl penicilline (50mg/kg) was administered intramuscularly.

The animals were divided into two groups as follows: (1) Steroid-treated group (19 dogs)-prednisolone (2mg/kg body weight) was given intramuscularly from the operation day for 7 days. (2) Control group (23 dogs)-without medication of prednisolone.

Bronchoscopy was performed immediately after operation to confirm the patency and no technical complications of the anastomosis and to remove the retained sputum and clot by suction. Serial bronchoscopies were also done at 3, 7, 14, 21 and 28 days postoperatively to examine the degree of edema, erythema, stenosis and granulation at the anas-

tomotic line. Since in our clinical cases which showed excellent healing at the first 4 weeks, no bronchial stenosis or granulation was developed during follow-up more than 4 weeks, the experiments in this study were observed for not over 28 days.

To evaluate the bronchial healing, the experiments were sacrificed as follows : (1) Steroid-treated group-two at 4 days, five at 7 days, three at 14 days and five at 28 days ; (2) Control group-two at 4 days and five each at 7, 14, 28 days after the operation. At sacrifice, the animals were heparinized. After performing thoracotomy the descending thoracic aorta which has been ligated above and below the origins of bronchial arteries, was cannulated and perfused with normal saline. Following these preparations, contrast material (gelatin-agar added 30% barium sulfate) was injected through the cannula (7). Before the specimen was removed, the pleural cavity was cooled with iced water to coagulate the contrast material in the vessels. Bronchial angiogram of the specimen was taken with Softex (Type EMB, Softex Co.) using Fuji softex film. Following angiography, the specimens were opened along the central line of the anterior tracheobronchial wall. The regeneration of the bronchial mucosal capillaries growing across the anastomotic line was studied macroscopically.

After the suture material was removed, the breaking strength of each 1cm wide strip of the left main bronchus included anastomosis was measured with Shimadzu Autograph (DCS-500) with a cross-head speed of 5mm per minute. The breaking strength required to disrupt the bronchial wound was printed out graphically and digitally (Figure 1).

For histologic evaluation of the anastomotic site, the divided specimens were fixed in 10% formalin. Sections included the anastomoses were prepared and stained with hematoxylin and eosin.

RESULTS

Postoperative complications were listed as in Table 1. Compared to the control group, it was surprising that animals in the steroid-treated group had no tendency to be infected.

Endoscopic pictures and gross findings

In the control group, edema and hyperemia of the anastomotic site were moderate at 3 days, and decreased to slight degree at 7 days. In the steroid-treated group, edema was slight or absent with moderate or slight hyperemia at 3 days, and at 7 days edema was almost disappeared with slight hyperemia remaining. After two weeks, edema and

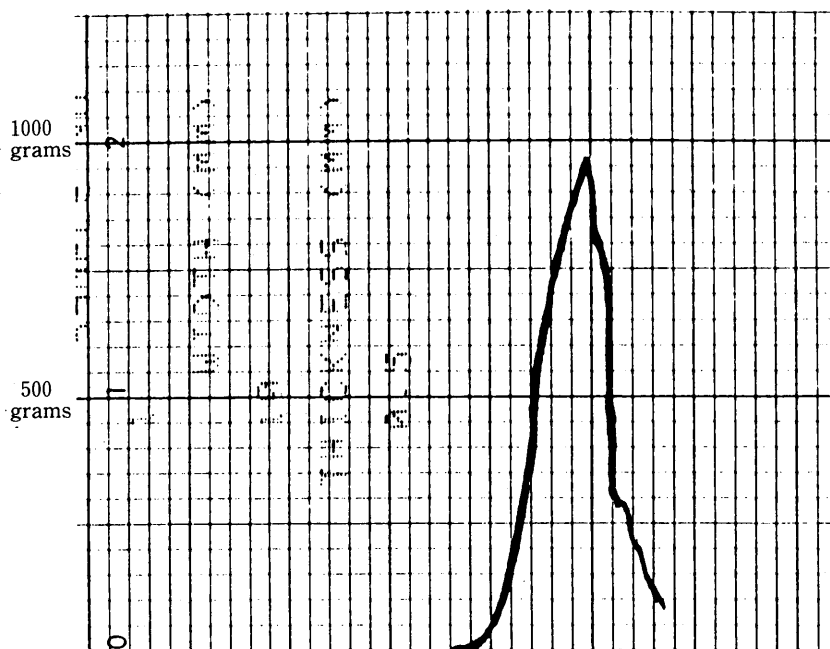


Fig. 1. The graph recorded by Shimadzu Autograph (DCS-500) showing the bronchial breaking strength. Steroid-treated dog, at 28 days.

Table 1. Complications Following Operation (42dogs)

	Controls (23)	Steroid-treated (19)
Death	7	2
Pneumonia	4	2
(left)	(3)	(1)
(bilateral)	(1)	(1)
Empyema	1	
Diarrhea	1	
Sudden Death	1	
Focal Pneumonia		
(at sacrifice)	1	2
Wound Infection,		
Dehiscence	2	1

hyperemia subsided almost completely in the both groups. Peak of moderate narrowing of anastomotic site which resulted from local edema was recognized at 7 days in the control group, but only a few animals showed slight narrowing during the first postoperative week in the steroid-treated group.

Ten dogs were observed for 28 days. In the 5 control dogs, one moderate and two

mild stenoses were noted. In the 5 steroid-treated animals, one moderate and one slight stenosis were recognized, but the former resulted from a minimal bronchial disruption caused by an endoscopic technical failure. Nevertheless, the bronchus-reconstructed lungs continued to be ventilated in a satisfactory way.

Neovascularization.

Regeneration of bronchial artery at the anastomosis was graded by the findings from bronchial angiogram and macroscopic observation of submucosal capillaries (Fig. 2, 3, 4). In the control group, regeneration of bronchial artery appeared already at 4 days, and was nearly completed around 2 weeks. In the steroid-treated group, one animal at 4 days and

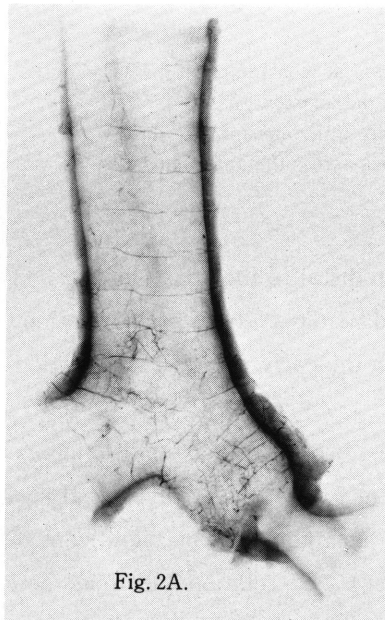


Fig. 2A.

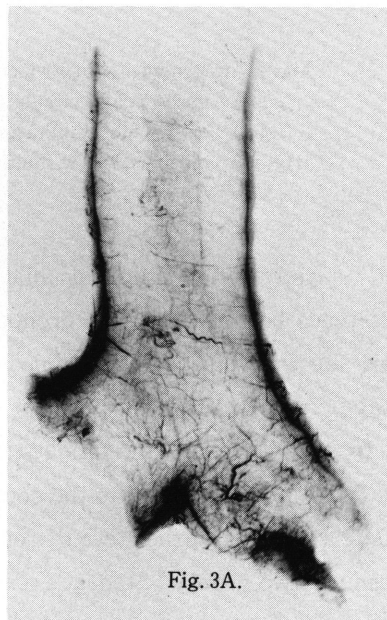

Fig. 3A.

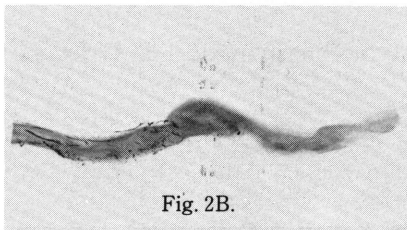


Fig. 2B.




Fig. 3B.

Bronchial angiogram.

Fig. 2.A. Steroid-treated dog at 4 days, Grade 0.

Fig. 2.B. The vertical slice across the anastomosis of the specimen showing no contrast beyond the anastomotic line.

Fig. 3.A. Steroid-treated dog at 7 days, Grade II.

Fig. 3.B. The vertical slice showing multiple vessels across the anastomosis.

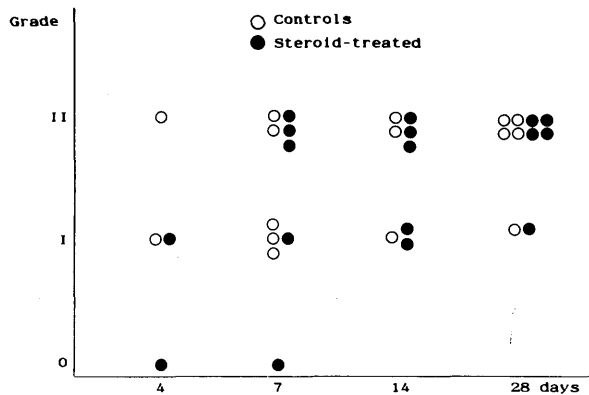


Fig. 4. Regeneration of Bronchial Circulation at Anastomotic Sites Grading
 0 (poor): no bronchial circulation distal to the anastomosis.
 I (fair): only a few capillaries growing across the anastomotic line.
 II (good): regeneration of multiple capillaries across the anastomosis.

one at 7 days were found no bronchial circulation distal to the anastomoses. There was no difference between the both groups at 14 and 28 days. Neovascularization at anastomotic site was retarded by prednisolone only in the early postoperative period.

Bronchial Breaking Strength

In the both groups, breaking strength of the bronchial anastomosis increased with time (Table 2). Compared to the control group at 7 days and 14 days, breaking strength were slightly lower in the steroid-treated group, but there was no significant difference between the two groups (Student's unpaired t-test). No relation was found between the degree of neovascularization and the breaking strength of the bronchial anastomoses.

Contraction Index

From the opened specimens, the breadth at the anastomotic line (=a) and 5mm

Table 2. Recovery of Bronchial Breaking Strength*(grams) in Post-operative Period after Left Upper Sleeve Lobectomy.

Days	4	7	14	28
Control	29.1 ± 0.7 (n=2)	325.6 ± 55.7 (n=5)	697.7 ± 91.7 (n=3)	724.1 ± 87.4 (n=5)
Steroid-treated	28.0 ± 0 (n=2)	236.1 ± 30.6 (n=5)	561.3 ± 81.3 (n=5)	798.2 ± 67.7 (n=5)

*Bronchial Breaking Strength ± Standard Errors

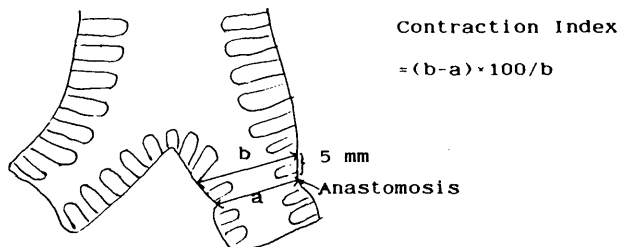
proximal to the anastomosis (= b) were measured. Contraction index was calculated as the following equation, contraction index = $(b-a) \times 100/b$. The larger the index, the greater is the degree of contraction of the anastomotic line. In two of five non-treated dogs at 28 days, their contraction index values were over 25. The steroid-treated animals had lesser tendency to contract at the anastomotic sites in the late healing stage. There were no differences between two groups at 4, 7 and 14 days (Table 3).

Histology of Bronchial Anastomosis

Non-treated dogs showed the strongest inflammatory findings at 7 days (Fig 5, a) and subsided thereafter. In the steroid-treated group, the strongest inflammation was noted at 14 days (Fig 5, b), one week later than that of the non-treated group. Even at 28 days, the steroid-treated animals showed lesser inflammatory changes than the controls. At 28 days, one moderate and two excessive granulation at the anastomoses were noted in 5 control animals. Excessive granulation at anastomotic site secondary to technical failure of bronchoscopy was observed in one of 5 steroid-treated animals. In these cases, the degree of stenosis and contraction index were also high.

Table 3. Contraction Index at 28 Days Postoperatively

Group	Contraction Index				
	1	2	3	4	5
Control (n=5)	30.3	28.1	15.4	12.6	12.5
Steroid- treated (n=5)	20.9	15.7	15.1	12.6	11.5



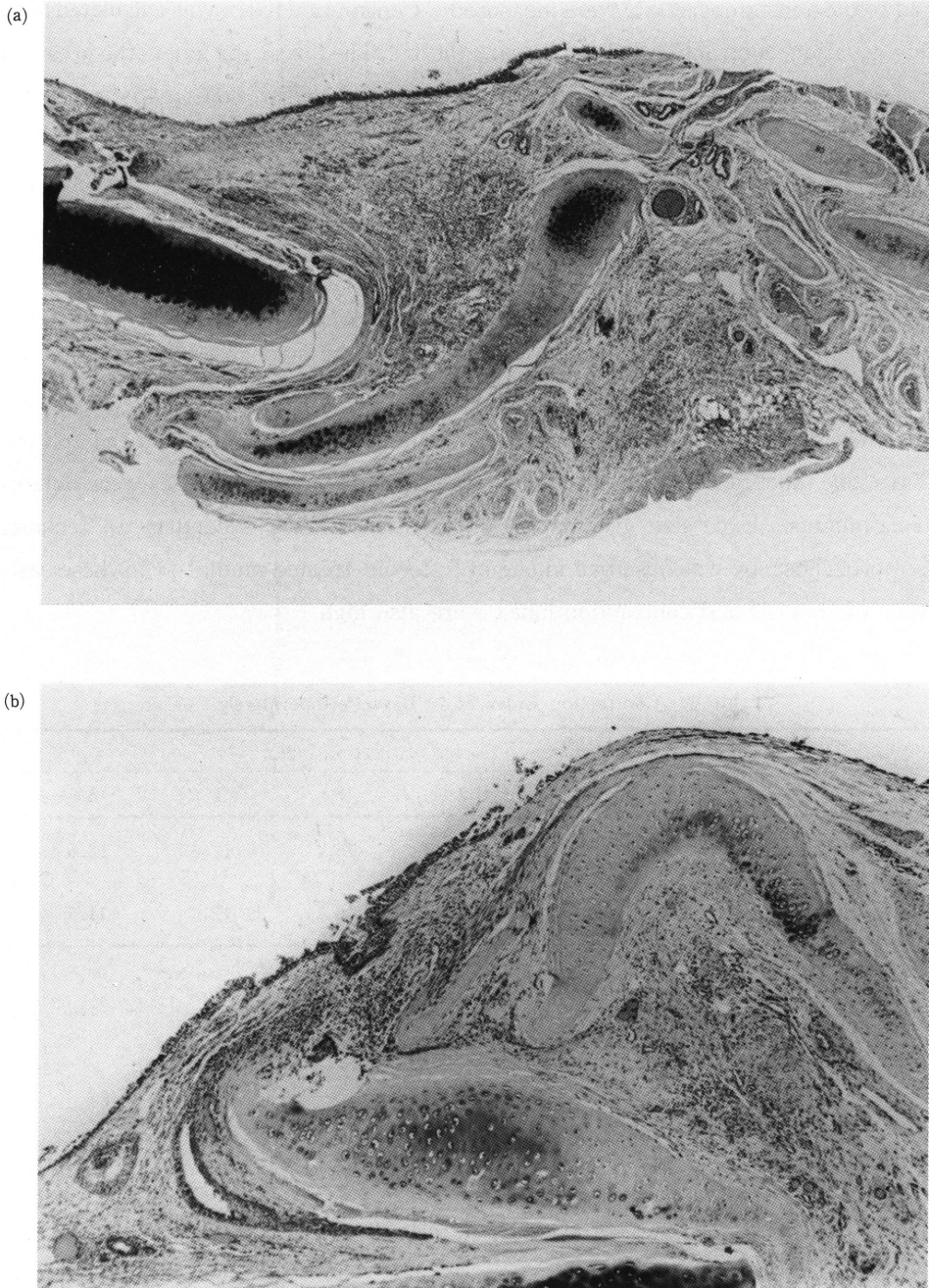


Fig. 5. Histology of Anastomotic Sites

- a) Non-treated dog, 7 days postoperatively. Inflammatory changes is remarkable.
- b) Steroid-treated dog, 14 days. The strongest inflammatory findings is at 14 days postoperatively.

DISCUSSION

During the series of morphologic events of wound, corticosteroids inhibit not only the early inflammatory process (eg edema, capillary dilation, migration of leucocytes into the inflamed area etc.), but also the later appearance such as capillary proliferation, fibroblast proliferation, cicatrization etc (8). Much of the effect of corticosteroids on wound healing is related to their anti-inflammatory action (9). Since the greatest effect on inflammatory phase of wound healing is expected when corticosteroid is administered prior to or immediately after wounding (10), in this study steroid therapy was started immediately after operation.

Although a number of animal models are used to investigate the effect of corticosteroids on wound healing, there is a paucity of well-controlled studies in the canine bronchial anastomotic model. In the lung autotransplantation studied by LIMA (11), half of the controls showed severe stenosis, but only one of the immunosuppressed (methylprednisolone and azathioprine) dogs developed severe bronchostenosis. The natural tendency to contract in the late healing process may be increased by the bronchial ischemia present distal to the anastomosis. In another lung autotransplantation investigated by PINSKER (12), the group of dogs received corticosteroid therapy that was allowed to survive for 21 days after operation demonstrated no evidence of bronchial stenosis. In these two studies, corticosteroids are used continuously as an immunosuppressant after lung autotransplantation while the purpose of the present study was prevention of excessive granulation or stenosis and steroids were used experimentally for seven days. In addition, a pulmonary artery-bronchial artery collateral circulation was preserved in the upper sleeve lobectomy models. At 28 days after operation, compared to only slight contraction in the steroid-treated animals, two of 5 untreated dogs showed moderate bronchial stenosis. As the results of previous two studies, the steroid therapy had a beneficial effect on bronchial anastomoses in this study.

Generally, corticosteroids are considered as an immunosuppressant, administration of steroids after operation is controversial. The result of this study that the steroid-treated animals were not vulnerable to infections was beyond expectation. Combination of antibiotics with steroid therapy might prevent the animals from infections.

As mentioned previously, steroids are considered to inhibit wound healing (13, 14). In an aforementioned study of bronchial anastomotic healing (11), continuous administration of the combination of corticosteroids and azathioprine demonstrated decrease in

bronchial anastomotic breaking strength. Combined use with azathioprine, corticosteroid may show an additional inhibitory effect on wound healing. However, in a study of influence of prednisolone (0.5 mg/kg) and azathioprine either alone or in combination shows no inhibitory effect on the healing of abdominal musculofascial wounds evaluated by breaking strength and hydroxyproline assay (13). In another study of the effect of corticosteroids on bronchial healing with or without intact bronchial circulation (12) in which 2mg of prednisone per kilogram body weight is used. The dose is equivalent to 100 to 120mg for human. However, this dose does not interfere with healing process macroscopically for up to 21 days. In the present study, the same dose of prednisolone was used for seven days and it demonstrated retardation of neovascularization and slight decrease of bronchial breaking strength only at the early postoperative period.

Several factors such as surgical technique, nutrition (16), local blood supply and suture material (5) would influence the outcome of the healing of bronchial anastomosis. Certainly, it is impossible to correct a surgical technical failure by steroid therapy. Undoubtedly, under the situations of poor nutrition or bronchial ischemia, steroid therapy may harmfully influence the bronchial healing.

Since the effect of corticosteroids on wound healing is dose dependent (15) and the susceptibilities to corticosteroids vary among the animals (13, 14), the proper dose and acceptable period of steroid therapy for suppressing excessive granulation at bronchial anastomosis is remained to be established in animal models and for clinical use.

CONCLUSION

A postoperative short-term use of steroid that shows only a little inhibitory effect on bronchial healing, results in an inhibition of early postoperative edema and excessive granulation in cases without surgical technical failure at bronchial anastomosis.

ACKNOWLEDGEMENT

The author gratefully acknowledges professor Tomita and Dr. Ayabe for their guidance and review of this paper. Author also thanks Dr. Kawahara for his technical guidance, Dr. Kusano for his pathologic study of the specimens, Dr. Hasegawa and Dr. Yoshida for their cooperation and all the laboratory assistants for their technical assistance.

REFERENCE

- 1) TOMITA M. Postoperative care following tracheobronchoplasty. *Surgical Therapy* 52 ; 6 : 726-729, 1985.(Abstract in English)
- 2) AYABE H, NAKAMURA Y, MIURA T, KUGIMIYA T, KOGA Y, TSUJI Y. Bronchoplasty for bronchogenic carcinoma. *World J. Surg* 6 : 433-439, 1982.
- 3) JENSIK RT, FABER LP, MILLOY EJ, AMATO JJ. Sleeve lobectomy for carcinoma. *J Thorac Cardiovasc Surg* 64 : 400-412, 1972.
- 4) BENNETT WF, SMITH RA. A twenty-year analysis of the results of sleeve resection for primary bronchogenic carcinoma. *J Thorac Cardiovasc Surg* 76 : 840-845, 1978.
- 5) SHAW KM, LUKE DA. Lobectomy with sleeve resection of the lung and the influence of the suture material used for the bronchial repair. *Thorac Cardiovasc Surg* 27 : 325-329, 1979.
- 6) NARUKE T, YONEYAMA T, OGATA T, SUEMASU K. Bronchoplastic procedures for lung cancer. *J Thorac Cardiovasc Surg* 73 : 927-935, 1977.
- 7) KAWAHARA K, TOMITA M, NAKAMURA Y, AYABE H, KUGIMIYA T. Experimental assessment of restoration of the bronchial artery in sleeve lobectomy combined with pulmonary angioplasty. *Acta Med Nagasaki* 1983 28 : 129-135.
- 8) HAYNES RC, MURAD F. Goodman and Gilman's The Pharmacological Basis of Therapeutics, Seventh edition, New York : MACMILLAN publishing company, 1985 ; p 1471 -1472.
- 9) EHRLICH HP, TARVER H, HUNT TK. Effect of vitamin A and glucocorticoids upon inflammation and collagen synthesis. *Ann Surg* 177 : 222-227, 1973.
- 10) SANDBERG N. Time relationship between administration of cortisone and wound healing in rats. *Acta Chir Scand* 127 : 446-455, 1964.
- 11) LIMA O, COOPER JD, PETER WJ, AYABE H, TOWNSEND E, LUK SC, GOLDBERG M. Effect of methylprednisolone and azathioprine on bronchial healing following lung autotransplantation. *J Thorac Cardiovasc Surg* 82 : 211-215, 1981.
- 12) PINSKER KL, VEITH FT, KAMHOLZ SL, MONTEFUSCO C, EMESON E, HAGSTROM JWC. Influence of bronchial circulation and corticosteroid therapy on bronchial anastomotic healing. *J Thorac Cardiovasc Surg* 87 : 439-444, 1984.
- 13) ARUMUGAN S, NIMMANNIT S, ENQUIST IF. The effect of immunosuppression on wound healing. *Surg Gynecol Obstet* 133 : 72-74, 1971.
- 14) PEACOCK EE, WINKLE WV. Wound repair. Philadelphia : W. B. Saunders Company, 1976 ; 185-189.
- 15) DIPASQUALE G, STEINETZ BG. Relationship of food intake to the effect of cortisone acetate on skin wound healing. *Proc Soc Exp Biol Med* 1964 ; 118-120, 1964.
- 16) FINDLAY CW Jr, HOWES EL. The combined effect of cortisone and partial protein depletion on wound healing. *New Eng J Med* 246 : 597, 1952.