

Selective Proximal Vagotomy Associated with Gastric Transection for the Patients with Duodenal Ulcer.

Toshio MIURA, Masao TOMITA, Toshiyo ISHII,
Takatoshi SHIMOYAMA, Yoshihisa ISHIKAWA, Shigehiro HASHIMOTO,
Tatsuo HIRANO, Tohru NAKAGOE

*First Department of Surgery,
Nagasaki University School of Medicine,
Nagasaki, Japan*

Received for publication, June 30, 1986

INTRODUCTION

Vagotomy first applied by DRAGSTEDT and OWENS¹⁾ to humans clinically appears to have been completed by selective proximal vagotomy (SPV) by HOLLE²⁾, and this is considered to be the most idealistic operative procedure for duodenal ulcers.

Historically, this has been accomplished by the addition of drainage procedure and selective vagotomy.

The advantages of SPV lie in the fact that the procedure blocks the autonomic control of gastric secretion and possibly suppresses the sensitivity of parietal cells to gastrin while maintaining the normal gastric function i.e. the emptying of the gastric content.

As AMDRUP and JENSEN stated³⁾, pyloroplasty is not required with the absence of stenosis due to peptic scarring.

Therefore, with the absence of stenosis in the region of pyloric ring, duodenoplasty is considered to be the sufficient adjunct procedure while pyloroplasty is reserved for the instance where stenotic lesions secondary to peptic scarring are present in the pylorus³⁾⁴⁾.

Since 1971, we have been using SPV in our clinic for treating duodenal ulcers as the

三浦 敏夫, 富田 正雄, 石井 俊世, 下山 孝俊, 石川 喜久, 橋本 茂廣, 平野 達雄
中越 享

primary operative procedure.

As we experienced a few instances of the dumping syndrome after pyloroplasty²⁰⁾, we have discontinued the drainage procedure unless there are symptoms of pyloric stenosis.

It has been known that the original method of SPV was associated with a high incidence of recurrence (4–22%)⁷⁾⁸⁾⁹⁾¹⁰⁾¹¹⁾ possibly due to incomplete denervation of parietal cells. There have been many attempts to improve completeness of vagotomy in SPV⁸⁾¹²⁾¹³⁾¹⁴⁾¹⁵⁾¹⁶⁾.

It is also our experience that is considerably inferior in suppressing the gastric acidity to other methods, such as subtotal gastrectomy or antrectomy combined with selective vagotomy, and we have elaborated the following procedure. It is a gastric transection combined with SPV (SPV-T).

Since June 1977, we have observed 12 such examples in which considerable decrease in gastric acidity was noted in comparison to simple SPV. The following is the description of the operative procedure, effects on gastric acidity, serum gastrin and postoperative complications.

OPERATIVE TECHNIQUE

An upper midline incision is made, starting at the level of 1 to 2 cm above the xyphoid process down to just above the umbilicus, shifting the upper end to the left.

First, we locate the duodenal ulcer, determine the extent of the scarring, evaluate thickening of the wall of the bulbus of the duodenum, and the presence or absence of stenosis. The hepatic triangular hiatus is cut by cautery, and the left lobe of the liver is flipped over. The peritoneum overlying the esophageal hiatus in the diaphragm is divided by means of a transverse scissor-cut. The esophagus is hooked out of the hiatus with the index finger. A rubber tube is passed underneath it. The anterior and posterior trunks are then elevated in turn by a right angle clamp and retracted by the rubber tube respectively so that the structures would be easily bundled in the following operative maneuvering.

On the greater curvature side, the greater omentum is incised upward starting 5 to 6 cm from the pyloric ring. This enables one to examine in the lesser sac, the presence or absence of pancreas pathology, and the course and distribution of the posterior antral branch of the vagus.

Identifying the antral Latarjet nerve by pulling down the stomach and stretching the

lesser omentum, the dissection starts just above the crow's foot. We sever the most proximal ascending branch while preserving the crow's foot. When this branch can not be identified, the gastric transection combined with SPV may be carried out. The vessel and nerve are mobilized using a right angle clamp and sever between two silk ligatures. We have elaborated a Siebel-Flick's type pincette that can be utilized for this purpose. This pincette is used to separate the anterior leaf of the lesser omentum so that vessels and nerves in the structures become well visualized. During the ligation and severing them, the pincette can be placed on the posterior leaf of the lesser omentum in its opened position by fixing a sliding hook. Several segments of the anterior leaf of the lesser omentum including gastric branches to the cardiac fundus are divided continuing toward up along the lesser curvature to the esophagogastric junction. Underneath the severed branches of the anterior, the gastric plexus becomes visible in the second layer. Then, turning up the stomach, the posterior wall of the stomach is exposed, by starting a dissection of posterior branches of Latarjet nerve. Sometimes, we have a little difficulty to identify the posterior caudal borderline nerve. It is usually incised 1-2cm higher on the posterior side than the anterior branch. Keeping close to the stomach wall, the segments including the caudal borderline nerve to the fundus. Slightly higher than to anterior segment, ligation and severance are made which create a small opening to the omental bursa. Two or three more segments of the posterior leaf with related vessels have been divided and ligated.

Again, returning the stomach to the normal position, the serosally denuded part of the lesser curvature is sutured by interrupted silk fine suture, bringing the anterior and the posterior wall of the stomach together on the medial side of the lesser curvature. Holding the tied sutures, the process of separating the attachment of the leaf from the stomach is continued upward to the outer margin of the lower end of the esophagus, step to step, and the denuded part of the lesser curvature is sutured in succession. Upon reaching the His angle, all tissue reaching there is removed down to the muscular tissue, and any branches descending to the left of the esophagus are found and removed. The esophagus is usually cleared for at least 5cm above the cardia. During the dissection, special care is taken when exposing the lower esophagus to avoid missing the smallest vagal branches using leucomethylen blue staining. The procedure of our standard SPV is illustrated in Fig. 1. In no case was there any attempt to locate the proximal limit of the antrum by means of an intra-gastric pH probe or staining of the mucosa with congo-red through a gastrotomy.

Gastric transection is set through the points 6.5cm proximal to the pyloric ring on the lesser curvature at 7.0cm on the greater curvature. It is our observation that the transection line approximates the junction between the areas, distributed by antral glands and by

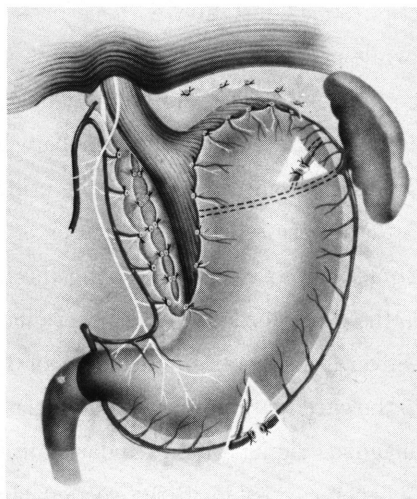


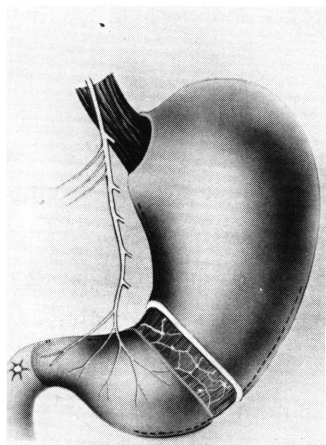
Fig. 1. Schematic representation of completed procedure of our standard selective proximal vagotomy.

parietal cells. Along the proposed transection line, the anterior half of the gastric wall is incised which includes the serosa and muscle coat, and the submucosal vessels are clamped for hemostasis. The mucosa is dissected from the muscularis upward and downward by 2cm in width (Fig. 2-1). The submucosal vessel found on the dissected surface are stick-ligated using 4-0 silk sutures. A Kirshner's needle may be inserted from the greater curvature to the lesser curvature through these portions as well as through the gastric lumen. Then, the Kirshner's needle is lifted by holding it at both ends (Fig. 2-2). The lifted mucosal portion of the anterior gastric wall is pressed and sutured using Nakayama's GI sawing instrument. The mucosa of the posterior portion of the gastric wall is sutured in a similar manner after flopping the stomach along its long axis. Finally, the sero-muscular suture is given with 3-0 interrupted silk sutures (Fig. 2-5).

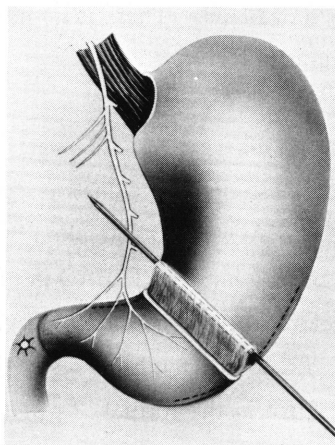
CLINICAL MATERIAL AND RESULTS

During the two years from 1977 to 1978, we performed this procedure in 12 patients with duodenal ulcer. The average age was 23 years ranging from 16 to 36 years. All 12 patients were males. On presenting their symptoms, abdominal pain was found the most frequent symptoms in all patients. Nausea was in 4 patients and melena in 2. The duration of the symptoms until operation was 3.6 years on the average.

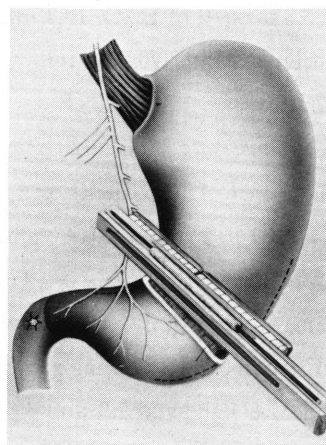
Preoperative gastric secretion studies were performed in 11 cases with an average



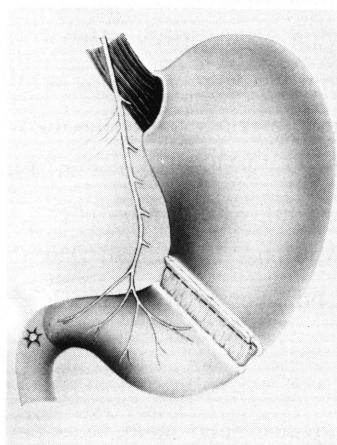
1. The serosa and muscle coat is incised



2. A Kirschner's is inserted from greater curvature to lesser curvature through the gastric lumen

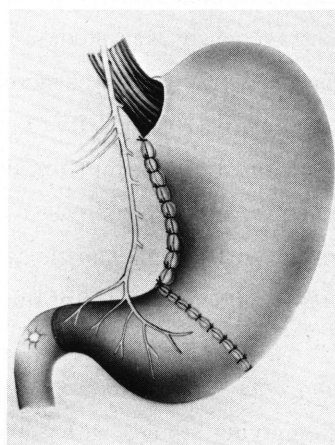


3. The needle is lifted, then mucosa of anterior gastric wall is pressed and sutured using Nakayama's GI sawing instrument



4. The lifted mucosal portion is cut off by Bovie

FIG-2



5. The sero-muscular suture is placed with 3-0 interrupted silk sutures

Fig. 2. Operative technique of selective proximal vagotomy with gastric transection (SPV-T).

of 6.8 mEq/h of BAO, 19.3 mEq/h of MAO. There is no mortality and morbidity in these patients at an average follow-up of 6.7 years.

Reduction rate of gastric acid secretion :

In 7 of 12 patients, pre- and post-operative gastric secretion studies were performed (Table 1). Preoperative values of BAO, MAO provoked by tetragastrin were 6.8 and 21.0 mEq/h in SPV, while 9.5, 19.3 mEq/h in SPV-T, BAO in SPV-T was slightly higher than those in SPV only. Three weeks after the operation, BAO and MAO were 2.0 and 6.2 mEq/h in SPV, whereas in SPV-T 2.3 and 3.9 mEq/h respectively. Six months later, BAO and MAO showed 1.9 and 6.6 mEq/h in the former, 2.4 and 3.8 mEq/h in the latter.

The reduction rate of acid secretion showed about 70% in both BAO and MAO in SPV, while in SPV-T showed 75% in BAO and 80% in MAO. There was more reduction among patients who underwent SPV-T. Twelve months later, the reduction rate of acid secretion showed a tendency to decrease and those of BAO and MAO about 60% in SPV, while 65.3% and 70.5% respectively in SPV-T.

Changes in serum gastrin Levels :

In 11 patients treated by SPV-T, the serum gastrin levels to stimulation using 0.2U./kg of insulin intravenously was studied. Following insulin stimulation to preoperative patients, the serum gastrin levels was increased from 100 pg/ml to 130 pg/ml by 30%, while after the operation both SPV and SPV-T, the serum gastrin levels in fasting was increased to 150 pg/ml (50%) and 170 pg/ml (70%) respectively. Following insulin stimulation, the values of serum gastrin were increased to 270 pg/ml, 320 pg/ml. There was a higher response to insulin in SPV-T than those in SPV alone. It seemed that these findings followed as a result of denervation of the vagus and severing of the plexus of the intrinsic nerve (Fig. 3).

Gastric emptying after the operation :

Gastric emptying studies with a ^{99m}Tc-labelled solid meal were performed in 6 patients (Fig. 4). The peristaltic movements of the gastric wall occurred rhythmically

Table 1. Change of gastric acid secretion.

		SPV	SPV-T
Before operation	BAO	6.8mEq/h	9.5mEq/h
	MAO	21.0mEq/h	19.3mEq/h
3 Weeks after op.	BAO	2.0 (70.6%)	2.3 (75.8%)
	MAO	6.2 (70.5%)	3.9 (79.8%)
6 Months after op.	BAO	1.9 (72.0%)	2.4 (74.7%)
	MAO	6.6 (68.6%)	3.8 (80.3%)

(): reduction rate

once per 20 seconds in preoperative patients with duodenal ulcer, in these who underwent SPV as well as in healthy volunteers. After gastric transection, the peristaltic movements were prolonged and occurred once per 30 seconds. Half gastric emptying times (T1/2) showed faster 16.7 min. in postoperative patients than those of 29 ± 5.3 min. in preoperative patients and 28.4 ± 10 min. in patients with SPV (Fig. 5). It was concluded that gastric emptying was significantly faster in patients who underwent SPV-T than SPV owing to the interception of conduction of peristaltic stimulation by gastric transection.

Visick grading :

Functional results according to a Visick classification were followed that the incidence of a patient graded Visick I, II, III and IV was 75%, 16.7%, 0% and 8.3% respectively in SPV-T, while in SPV only, the incidence was 77.8%, 16.7%, 1.9% and 3.7% respectively. There was no differences in both groups in respect to clinical results according to a Visick grading (Fig. 6). One recurrence ulcer occurred after SPV-T with pyloroplasty, and one without pyloroplasty. The latter patient underwent antrectomy one year and three months later. The former patient treated medically with cimetidin, and there was no sign of ulcer at the time of this study.

DISCUSSION

In 1957, GRIFFITH and HARKINS²¹⁾ reported the results of their experimental study on selective vagotomy for the parietal cells. They suggested the possible application of the procedure to the clinical material because of its preservation of an innervated, intact antrum and pylorus, its lack of the retention of gastric contents, in addition to the adequate reduction of the gastric acidity.

In 1967, HOLLE and HART²⁾²²⁾ were the first to perform this type of denervation in humans. Of 461 patients who underwent this procedure, the recurrence rate was 0.87%, which was significantly lower than those after vagotomy reported by other authors. But, its advantage was lost largely because of the combination with the procedure with pyloroplasty. JOHNSTON and WILKINSON⁴⁾, and AMDRUP and JENSEN³⁾ independently, but at the same time, demonstrated in humans that parietal cell vagotomy did not require the drainage operation in accompaniment. This method has been widely applied as an acceptable procedure for the treatment of duodenal ulcer in Europe, under many names including parietal cell vagotomy, selective vagotomy of the parietal cell mass, highly selective vagotomy, selective proximal vagotomy, acid fundic selective vagotomy and

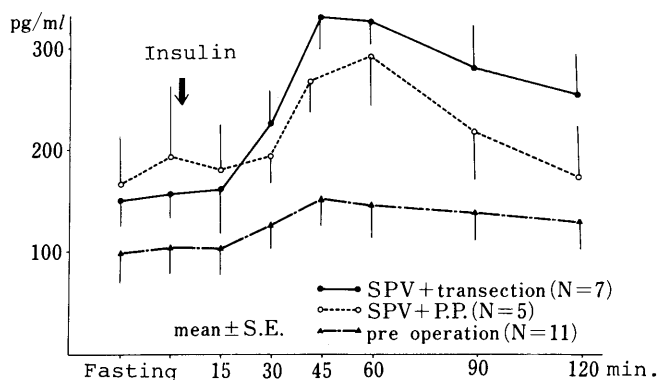


Fig. 3. change of serum gastrin levels after gastric transection with SPV and SPV.

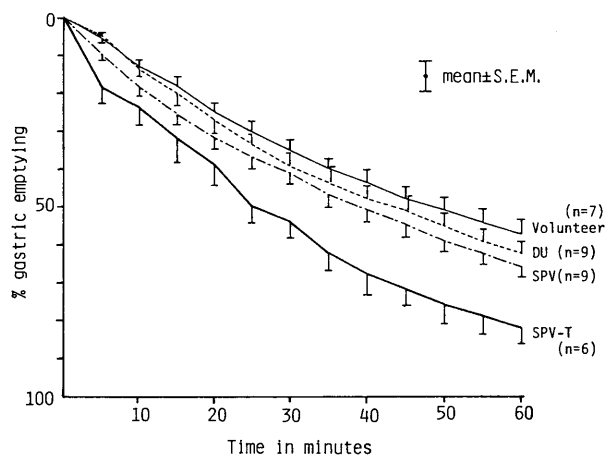


Fig. 4. Gastric emptying curve.

	(n)	mean ± SEM	T 1/2
Volunteer	(7)	50.8 ± 4.7	• • • • •
D. U.	(9)	43.1 ± 3.7	• • • • •
SPV	(9)	40.7 ± 3.3	• • • • •
SPV+T	(6)	27.9* ± 4.3	• • • • •

10 20 30 40 50 60 70 min.

Fig. 5. Half gastric emptying times (T1/2). ($P < 0.05$)

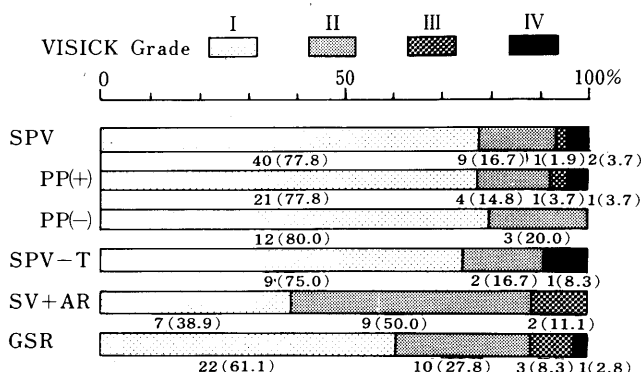


Fig. 6. Clinical results of surgical treatment for chronic duodenal ulcer according to VISICK grading.

proximal gastric vagotomy. Applying the original type of this procedure, even in the hands of surgeons with wide experience, recurrence of ulcer have occurred in 4% to 22% of patients at 5 to 8 years. Moreover, they continued to increase linearly even after 8 years.

There have been many attempts to improve completeness of vagotomy to eliminate the recurrence of ulcer in selective vagotomy. LIEBERG *et al*⁷⁾ expressed that the esophagus should be bared of vagal fibers for 6 to 8cm above the cardia, because a short esophageal dissection results as the increasing of the risk of recurrent ulceration owing to perform a incomplete denervation of fibers running through the esophageal wall. We routinely clean the esophagus for more than 5cm above the cardia. GRASSI *et al*¹³⁾²³⁾, for the completion of vagal denervation of the acid-secreting parietal cell, placed particular importance, primarily on the section of what they call the "criminal fibers" which run over the posterior surface of the cardia. In order to perform a complete denervation of the parietal cell mass, ROSATI *et al*¹⁴⁾ recommended to extend the vagotomy to the greater curvature by section of the right gastroepiploic neurovascular peduncle, in addition to severing the descending tuberosity branches that run on the freno-gastric ligament. The mean insulin peak acid output was reduced to 93% after operation and was maintained one year after the procedure without affecting the gastric emptying time. They expressed this extended technique could be effective for the surgical treatment of hypersecretory patients. To get rid of recurrences, AOKI and NAGAO¹⁵⁾ reported to have severed the nerve of the gastro-pancreatic ligament adjoining the posterior gastric artery. In patients given this procedure, there was no recurrent ulcer. TAKITA *et al*¹²⁾ reported that the most proximal ascending branch of crow's foot should be severed for completeness of denervation to the parietal cell mass. The results of intra-operative tests for completeness of SPV were

reported by some authors. The Burge test is an electrical stimulation test. The vagi are stimulated by a circular electrode which is placed around the lower esophagus.

An oral gastric tube with a cuff in the region of the electrode brings the vagal trunks in contact with the electrode. INBERG *et al* (30) reported that in their 64 cases of SPV, the test proved negative, indicating complete vagotomy was found in 61 patients. They expressed this test produced good results, especially in SPV, but as soon as the technique was developed the use of Burge's test can be restricted to difficult cases. GRASSI *et al*⁽²³⁾ checked the exact antrofundal delimitation by way of a gastric pH-meter which they used as intra-operative test to determine complete vagal section. Incompletely denervated areas are discovered because they showed the pH values of 1.8 to 2.2. The vagus branch responsible for this can now be easily identified. After its dissection, there is an immediate rise in the pH from 5.5 to 7.0. The postoperative secretory test on 396 patients showed a reduction from 90 to 75% of BAO, MAO and PAO. There were only 8 cases or 1.1% of recurrent ulcer, of which 4 (1.5%) occurred after highly selective vagotomy without drainage, and 4 (1.5%) with drainage. ROSATI *et al*⁽¹⁴⁾ also monitored the completeness of the parietal cell denervation intraoperatively with a pH-meter. In 1977, JOHNSON and BAXTER⁽¹⁶⁾ identified four distinct areas of the stomach where nerve fibers were likely to be left using the Grassi's intra-operative test of the mucosal pH. Three of these can usually be eliminated by careful attention to the technique, but the fourth-distal extent of the parietal cellmass can only be identified by a precise intraoperative test. This is relevant to proximal gastric vagotomy. A precise intra-operative test of residual innervation is particularly helpful in establishing the technique of proximal gastric vagotomy.

JACINTO *et al*⁽²⁶⁾ initially only 5 to 6cm the distal stomach was left with vagal innervation in 54 patients. Later, fearing that such an extensive denervation might interfere in some cases with normal emptying, all the terminal branches of the anterior nerve of Latarjet in 45 patients were preserved, which meant retaining vagal innervation to 8cm or more of the distal stomach. But the recurrent rate and acid reduction studies showed no special differences in the two groups. Most authors⁽²⁵⁾⁽¹¹⁾ preserved the nerves of Latarjet to the antrum up to 6 to 8.6cm from the pylorus.

We have usually severed the most proximal branch of crow's foot, preserving the antrum innervated 6 to 6.5cm from the pylorus. The procedures of gastric transection were added at the point of 6.5cm proximal to pylorus. In our series, we have never experienced the postoperative cases of SPV with delayed emptying.

In 1960, NYHUS *et al*⁽²⁴⁾ showed the decrease in Heidenhain pouch secretion following separation of the mucosa from the underlying layer (antro-neurolisis) without change in

motility. Seromuscular transection, according to OBERHELMAN²⁷⁾, causes a relatively small and variable decrease in pouch secretion.

JOHNSON *et al*²⁸⁾ reported that the acid secretory response of the Heidenhain pouch to food was reduced in all animals who had vagal denervation of the antral mucosa, but no difference was noted between vagal denervation by seromuscular transection and antroneurolysis on the amount of depression produced on pouch secretion. Seromuscular transection ended vagal-induced antral motility.

These observations have led to the postulation that the two different nerve fiber groups might respond to vagal stimulation, one causing increased motor activity, and the other, mediating the release of gastrin. MASON *et al*²⁹⁾ also concluded, after their experiments, that antral motility was derived directly from vagal fibers, but the gastrin release was less dependent on this direct innervation and might arise most probably from Meissner's plexus.

In 1974, DEBAS *et al*¹⁷⁾ found in dogs with the innervated antral pouch, gastric fistula, and Heidenhain pouch, acid secretion and serum gastrin, measured in response to distention of the antral pouch with NaHCO and HCl solution under various pressures. Acidification of the antral pouch abolished gastrin release and acid secretion from the Heidenhain pouch in response to distention, but did not abolish acid secretion from the gastric fistula. These results indicated that antral distention caused acid secretion by at least two mechanisms: only one of which was gastrin-dependent, while gastrin-independent mechanism was a pyloro-oxynitic reflex.

On this postulation, we performed a study on the gastric transection with SPV in dogs¹⁸⁾¹⁹⁾. ISHIKAWA¹⁸⁾, the effects of transection at the antral fundic junction studied in Pavlov pouch dogs and gastric-fistula dogs with SPV. Experimental schema is illustrated in Fig. 7. Under feeding stimulation using solid meals, gastric transection reduced Pavlov-pouch acid secretion by about 47%, and serum gastric levels were decreased by about 31%. By tetragastrin stimulation, gastric transection was reduced the gastric secretion by about 35% in MAO. (Fig. 8) According to HASHIMOTO, the gastric emptying time and volume of liquid or solid test meals were evaluated in dogs which underwent SPV with transection of the stomach, and in untreated dogs as controls.¹⁹⁾ The gastric emptying of liquid meals was significantly shortened in the dogs treated with SPV with gastric transection as compared with the untreated dogs. The gastric emptying pattern of solid test meals in the animals treated with these surgical procedures was similar to that of untreated ones. (Fig. 9) On gastric reservoir function, Cannon already stated that the cardiac part of the stomach acted as a reservoir pressing out its contents a little at a time as the antral

mechanism was ready to receive them. CANNON and LIEB³²⁾, in 1911, found that during deglutition the stomach relaxed already when food passed the pharynx and the upper part of the esophagus and termed this response "*gastric receptive relaxation*." We postulated that the increase in gastric emptying in patients who underwent SPV-T depended on the lack of gastric receptive relaxation causing by complete denervation of the intrinsic nerve by gastric transection.

In these experiment of ours, it could be concluded that a marked reduction in gastric acid secretion with satisfactory subjective complications was obtained with SPV with gastric transection than with SPV alone. This procedure was thought to be of value for a choice of operative techniques for duodenal ulcer.

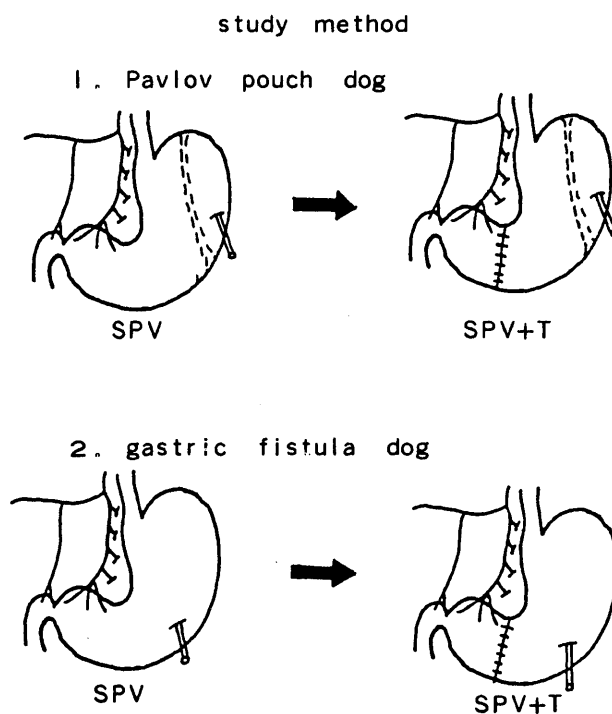


Fig. 7. Experimental schema according to Ishikawa.

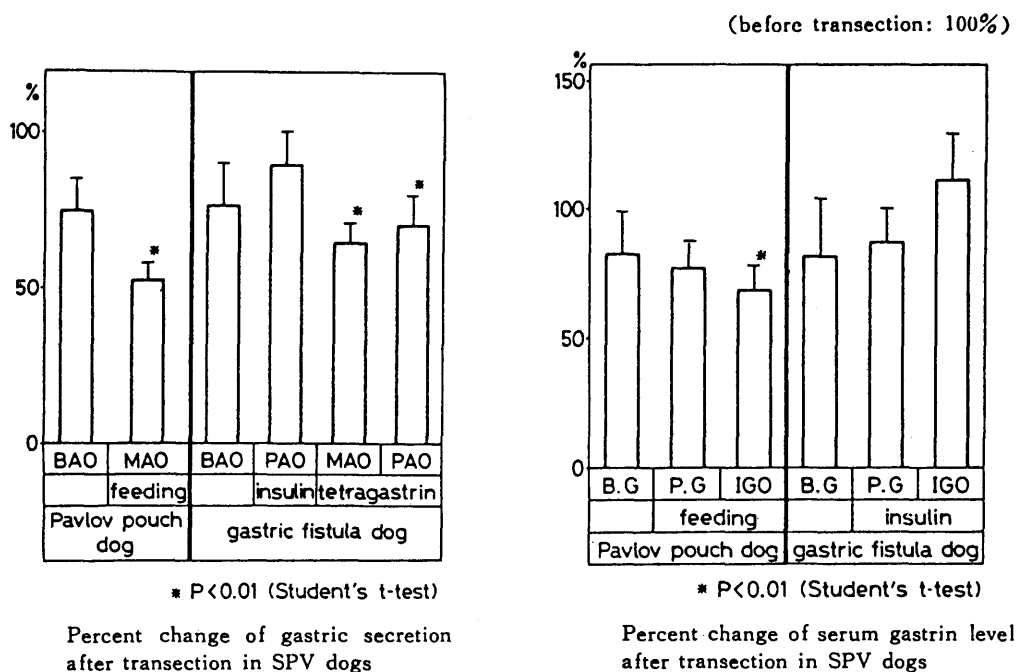


Fig. 8. Gastric acid secretion and serum gastrin level.

SUMMARY

For the treatment of peptic ulcer diseases of the duodenum, we introduced a gastric transection combined with selective proximal vagotomy.

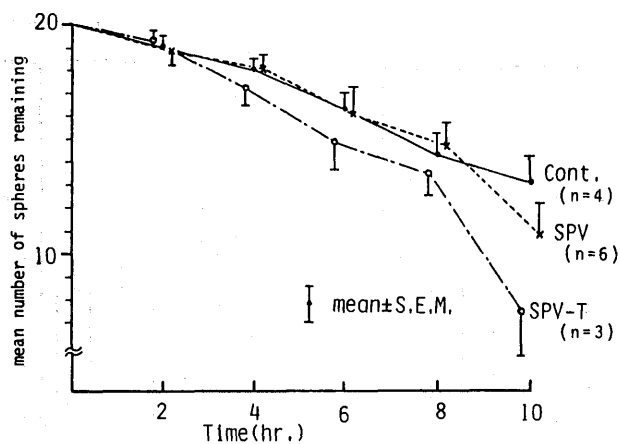
In comparison with typical SPV, the method appears to be superior with subjective improvements in respect to postoperative complaints, gastric acid secretion, serum gastrin levels, while maintaining the gastric emptying function.

The method was thought to be of particular value when a high gastric acidity is present or the course of pyloric sinus branches of the vagus is not really identified.

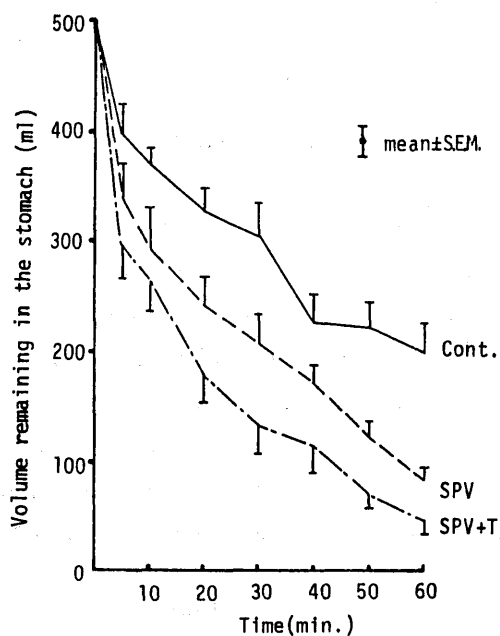
The surgical technique of this procedure and clinical results were discussed.

REFERENCES

- 1) DRAGSTEDT, L.R. and F.M. OWENS: Supradiaphragmatic section of the vagus nerve in treatment of duodenal ulcer. *Arch. Surg.* 44: 152-154, 1943.
- 2) HOLLE, F. and W. HART: News in the surgery of the surgery of gastroduodenal ulcer. *Mediz. Klinik.* 62: 441, 1967.
- 3) AMDRUP, B. E. and C.A. GRIFFITH: Selective vagotomy of the parietal mass. Part I: With preservation of the innervated antrum and pylorus. *Ann. Surg.* 170: 207, 1969.



1) Gastric emptying with solid meals



2) Gastric emptying with liquid meals

Fig. 9. Gastric emptying curves.

- 4) JOHNSTON, D. and A. R. WILKINSON : Selective vagotomy with innervated antrum without drainage procedure for duodenal ulcer. *Br. J. Surg.* 56 : 626, 1969.
- 5) KENNEDY, T. *et al.* : Proximal gastric vagotomy : interim results of a randomised controlled trial. *Br. J. Surg.* 62 : 301-303, 1975.
- 6) TANNER, N.C. : Peptic ulcer surgery modification averts complications. *J. A. M. A.* 223 : 606-607, 1973.
- 7) LIEBERG, G. and J. OSCARSON : Selective proximal vagotomy — short time follow up of 80 patients —. *Scand. J. Gastroenterol.* 8 (suppl.) 12, 1972.
- 8) HALLENBECK, G.A. and GLEYSTEN, J. : Proximal gastric vagotomy without "drainage" An experimental study. *Ann. Surg.* 179 : 608-617, 1974.
- 9) WASTELL, C. and T. WILSON : Proximal gastric vagotomy. *Proc. R. Soc. Med.* 67 : 1183-1185, 1974.
- 10) JORDAN, P. H. : Parietal cell vagotomy without drainage for treatment of duodenal ulcer : A two-to three year follow up report. *Arch. Surg.* 111 : 370-376, 1976.
- 11) KRONBORG, O. and P. MADSEN : A controlled randomized trial of highly selective vagotomy versus selective vagotomy and pyloroplasty in the treatment of duodenal ulcer. *Gut*, 16 : 268-271, 1975.
- 12) TAKITA, S. *et al.* : Clinical and experimental studies on gastric function after several types of vagotomy. *Bul. Soc. Int. Chir.* 30 : 462-470, 1971.
- 13) GRASSI, G. : Vagotomie, p. 83. Geoge Thieme, Verlag. 1976.
- 14) ROSATI, I. *et al.* : Extended selective proximal vagotomy : Observation on a variant in technique. *Chir. Gastroent.* 10 : 33-37, 1976.
- 15) NAGAO, F. and T. AOKI : A technique of selective proximal vagotomy for duodenal ulcer. *J. Clin. Surg.* 33 : 201-212, 1978.
- 16) JOHNSON, A. G. and H. K. BAXTER : Where is your vagotomy incomplete? Observations on operative technique. *Br. J. Surg.* 64 : 583-586, 1977.
- 17) DEBAS, H.T. *et al.* : Proof of a pyloro-oxynitic reflex for stimulation of acid secretion. *Gastroenterology* 66 : 526, 1974.
- 18) ISHIKAWA, Y. : Experimental and clinical researches concerning selective proximal vagotomy with gastric transection. — Especially from the view of gastric acid and gastrin secretion. *Nagasaki Igakkai Zasshi*, 55 : 327-344, 1980.
- 19) HASHIMOTO, S. : The influence of selective proximal vagotomy with gastric transection on gastric emptying. *Nagasaki Igakkai Zasshi*, 55 : 420-436, 1980.
- 20) c. f. HOLLE, F. : Operative technique of SPV and pyloroplasty, Vagotomy, latest Advances, Springer, Berlin 1974.
- 21) GRIFFITH, C. A. and H. N. HARKINS : Prietal gastric vagotomy : An experimental study. *Gastroenterology* 32 : 96-102, 1957.
- 22) HOLLE, F. *et al.* : Neue Wege der Chirurgie des Gastroduodenalulkus. *Med. Klin.* 62 : 441-450, 1967.
- 23) GRASSI, G. *et al.* : The results of highly selective vagotomy in our experience (787 cases). *Chir. Gastroent.* 11 : 51-58, 1977.
- 24) NYHUS, L. M. *et al.* : The control of gastrin release. *Gastroenterology*. 39 : 582-589, 1960.
- 25) HANCOCK, D. M. *et al.* : The combination of proximal gastric vagotomy with a rotational

- posterior gastropexy for duodenal ulcer. *Br. J. Surg.* **65** : 706-711, 1978.
- 26) JACINTO de Miguel : Recurrence after proximal gastric vagotomy without drainage for duodenal ulcer. *Br. J. Surg.* **64** : 473-476, 1977.
- 27) OBERHELMAN, H.A. *et al.* : Relationship of antral and fundic vagal denervation to gastric secretion. *Am. J. Physiol.* **201** : 171-174, 1961.
- 28) JOHNSON, A.N. *et al.* : Significance of vagal influence on release of antral gastrin. *Am. J. Surg.* **108** : 31-3-, 1964.
- 29) MASON, G.R. *et al.* : The role of intrinsic neural plexuses in release of gastric antral gastrin. *Arch. Surg.* **90** : 895-898, 1965.
- 30) INBERG, K.R. *et al.* : The Burge test for completeness of vagotomy. *Acta Chir. Scand.* **139** : 61-71, 1973.
- 31) DEBAS, H. T. *et al.* : Evidence for Oxyntopyloric reflex for release of antral gastrin. *Gastroenterology.* **68** : 687-690, 1975.