

Carcinoma of the Rectum Following Irradiation for Cervical Cancer

Ichiro SEKINE¹⁾, Yoshihisa KAWASE¹⁾, Junji OOI¹⁾, Masahiro ITO¹⁾,
Issei NISHIMORI¹⁾, Osamu TAKAHARA²⁾, Hideharu FUJII³⁾,
Takatoshi SHIMOYAMA⁴⁾, Masao TOMITA⁴⁾ and Yutaka OKUMURA⁵⁾

- 1) Department of Pathology, Atomic Disease Institute, Nagasaki
University School of Medicine
12-4 Sakamoto-machi, Nagasaki 852 Japan
- 2) Department of Pathology, Red Cross Nagasaki A-bomb Hospital
3-15 Mori-machi, Nagasaki 852 Japan
- 3) Department of Pathology, National Nagasaki Central Hospital
Kamikuwara, Omura 855 Japan
- 4) First Department of Surgery, Nagasaki University School of
Medicine
12-4 Samamoto-machi, Nagasaki 852 Japan
- 5) Department of Radiation Biophysics, Atomic Disease Institute,
Nagasaki University School of Medicine
12-4 Sakamoto-machi, Nagasaki 852 Japan

Received for publication, July 11, 1986

ABSTRACT

In this paper, 4 cases of rectal cancer possibly induced by radiotherapy for cervical cancer are reported, with special reference to radiation-carcinogenesis relationship. For detecting radiation-induced rectal cancer, we reviewed 34,783 cases with tumor or tumor-like lesion registered to the Nagasaki Tumor Registry Committee. As a result, we found 4 cases reported here from 296 female cases of rectal cancer, the rate being 1.35%. The latent period ranged from 10 to 27 years, the mean being 19.5 years. In all of these 4 cases,

関根 一郎, 川瀬 義久, 大井 順二, 伊藤 正博, 西森 一正, 高原 耕, 藤井 秀治,
下山 孝俊, 富田 正雄, 奥村 寛

tumors were located in the anterior wall of the rectum 3-6 cm from the anal verge. Macroscopically, they were Borrmann II-III type. Microscopically, they were well differentiated adenocarcinoma, some of which revealed mucinous carcinoma in parts. The rectal wall of three resected cases showed fibrosis of the submucosa and surrounding tissue, where the blood vessels showed sclerosis and hyalinization, due to previous irradiation.

INTRODUCTION

Carcinogenesis as a late effect of radiotherapy is the most important issue. Radiotherapy is often performed for cervical cancer before and after surgery or independently. Cancer of the rectum¹⁾, cancer of the bladder²⁾, cancer of the uterine body³⁾, sarcoma⁴⁾, etc., have been known generally, though rare, as cancers induced by irradiation for cervical cancer. Among those, cancer of the rectum is most frequent by the literature.⁵⁾⁶⁾ Accumulation and analysis of cases of rectal cancer after radiation therapy seem to indicate as to how such patients should be followed up in their courses. CASTRO *et al*¹⁾ analysed 26 cases of colorectal cancer following irradiation for cervical and uterine cancers in 1973. KARAKI *et al*⁷⁾ summarized 74 cases of radiation induced colorectal cancer previously reported abroad including Castro's 26 cases. However, there are a few reports describing detailed clinicopathological findings in each case. The purpose of this paper is to report 4 cases of rectal cancer possibly induced by radiotherapy for cervical cancer, especially concerning radiation-carcinogenesis relationship.

MATERIALS AND METHODS

For the purpose of detecting rectal cancer induced by radiotherapy for cervical cancer, we reviewed 34,783 cases with tumor or tumor-like lesion registered to the Nagasaki Tumor Registry Committee during eight years from 1973 to 1980 covering the central and southern areas of Nagasaki Prefecture. The criteria used for selection of radiation induced rectal cancer cases were 1) past history of radiation therapy for cervical cancer, 2) evidence of rectal cancer and 3) relatively long latent period. Cases with possible recurrence and/or metastasis of cervical cancer were discarded. For the detected cases, histological specimens were prepared from paraffin blocks and reexamined microscopically by several staining methods. As classification of the tumor by macroscopic appearance, Borrmann's classification which is usually applied to gastric cancer, was used.

As to microscopic diagnosis and degree of invasion of carcinoma, general rules for clinical and pathological studies on cancer of colon, rectum and anus by Japanese Research Society for Cancers of Colon and Rectum were applied.⁸⁾

RESULTS

In 34,783 cases registered, 720 cases of rectal cancer including 296 female cases were selected. Among these female cases, 4 cases of probable radiation induced rectal cancer were detected. The rate of radiation-induced rectal cancer to all rectal cancer of female was 1.35%. A summary of these 4 cases is given in Table 1. The latent period ranged from 10 to 27 years, the mean being 19.5 years. The age at diagnosis or of operation for rectal cancer ranged from 56 to 72, the mean being 65.5 years.

Table 1. Rectal cancer following irradiation for cervical carcinoma (Nagasaki Tumor Tissue Registry 1973~1980)

	Cervical carcinoma				Rectal cancer						
	Age	Operation	Radiation therapy	Dose	Time	Latent period(y)	Onset	Symptom	Location	Macroscopic type	Histologic type
1	69	(+)	(+)	?	1953	27	1980	Constipation	ant.4-5cm	Borr III	pap-tub
2	56	(+)	External Internal	?	1956	19	1975	Difficulty of defecation	ant.6cm	Borr II	pap-tub
3	72	(-)	Radium	5875mg.h	1953	22	1975	Vaginal tumor	ant. ?	Borr II	pap-tub(b.)
4	65	(-)	X-ray Radium	4.89Gy 7200mg.h	1963	10	1973	Anal bleeding	ant.3cm	Borr III	pap-tub-muc

ant: anterior wall, pap: papillary, tub: tubular, muc: mucinous

CASES

Case 1 69 year-old female

In 1953, hysterectomy was performed under a diagnosis of cervical cancer and this was followed by radiotherapy. The dose and method of irradiation are unknown. Thereafter, vesico-vaginal fistulas developed and the patient needed diapers. Since then, there was a trend of constipation. In June 1980, constipation was aggravated and the stool was confined in size. Digital palpation disclosed a circumferential papillary tumor at the site approximately 4-5cm from the anal verge. A diagnosis of adenocarcinoma was made by biopsy and proctectomy was performed. The rectum was severely adhered to the vagina and bladder wall. The Borrmann-III tumor measuring 8.0 x 7.0cm was located almost circumferentially at the anterior wall of the lower rectum. Histologically, the

tumor was moderately differentiated adenocarcinoma, consisting of well differentiated parts with papillary and glandular proliferation of large atypical cylindrical epithelium, moderately differentiated parts with formation of small glands by cubic-cylindrical epithelium, and poorly differentiated parts forming cell masses (Fig. 1). Invasion pattern was INF α , lyo vo, aw(-) ow(-) ew(+). Fibrosis of the submucosal tissue around the tumor was seen and the vessels showed fibrous or hyalinous thickening.

Case 2 56-year old female

In 1956, simple hysterectomy was performed under a diagnosis of cervical cancer stage III. After the operation, external and intravaginal irradiation was performed, but the dose and method of irradiation are unknown. Around this time, she received treatment for anal fistula. After the radiotherapy, stool was confined in size. Since 1962, bloody stool was noted occasionally but it was considered as hemorrhoids. In September 1975, the patient was examined for difficulty in defecation. Endoscopy disclosed a cauliflower-shaped tumor at the right anterior wall 6cm from the anal verge. A diagnosis of adenocarcinoma was made by biopsy. Proctectomy was performed. A Borrmann II tumor measuring 2.4 x 1.9cm was present in a region, 5.5cm from the anal verge. Histologically, it was well differentiated adenocarcinoma with papillary or glandular proliferation of hyperchromatic atypical large cylindrical epithelium. Part of the tumor revealed the appearance of mucous adenocarcinoma forming dilatation and degenerative necrosis of the gland due to excessive production of mucin (Fig. 2). Fibrosis was observed in the deeper part of the tumor and fibrous and hyalinous thickening of blood vessels was occasionally seen (Fig. 3).

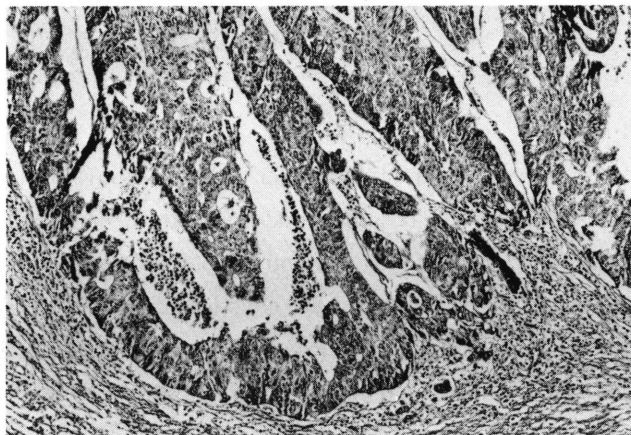


Fig. 1. Case 1. This case showed well, moderately and poorly differentiated adenocarcinoma, in which well differentiated part is predominant. (H. E. 130 x)

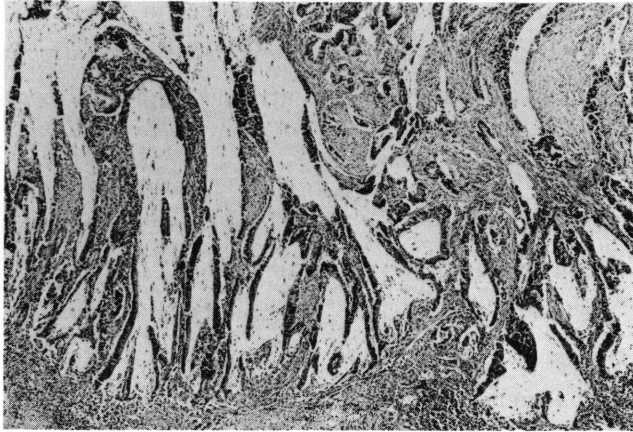


Fig. 2. Case 2. Mucinous adenocarcinoma with dilatation and degeneration of glands due to excessive production of mucin was seen in part though well differentiated adenocarcinoma composed of papillary and glandular proliferation of atypical cylindrical epithelia was predominant in this case. (H. E. 25 x)

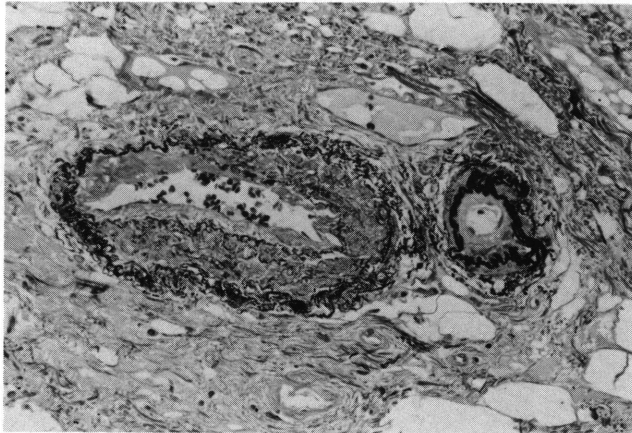


Fig. 3. Case 2. In the deeper part of the rectum, blood vessels showed fibrous thickening and hyalinization surrounded by fibrosis. (Elastic stain. 250 x)

Case 3 72-year old female

In 1953, radiotherapy with radium 5,874mg. hr was performed under a diagnosis of cervical cancer stage IV. The clinical course thereafter was satisfactory. However, yellowish discharge developed since 1975 and a protrusive lesion appeared at the posterior vaginal wall in February 1976. A soft tumor was found circumferentially at the anterior wall by rectal examination and was diagnosed as adenocarcinoma by biopsy. The general

condition was aggravated thereafter and the patient died in May 1976. Autopsy was not performed. Biopsy specimens showed well differentiated adenocarcinoma with papillary or glandular proliferation of hyperchromatic atypical cylindrical epithelium in necrotic tissue.

Case 4 65 year-old female

In April 1963, the patient received intravaginal irradiation with radium 7,200mg. hr and deep irradiation with x-ray 306 rad x 16 times (total 48.96 Gy) under a diagnosis of cervical cancer. The progress thereafter was satisfactory except for infrequent anal hemorrhage. In November 1973, the patient noticed anal hemorrhage. She had no diarrhea nor tenesmus. A tumor was found at the anterior wall 3cm from the anal verge by rectal examination. A diagnosis of adenocarcinoma was made by biopsy and proctectomy was performed. The rectum was fibrously adhered with the uterus. Recurrence of uterine cancer was not noted. The resected specimen showed a Borrmann-III tumorous lesion measuring 2.5 x 2.2cm at the anterior wall 3cm from the anal verge. A part of tumor showed a smooth surfaced polypoid lesion. In the rectal mucosa near the tumor, scattered lesions of irregular-shaped shallow ulcer were seen (Fig. 4). Histologically, the tumor was

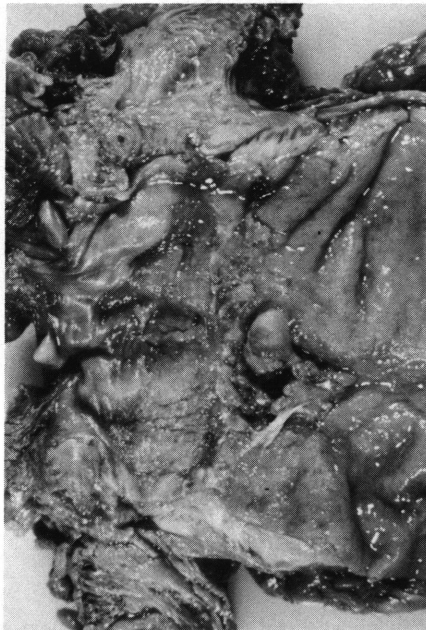

Fig. 4. Case 4. Irregularly shaped carcinomatous lesion, Borrmann-III, is present on the anterior wall of the rectum, measuring 2.5 x 2.0 cm at 3 cm from anal verge. A smooth surfaced polypoid lesion is seen in a part of the tumorous lesion. In the rectal mucosa near the tumorous lesion, some scattered shallow ulcerative lesions are seen.

well differentiated adenocarcinoma wherein the atypical cylindrical epithelium formed irregular shaped glands and/or papillary proliferation. In a polypoid lesion, the appearance of mucinous carcinoma in which tumor cells floated in mucin lake was seen (Fig. 5). Submucosal edema and fibrosis were presented in the lower half of the resected specimen. In the ulcerative lesion, the regenerative mucosa was formed (Fig. 6). Some blood vessels in the rectal wall near the tumor showed fibrous thickening and hyalinization which were tortuous and embedded in increased elastic fibers (Fig. 6, 7).

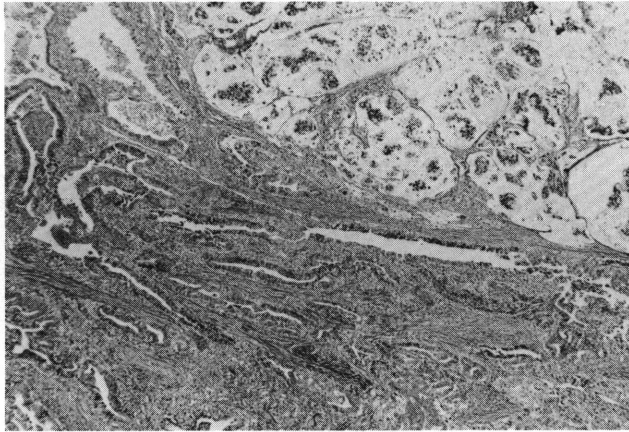


Fig. 5. Case 4. Histologically, this case is also well differentiated adenocarcinoma. Infiltrating tubular carcinomatous lesion and mucinous carcinomatous lesion with mucin lake and floating malignant cells (in upper right) are seen. (H. E. 25 x)

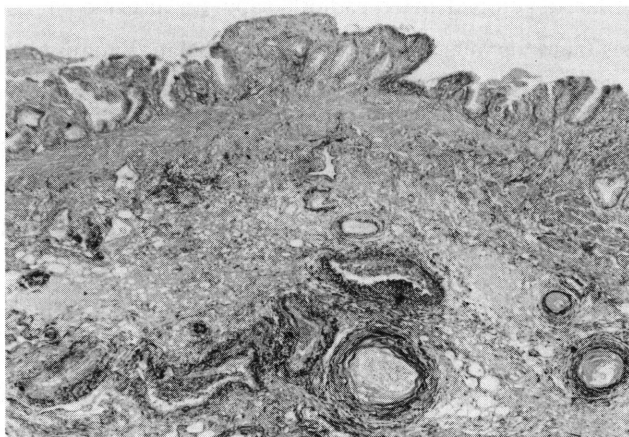


Fig. 6. Case 4. In the ulcerative lesion, regenerative mucosa is formed. The muscularis mucosa is thickened. In the submucosa, fibrously thickened blood vessels are seen. (Elastic stain. 25 x)




Fig. 7. Case 4. Blood vessels are thickened. An artery shows hyaline intimal thickening with disruption of internal elastic lamina. A small vein shows fibrous thickening surrounded by proliferating elastic fibers. (Elastic stain. 250 x)

DISCUSSION

Cervical cancer as well as breast cancer and cancer of head and neck is a malignant tumor that has been a common target of radiotherapy. Two cases of rectal cancer were first reported by SLAUGHTER and SOUTHWICK⁹⁾. In 1973, CASTRO *et al*¹¹⁾ collected 26 cases of colorectal cancer that developed after radiotherapy for uterine or cervical cancer and reviewed these cases from various aspects. In Japan, 290 malignant tumor cases following radiotherapy were collected by a nationwide questionnaire survey by SAKAI *et al*.⁵⁾ Of the 140 primary malignant cases among the collected cases, uterine cancer reportedly was most frequent being noted in 59 cases (42.1%). Recto-sigmoid colon cancer as an induced cancer was seen in 10 of 59 cases. MAEHARA *et al*⁶⁾ reported that, of the 19 possibly radiation induced tumor cases, cervical cancer as primary malignancy was in 10 cases and among these rectal cancer as induced cancer was most frequent being seen in 4 cases. NISHI¹⁰⁾ reported 52 cases of radiation-proctocolitis probably related to carcinogenesis in 142 cases collected by a questionnaire survey of non-tumorous disorders related to development of colorectal cancer.

SEYDEL¹¹⁾ reported that colorectal cancer developed in 3 cases of 354 cervical cancer 5-year survival individuals, the incidence being 0.85%. PALMER and SPRATT¹²⁾ observed the

occurrence of rectal cancer in 2 cases among 471 cervical cancer cases who received radiotherapy and survived 10 years or more and considered that the incidence was not different from the expected value. DICKSON¹³⁾ reported that, among 923 cases who survived 5 years or more following radium irradiation for cervical cancer, death from rectal cancer was seen in 12 cases versus the expected value of 4.35 and 13 cases of colon cancer versus the expected value of 9.94, showing some increase from the expected value. SANDLER¹⁴⁾ also emphasized high risk of colorectal cancer and recommended sufficient observation of the progress. In our previous screening of multiple cancer from among 13,000 autopsy cases in Nagasaki University and related hospitals,¹⁵⁾ we found only one case of induced rectal cancer among 3 cases of combined cervical cancer and rectal cancer.¹⁶⁾ The four cases in this study were extracted from 296 female cases of rectal cancer in 34,783 registered specimens, the rate being 1.35%.

The mean latent period from radiotherapy to the detection of induced cancer ranged from 5 to 30 years and was 10 years or more in 69.2% according to CASTRO *et al.*¹⁾ In 10 cases of rectal cancer following radiotherapy studied by SAKAI *et al.*⁵⁾ ranged from 10 to 24 years, the mean being 18.6 years. In MAEHARA *et al.*'s 4 cases, it was from 21 to 25 years with the mean of 23 years.⁶⁾ In our 4 cases, the latent period ranged from 10 years to 27 years, the mean being 19.5 years.

The site of rectal cancer was the anterior wall, 3-6cm from the anal verge in all the four cases. The anterior wall of rectum is connected to the vaginal wall through the rectovaginal septum and in contact with the uterus beyond the recto-uterine pouch. Thus, when the cervix uteri is treated by high-dose irradiation, the anterior wall among other regions in the rectum would be exposed to a higher dose. In radiation proctitis, the anterior wall is the most affected region in the rectum.¹⁷⁾ Although there has been no report with attention to the location of tumor in collection of rectal cancer cases following radiotherapy for cervical cancer, most of case reports of rectal cancer with indication of site have shown that the sites in most cases were anterior wall 3-7cm from the anus.¹⁸⁾¹⁹⁾

In terms of histological images, CASTRO¹⁾ paid attention to the rate of mucous cancer as high as 58% in comparison with about 10% in ordinary rectal cancer. He further considered that 92.8% of cases with mucous cancer had radiation induced proctocolitis in view of the clinical symptoms and histological findings, and emphasized the relationship between mucous cancer and radiation induced proctocolitis. However, there have been few scientists except Castro who paid attention to mucous adenocarcinoma. In our cases, 1 case underwent only biopsy and 3 cases proctectomy. In the case of biopsy, all we could say was well differentiated adenocarcinoma. In 3 cases with surgical specimens, his-

tological findings were well or moderately differentiated adenocarcinoma with papillo-tubular proliferation, and there was no case wherein mucous cancer was predominant. In case 4, an area of mucous cancer was seen in part of the tumor.

As a histological characteristic of radiation induced cancer, changes by irradiation in the surrounding area of tumor can be given. Many of case reports of rectal cancer describe the changes of the interstitium.¹⁸⁾¹⁹⁾²⁰⁾ Various changes from the mucosa to the serosa have been known in late radiation enteropathy.²¹⁾²²⁾ We also observed such changes as fibrosis and sclerosis of vessels in our cases.

We could find no dysplastic changes in the colorectal mucosa related to carcinogenesis in these resected cases except atrophy, architectural changes and cystic dilatation of glands.²³⁾ It is recommended that the study of carcinogenesis of the radiation induced colorectal cancer should be performed from various morphological aspects.

REFERENCES

- 1) CASTRO, E. L. B., ROSEN, P. P. and QUAN, S. H. Q. (1973) Carcinoma of large intestine in patients irradiated for carcinoma of cervix and uterus. *Cancer* 31 : 45-52.
- 2) DUNCAN, R. E., BENNETT, D. W., EVANS, A. T., ARON, B. S. and SCHELLHAS, H. F. (1977) Radiation-induced bladder tumors. *J. Urolol.* 118 : 43-45.
- 3) CZESNIN K. and WRONKOWSKI, Z. (1978) Second malignancies of the irradiated area in patients treated for uterine cervix cancer. *Gynecol. Oncol.* 6 : 309-315.
- 4) PINKSTON, J. A. and SEKINE, I. (1982) Postirradiated sarcoma (malignant fibrous histiocytoma) following cervix cancer. *Cancer* 49 : 434-438.
- 5) SAKAI, K., HINATA, H., KITAMURA, T., SHIINA, M., INAKOSHI, H., SAITO, A., ODANO, I. and TAKAHASHI, M. (1981) A survey on radiation-induced cancer following radiotherapy in Japan, *Nippon Act. Radiol.* 41 : 24-32.
- 6) MAEHARA, Y., SAKURAI, I., HARUYAMA, Y., NISHIO, M., SAITO, A. and KAGAMI, Y. (1984) Study on irradiation-induced malignant tumors. (author's translation) *Gann No Rinsho* 30 : 157-161.
- 7) KARAKI, Y., NAGASE, T., HOKARI, I., HASEGAWA, S., TAZAWA, K., ITO, H., FUTIMAKI, T. and KOIZUMI, T. (1982) One case of irradiation-induced rectal cancer and statistical observation of 74 reported cases abroad. (author's translation) *Gann No Rinsho* 28 : 1309-1319.
- 8) Japanese Research Society for Cancer of Colon and Rectum. (1977) General rules for clinical and pathological studies on cancer of colon, rectum and anus. *Kanahara Shuppan*, Tokyo.
- 9) SLAUGHTER, D. P. and SOUTHWICK, H. W. (1957) Mucosal carcinomas as a result of irradiation. *Arch. Surg.* 74 : 420-429.
- 10) NISHI, M. (1982) Report of questionnaire survey of non-tumorous disorders probably related to development of colorectal cancer. (author's translation) *Nippon Rinsho Komon Gakkaishi* 35 : 192.

- 11) SEYDEL, H. G. (1975) The risk of tumor induction in man following medical irradiation for malignant neoplasm. *Cancer* 35 : 1641-1645.
- 12) PALMER, J. P. and SPRATT, D. W. (1956) Pelvic carcinoma following irradiation for benign gynecologic diseases. *Am. J. Obstet. Gynecol.* 72 : 497-505.
- 13) DICKSON, R. J. (1972) Late results of radium treatment of carcinoma of the cervix. *Clin. Radiol.* 23 : 528-535.
- 14) SANDLER, R. S. and SANDLER, D. P. (1983) Radiation-induced cancers of the colon and rectum : assessing the risk. *Gastroenterol.* 84 : 51-57.
- 15) SEKINE, I., KAWASE, Y., OOI, J., MATSUMOTO, K., SHINKAI, K., HONDA, N., ISEKI, M., SHIMIZU, K., KISHIKAWA, M., NISHIMORI, I. and OKURURA, Y. Development of malignant tumors following irradiation of preexisting tumors-Study based on autopsy cases of double cancer-*J. Radiat. Res.* 27 : 151-162, 1986.
- 16) SEKINE, I., TAKIGUCHI, K., NISHIMORI, I., OOGI, K., TAKAHARA, O. and OOTSURU S. (1983) Rectal cancer possibly subsequent to irradiation for cervical carcinoma. *Nippon Shokakibyo Gakkaishi* 80 : 897-899.
- 17) PALMER, J. A. and BUSH, R. S. (1976) Radiation injuries to the bowel associated with the treatment of carcinoma of the cervix. *Surg.* 80 : 458-464.
- 18) MACMAHON, C. E. and ROWE, J. W. (1971) Rectal reaction following radiation therapy of cervical carcinoma : particular reference to subsequent occurrence of rectal carcinoma. *Ann. Surg.* 173 : 264-269.
- 19) QIZILBASH, A. H. (1974) Radiation-induced carcinoma of the rectum. A late complication of pelvic irradiation. *Arch. Pathol.* 98 : 118-121.
- 20) GREENWALD, H., H., BARKIN, J. S., HENSLEY, G. T. and KALSER, M. H. (1978) Cancer of the colon as a late sequel of pelvic irradiation. *Am. J. Gastroenterol.* 69 : 196-198.
- 21) O'CONNOR, T. W., ROMBEAU, J. L., LEVIN, H. S. and TURNBELL, R. B. (1979) Late development of colorectal cancer subsequent to pelvic irradiation. *Dis Colon Rectum* 22 : 123-128.
- 22) U. S. Energy Research and Development Administration (1975) An Atlas of Radiation Histopathology. Ed. White, D. C. Technical Information Center.
- 23) SEKINE, I., IKEYAMA, M., SUMI, C., SHIKAI, K., ITO, M., NISHIMORI, I., TAKAHARA, O., SHIMOYAMA, T., TOMITA, M. and OKUMURA, Y. (1985) Histo-pathological studies of the colorectal mucosa after radiation therapy for malignant tumors in the pelvic organs. *Nagasaki Igk. Z.* 60 : 219-223.