

Clinico-pathological Characteristics of Early Cancer of the Cardia

Yuzo UCHIDA*, Kazuhide TOMONARI, Nobuhiko FUJISHIMA,
Tetsuo HADAMA, Okihiko SHIBATA, Joji SHIRABE,
Takeshi FURUSAWA**

* *The Second Department of Surgery,
Oita Medical College, Oita, Japan*

** *Furusawa Hospital for Gastro-Intestinal
Diseases, Oita, Japan*

Received for publication, July 18, 1986

Abstract: Unique pathological feature of early cancer in the region of cardia has been discussed in comparison with early cancer in the rest of the upper third region of the stomach. Early cancer originated in this region mostly shows protruded or superficial elevated type of well differentiated adenocarcinoma histologically. Vascular invasion is as rare as lymph node metastasis in this area. Therefore, if one want to find out minute early cancer in this region, one must perform endoscopic examination using a forward viewing panendoscope and abrasive cytology with capsule even for those who do not complain swallowing difficulty. Radical treatment can be expected by proximal gastrectomy with dissection of lymph nodes for those cases of early cancer in the region of cardia.

Key words : Early cancer, cardia

INTRODUCTION

The chance of early diagnosis of gastric cancer increased greatly by the technical advance of radiological and endoscopic examination in the recent years.^{1,2)} Nevertheless, the chance of early diagnosis in the region of cardia is still low, compared with other regions of the stomach. Therefore, its clinicopathological feature is not yet fully understood.

In this article, the characteristics of early cancer of the cardia would be explained

内田 雄三*, 友成 一英, 藤島 宣彦, 葉玉 哲生, 柴田 興彦, 調 壺治, 古沢 毅

MATERIAL AND METHODS

The Oita Medical College Hospital was opened in October 1981. In the following 4 years and 6 months, gastrectomy has been performed on 183 cases of gastric cancer (197 lesions) in the Second Department of Surgery. Of 197 lesions resected, there were 89 lesions of early gastric cancer, as defined by "The General Rules for the Gastric Cancer Study in Surgery and Pathology",³⁾ including 57 mucosal layer and 32 submucosal layer lesions.

In the study of gastric cancer, the stomach is divided into three anatomical regions,³⁾ i.e. the upper third(C), middle third(M), and lower third(A). The upper third includes both the cardiac area and fundus. No anatomical definition has been established so far on this cardiac area. In 1973, NISHI et al.⁴⁾ called this area as cardiac region or the region of cardia because cardiac glands are found within 2 cm above and 2cm below the esophago-gastric junctional line (Z-Z line), and emphasized the need of differentiation from the so-called Region C³⁾ of the stomach. In this article, the location of cancer is divided into 4 regions; Cardia, upper third(C), middle third(M), and lower third(A) for further discussion.

Location of 197 carcinomas is shown in Figure 1. There were 95(48.2%) in the region A, 55(27.9%) in the region M, 37(18.8%) in the region A, and only 10(5.1%) in the region of cardia. The percentage of early cancer in each region was 54.7% in the region A, 49.0% in the region M, 21.6% in the region C and 20.0% in the cardia (Fig. 1). This means that only 2 cases of early cancer were found in the cardiac region among 183 cases of gastric cancer (197 lesions) resected in our department in 4 years and 6 months. Since the number is too small for statistics, 6 more lesions resected in other hospitals by our team were added, and 8 cases in total of early cancer located in the cardiac region were analyzed and discussed. Clinico-pathological findings of these lesions were classified and described according to "The General Rules for the Gastric Cancer Study in Surgery and Pathology"³⁾.

RESULTS

Of 89 lesions of early gastric cancer, 57(46.0%) were located in the mucosal layer (m-early cancer). M-early cancer was found in 39 of 52 lesions in the region A(75.0%) in 16 of 27 lesions in the region M(69.3%), and only one of 8 lesions in the region C(12.5%). The

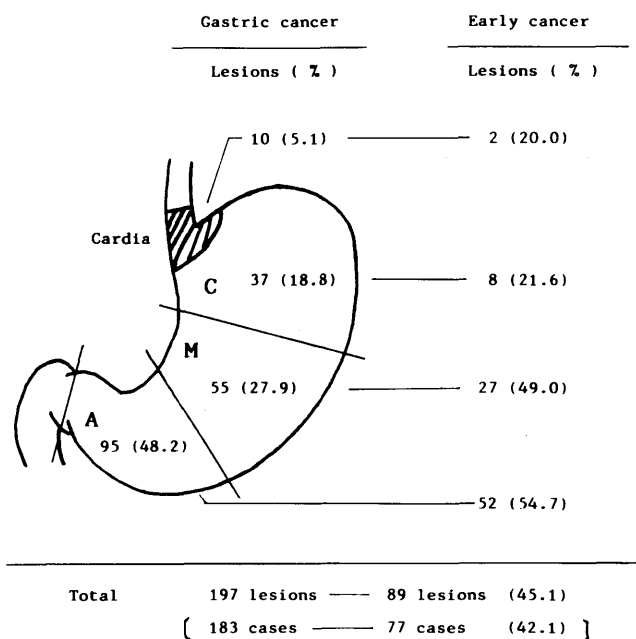


Fig. 1. Location of the gastric cancer

figures show how difficult to find cancer of the region C in the very early atage of m-early cancer, compared with early cancer in the region A and M.

1. Macroscopic findings: Macroscopic findings of early gastric cancer can be divided into Group I (protruded type and superficial elevated type) and Group II (superficial depressed type and excavated type). If these two findings were coexisted, then the predominant findings were adopted.

Table 1 demonstrates macroscopic findings of early cancer in each region. In every region, 69 to 80% of early cancer belonged to Group II. It is remarkable that 75% of early cancer in the region M and C were of superficial depressed type.

2. Microscopic findings: Microscopic findings of early gastric cancer were divided into three groups: Group A, papillary adenocarcinoma, well differentiated tubular adenocarcinoma, Group B, moderately differentiated tubular adenocarcinoma, and Group C, poorly differentiated adenocarcinoma, signet-ring cell carcinoma. Their microscopic findings are shown in Table 2: In the region A, 51.9% of lesions presented histology of well differentiated adenocarcinomas, and 26.9% were poorly differentiated carcinomas. In region C, however, 50.0% of lesions were poorly differentiated carcinomas, and only 37.5% were well differentiated adenocarcinomas.

Table 1. The macroscopic type of early cancer of the stomach
Number of lesions(%)

Regions of the stomach		A	M	C	Cardia	Total
Macroscopic type	Group I*	16 (30.8)	5 (18.5)	2 (25.0)	1	24 (27.0)
	Group I**	36 (69.2)	22 (81.5)	6 (75.0)	1	65 (73.0)
Total		52 (100.0)	27 (100.0)	8 (100.0)	2	89 (100.0)

* Group I: Protruded type and superficial elevated type

** Group I: Superficial depressed type and excavated type

Table 2. The histologic type of early cancer of the stomach
Number of lesions(%)

Regions of the stomach		A	M	C	Cardia	Total
Histologic type	Group A*	27 (51.9)	13 (48.1)	3 (37.5)	2	45 (50.6)
	Group B**	11 (21.2)	3 (11.1)	1 (12.5)	0	15 (16.8)
	Group C***	14 (26.9)	11 (40.8)	4 (50.0)	0	29 (32.6)
Total		52 (100.0)	27 (100.0)	8 (100.0)	2	89 (100.0)

* Group A: Papillary adenoca. and well diff. tub. adenoca.









** Group B: Moderately diff. tub. adenoca.

*** Group C: Poorly diff. adenoca. and signet-ring cell ca.

3. Findings of early cancer of the cardiac region: Table 3 shows pathological findings of 8 lesions in the cardia. All patients were male in age 55 to 68 (62.4 on the average). The motive of clinical visit was found in only one case who complained swallowing difficulty, and none among other 7 cases. Early cancer of the cardia was found accidentally in 5 cases during the follow-up study of other illness including gastric ulcer and liver cirrhosis. In other 2 cases it was found by group by check-up. Radiological examination revealed cardiac lesions in 5 cases, but failed to find in 3 other cases. Endoscopic examination using a forward viewing panendoscope accurately identified carcinomatous lesions in every case, and endoscopic biopsy confirmed the diagnosis of adenocarcinoma. Total gastrectomy was performed in 2 of 8 cases, and proximal gastrectomy in 6 cases as treatment. In the latter esophagostomy was added in 3 cases, and jejunal interposition in 3 others to prevent reflux esophagitis.

In the resected specimens, the size of lesions ranged from 1.0×0.5cm to 3.0×3.0cm. Pathological lesions were located in the site of the lower esophagus in Case 1, and in the site of the stomach in Case 8, but in the other 6 cases (Case 2, 3, 4, 5, 6, and 7) the lesions

Table 3. Eight cases of early cancer of the cardia

No.	Age Sex	Location of the lesion	Macroscopic type and size	Histologic findings	Metastasis
1)	57 M		protruded 1.7 x 1.5 cm (E)	well diff. tub. -adenoca. sm, ly ₀ , v ₀	H ₀ , P ₀ n ₀
2)	61 M		superf. elevated 1.8 x 1.5 cm (C=E)	well diff. tub. -adenoca. sm, ly ₀ , v ₀	H ₀ , P ₀ n ₀
3)	65 M		superf. elevated 1.4 x 1.1 cm (C=E)	well diff. tub. -adenoca. sm, ly ₀ , v ₀	H ₀ , P ₀ n ₀
4)	59 M		superf. elevated 1.0 x 0.5 cm (C>E)	well diff. tub. -adenoca. sm, ly ₀ , v ₀	H ₀ , P ₀ n ₀
5)	55 M		superf. depressed 3.0 x 3.0 cm (C>E)	well diff. tub. -adenoca. sm, ly ₀ , v ₀	H ₀ , P ₀ n ₀
6)	60 M		superf. depressed 1.4 x 2.5 cm (C>E)	well diff. tub. -adenoca. m, ly ₀ , v ₀	H ₀ , P ₀ n ₀
7)	75 M		superf. elevated 1.3 x 1.0 cm (C>E)	well diff. tub. -adenoca. sm, ly ₀ , v ₀	H ₀ , P ₀ n ₀
8)	67 M		superf. elevated 2.0 x 2.0 cm (C)	well diff. tub. -adenoca. m, ly ₀ , v ₀	H ₀ , P ₀ n ₀

() : Site of carcinoma, C : Cardia, E : Esophagus

involved the esophago-gastric junctional line, as defined by NISHI et al. as early cancer at the esophagogastric junctional area.

Macroscopic classification : In one case (Case 1) the lesion was of protruded type, in 6 cases superficial elevated type and in the other one (Case 5) superficial depressed type.

Histological findings : In all cases well differentiated tubular adenocarcinoma was confirmed histologically. Cancer invasion was limited to the mucosal layer in 2 cases, but it extended to the submucosal layer in 6 cases, although only a small part of lesion reached the submucosal layer leaving the rest in the mucosal layer in 5 of these 6 cases ($m > sm$). No metastasis was found in the dissected lymph nodes. Neither liver metastasis nor peritoneal dissemination.

Two of 8 cases died of other illness, but the rest are well, showing no sign of recurrence.

DISCUSSION

Changeableness of histologic pattern in the course of progressive cancer⁵⁾⁶⁾, or multipotency of cancer cells⁷⁾ has been recognized in the cancer cells of the stomach. Therefore, it is mandatory to analyze and discuss on early cancer in order to compare the characteristics of various cancer initiated from different regions.

Morphological difference of early cancer depending on the site of origin, the area of pyloric glands and the area of fundic glands, has been reported by many scholars⁸⁾⁹⁾¹⁰⁾ and confirmed by our present data.

NISHI et al.⁴⁾ named the area within 2cm above and 2cm below the esophagogastric junctional line as the region of cardia, or cardiac area, because of the distribution of the cardiac glands, and proposed to differentiate it from the rest of the upper third region(C) of the stomach.

In this article, those carcinomas located mainly in this area were regarded as carcinomas arising from the cardiac region, and their findings were compared with those of carcinomas of the region C.

While 75% of early cancer in the region C belonged to superficial depressed type, 7 of 8 cases in the region of cardia revealed protruded or superficial elevated type. And 50% of the former were poorly differentiated carcinomas and 25% were well differentiated adenocarcinomas, but all the latter were well differentiated adenocarcinomas. The same trend was found in all 13 cases¹¹⁾ reported in Japan in the past. This fact indicates that

early cancer in the region of cardia has a better chance to be diagnosed by endoscopic examination. Abrasive cytology with capsule¹²⁾ is regarded as a potent technique to find early cancer in this area, if one consider the unique anatomical feature of the region.

In 6 of 8 cases (75%) of early cancer in the region of cardia, invasion of cancer reached the submucosal layer. However, neither vascular invasion nor lymph node metastasis was found at all. This trend coincides with the findings in 13 reported cases¹¹⁾ in Japan, and differs from the features of early cancer in the so-called Region C. Therefore, radicality of surgical removal can be expected in early cancer of this area by proximal one half resection of the stomach and the abdominal esophagus added by dissection of the perigastric lymph nodes in the upper half and lymph nodes around the left gastric artery. At reconstruction, jejunal interposition between the residual esophagus and the anterior wall of the residual stomach should be performed to prevent reflux esophagitis following proximal gastrectomy.

REFERENCES

- 1) KIDOKORO, T.: Frequency of resection, metastasis and five-year survival rate of early gastric carcinoma in a surgical clinic. *Early gastric cancer, GANN Monograph on Cancer Research* 11: 45-49, University of Tokyo Press, Tokyo, 1971.
- 2) TAKAGI, K.: Progress of diagnosis of early gastric cancer. *Diagnosis and Treatment*, 66: 202-208, 1978.
- 3) JAPANESE RESEARCH SOCIETY FOR GASTRIC CANCER: The general routes for the gastric cancer study. Kanehara, Tokyo, 1985.
- 4) NISHI, M., KAJISA, T., AKUNE, T. et al.: Definition of the cardiac region and esophagogastric junctional area. *Surgical Diagnosis and Treatment*, 28: 1328-1338, 1973.
- 5) KOTAKE, Y.: Histological and electron microscopical studies on experimentally induced carcinoma in the glandular stomach of rats, especially in fundus region. *Nagasaki Igakkai Zasshi*, 52: 81-99, 1977.
- 6) KOTAKE, Y., UCHIDA, Y., TOBINAGA, K. et al.: Clinicopathological significance of the histological pattern at the peripheral area of gastric cancer in comparison with the dominant pattern. *Nagasaki Igakkai Zasshi*, 52: 276-285, 1977.
- 7) UCHIDA, Y., ROESSNER, A., SCHLAKE, W. et al.: Development of tumors in the glandular stomach of rats after oral administration of carcinogens. II. Different cell types in antral carcinoma as revealed by electron microscopy. *Zeitschrift für Krebsforschung und Klinische Onkologie*, 87: 213-228, 1976.
- 8) KATO, Y., SUGANO, H., NAKAMURA, K.: Characteristics of cardiac carcinoma (adenocarcinoma), from the viewpoint of pathology. *Journal of Clinical Surgery*, 34: 1851-1856, 1979.
- 9) UCHIDA, Y., ICHIMANDA, M., SHIBATA, O. et al.: Carcinoma of the esophagogastric junctional area. *The Japanese Journal of Clinical and Experimental Medicine*, 58: 2874-2879, 1981.

- 10) LAURÉN, P.: The two histological types of gastric carcinoma ; diffuse and so-called intestinal type carcinoma ; at attempt at a histoclinical classification. *Acta Pathol. Microbiol. Scand.* , 64 : 31-49, 1965.
- 11) UCHIDA, Y., ICHIMANDA, M., SHIBATA, O. et al.: Three cases of early cancer at the esophagogastric junctional area. A review of Japanese literature. *The Japanese Journal of Gastroenterological Surgery*, 14 : 1230-1235, 1981.
- 12) ONOZAWA, K., NABEYA, K. : Abrasive cytology with capsule for esophageal cancer. *The Japanese Journal of Gastroenterological Surgery*, 10 : 1-6, 1977.