

## The Boerhaave Syndrome —Report of a case treated operatively—

Toshio MIURA, Hiroyoshi AYABE, Katsunobu KAWAHARA,  
Masatoshi MORI, Toshiyo ISHII, Masao TOMITA

*The 1st Department of Surgery,  
Nagasaki University School of Medicine,  
Nagasaki, Japan*

Received for publication, July 21, 1986

Esophageal perforation is usually associated with ingestion of a foreign body, surgical instrumentation or disrupted esophageal intestinal anastomoses.<sup>(1)</sup> Spontaneous rupture of the esophagus is most often a catastrophic event unless diagnosed promptly and treated with surgical measures, was first described by Boerhaave in 1724. The rarity of the condition is attested to by its reported of only 60 cases collected by Kijima et al. in Japan as of 1975.<sup>(2)</sup>

We wish to report a typical presentation of such a case treated with thoracotomy to repair the tear resulting in survival.

### CASE REPORT

A 38-year-old unmarried Japanese female was admitted to Nagasaki University Hospital on March 29, 1984 with dyspnea and severe anterior chest pain. She was known to have had symptoms of duodenal ulcer disease and gall stone since 1975, and had a history of alcohol abuse, drinking a half bottle of whisky a day during the past few years. She underwent a gastroduodenoscopy to determine the presence of the duodenal ulcer on the same day by her family physician, and drunk a glass of water shortly after the examination, but she did not complain of any symptoms. Two hours later she had drunk a glass of whisky and had immediately become nauseated, vomited a small amount of bright red blood and then suddenly developed dyspnea, peripheral cyanosis, and anterior chest and back pain. She consulted the family physician who was an excellent endoscopist.

---

三浦 敏夫, 綾部 公懿, 川原 克信, 母里 正敏, 石井 俊世, 富田 正雄

The lungs were weak to auscultation in all the left lung field, and there was no tenderness on the abdominal wall. A film of the chest did not reveal the presence of subcutaneous emphysema anywhere, but there was a small opacification at the left lower lung base.

After about one hour, she was noticed to have subcutaneous emphysema of the left supraclavicular region. Immediately she was transferred to the emergency room of our Hospital diagnosed as suspicious perforation of the esophagus.

On admission her general condition was critically ill, but cyanosis had already disappeared by administration of oxygen, and her skin was slightly cool and clammy. She complained of dyspnea, chest pain, thirst and swallowing pain without coughing.

The patient was examined shortly after admission. Her temperature was 37.0°C, and the pulse was 102 per minute, and regular. The blood pressure was 140/110mmHg. The respiratory rate was 45 per minute. The breath sounds were clear to percussion and auscultation, except for the weakness in the left lower lung field. An electrocardiogram was interpreted as being normal. Examination of the abdomen revealed slight epigastric tenderness. There was no guarding or rebound and no mass was palpated. The bowel sounds were hypo-active. The rest of the physical examination was essentially negative. An upright chest film revealed a left pleural effusion, and the presence of subcutaneous emphysema of the neck and mediastinum. Radiographs of the abdomen failed to reveal any evidence of free air. (Fig. 1)

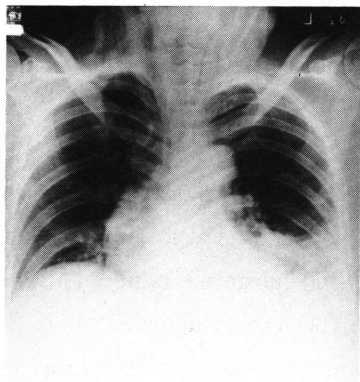
Laboratory results showed an elevated serum amylase of 426I. U. The hematocrit was 41%, the hemoglobin of 14.7gms, the white blood cell count was 6000 per cu. mm., slightly elevated serum GOT of 274, and GPT of 169. The blood sugar level was as high as 355 mg/dl.

Gastrographin esophagrams were then carried out in the supine and left lateral positions and showed leakage in the mediastinum from the esophagus. (Fig. 2) The preoperative diagnosis was post-emetic spontaneous rupture of the esophagus but not instrumental perforation.

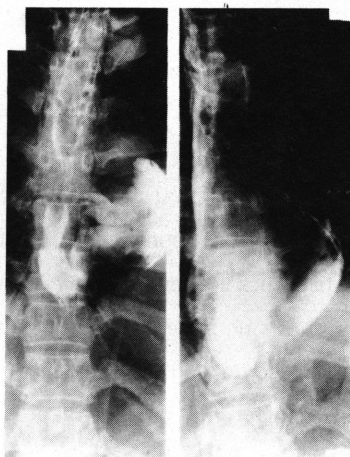
Blood was being cross-matched for the patient and vigorous replacement of fluids and electrolytes under central venous pressure was being done. Hyperalimentation was started through a central venous line. The patient was taken to the operating room three hours after admission and eight hours after the onset of her illness.

She was placed into the left midlateral position and the chest was opened through a left postero-lateral thoracotomy incision between the sixth and seventh ribs. About 300 ml of a turbid and coloured fluid were present in the pleural cavity. Inferior mediastinal

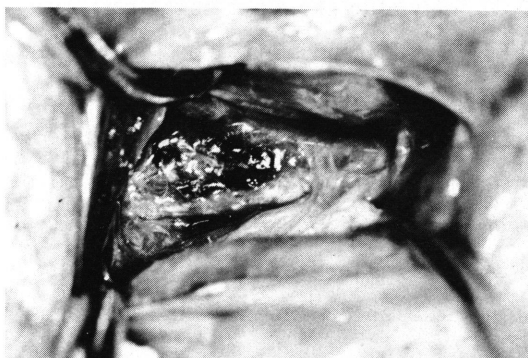pleura formed an egg-sized tumor looking like a cyst. The periesophageal tissues were oedematous and inflamed. An incision was made into the mediastinal pleura, a small amount of foul fluid was noticed but without bleeding. A 2 cm longitudinal, and full-thickness tear was located on the left lateral aspect of the esophagus approximately three cm above the diaphragm. (Fig. 3). A nasogastric tube which had been passed into the stomach was found under direct vision. The edges of the laceration were clearly washed out by saline, and closed in layers with interrupted 3-0 Dexon sutures. Mediastinal pleura was taken over the repair using 3-0 continuous Dexon sutures. The chest was closed



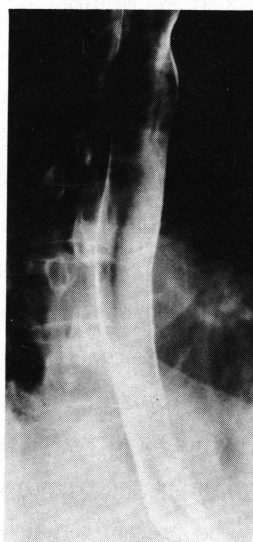**Fig. 1.** Radiograph showing left pleural effusion and cervical subcutaneous emphysema.



**Fig. 2.** Contrast study of the esophagus showing leakage of contrast material in the mediastinum.



**Fig. 3.** Two cm longitudinal, and full-thickness tear was located on the lower esophagus approximately three cm above the diaphragm.



**Fig. 4.** Esophagogram after operation.

leaving a large chest tube which was connected to a suction drainage. An abdominal tube was left into the lower mediastinum through the esophageal hiatus to the left lateral abdominal wall. On the fifth post-operative day, the drainage ceased and tube was removed. Her post-operative course was uneventful. A radiograph of her chest was normal except for minimal pleural thickening. Barium esophagrams were performed on the fourteenth day, and showed a normal esophagram without any leakage and stenosis. (Fig. 4) The patient was discharged three weeks after operation, and returned to full employment two months after.

## DISCUSSION

Since the original description by BOERHAAVE in 1724,<sup>3)</sup> the dramatic nature of the symptoms following spontaneous perforation of the esophagus is well known. The classic triad on presentation is vomiting, mild hematemesis and substernal pain. This disease is not a common one in Japan. A review of 60 cases has been reported by KIJIMA in 1981 with the rate of recovery 50%. DERBES and MITCHELL comprehensively reviewed the subject in 1956 and reported 157 cases collected from the world literature.<sup>4)</sup>

The first clinically correct diagnosis of the spontaneously ruptured esophagus was reported by MEYER in 1859.<sup>5)</sup> COLLIS, HUMPHREYS and BOND reported on the first transthoracic attempt of the surgical repair of the spontaneously ruptured esophagus in 1944.<sup>6)</sup> The patient died in 21 hours after operation and 30 hours after the onset of the perforation. Autopsy revealed a satisfactory closure of the rent in the esophagus. FOGGITT reported a case in which a preoperative diagnosis of spontaneous perforation of the esophagus was made correctly.<sup>7)</sup> He entered the abdomen, pulled the esophagus down and closed the rent in the esophagus. A rubber tube was inserted into the mediastinum, anterior to the esophagus for drainage. A gastrotomy also was performed. The patient died in two days after surgical intervention. In 1947 BARRETT reported the first repair of the perforation of the esophagus.<sup>8)</sup> DORSEY *et al.* reported the first spontaneous rupture of the esophagus in a neonate.<sup>9)</sup> The case reported by ROSS in 1961 was found to have a rupture of the middle third of the esophagus at autopsy. There have been three reported cases of cervical esophageal rupture by MCKEOWN in 1965.<sup>11)</sup> In 1969 WYCHULIS *et al.* from the Mayo clinic, published their experience with instrumental and non instrumental perforations of the esophagus. The presented four cases of postemetic rupture occurring in non-diseased organs with a survival rate of 50 per cent.<sup>12)</sup> In the same year, BERNE *et al.* reported five

cases with five recoveries of interest and high significance in that all of these cases were treated successfully by an abdominal approach.

Their predisposing or associated conditions are abuse of alcohol, use of antabuse, peptic ulcer disease, neurologic disease and hiatal hernia. The common physiological denominator in almost all cases is an explosive act of vomiting or violent retching, often occurring after a large meal, followed with forceful swallowing. A few cases have been reported where vomiting did not occur, but these cases were associated with acts increasing intra-abdominal pressure, such as child-birth, straining at defaecation and a convulsive seizure.<sup>14)15)16)</sup> One case has been reported where massive upper gastro-intestinal haemorrhage was the precipitating factor.<sup>19)</sup> It is usual that Japanese women who seldom abuse whisky developed a disease as shown in this report.

On the basis of an extensive experimental study on the fresh cadaveric esophagi, MACKLER believed that rupture was due to a sudden violent increase in intra-abdominal pressure with explosive expulsion of a large amount of gastric contents into the fully relaxed esophagus, the tear occurring where this massive distension was initially sustained the distal esophagus. It may also be significant that the distal esophagus lacks the buttressing quality afforded to the proximal and middle esophagus, by such comparatively unyielding structures as the trachea, aortic arch, descending aorta, left bronchus, pericardium and various autonomic nerve plexuses.

The demonstration of a right-sided perforation is unusual. The tear occurs characteristically in 90-95% of cases in the left lateral position in the lower third of the esophagus.<sup>19)</sup> It is nearly always longitudinal in nature,<sup>4)</sup> measuring two to four cm long, and located three to six cm above the diaphragm,<sup>19)20)</sup> rarely causing massive hemorrhage.<sup>12)19)</sup> The longitudinal nature of the tear is explained by DERBES and MITCHELL by mathematical analysis, using the principle of free body diagrams which show that hydrodynamic factors incidental to the increased internal pressure compelling the esophagus to tear in a vertical plane.

The patients are typically middle-aged, alcoholic persons who present with a history of severe retching and vomiting. Males out-numbered females by 5-11 to 1.<sup>2)19)21)</sup> The dominance of the male may reflect a fact that many habitual alcohol drinkers are included as patients.<sup>2)</sup>

The classic symptomatology consists of sudden, severe low anterior chest pain or epigastric pain. The patients occasionally relate a "snapping" sensation in the chest. The pain is unremittingly excruciating and may radiate into the neck, arms, or back,<sup>19)</sup> and is exacerbated by swallowing,<sup>20)22)</sup> but there has been only two cases unaccompanied by

pain.<sup>23)24)</sup> If the swallowing is accompanied by coughing, it may surely be assumed that the mediastinal pleura has ruptured and that the esophageal tear communicates with the pleural cavity.<sup>19)</sup> Dyspnea, cyanosis and orthopnoea develop rapidly and peripheral vascular collapse may soon appear, patients complain of thirst,<sup>20)22)</sup> and are usually sitting up in bed in a crouched forward position. Physical examination usually reveals a critically ill patient, and subcutaneous emphysema is frequently present over the chest wall and classically in the supraclavicular region as was seen in this patient. In 66% of these patients neck crepitus<sup>25)30)</sup> was demonstrated. The abdomen is often tender with varying degrees of rigidity often simulating an intra-abdominal catastrophe.

Hemoconcentration is commonly demonstrated. Other signs in the chest that are usually present is hydro- or pneumothorax. All patients except one had a significant pneumo-mediastinum,<sup>26)</sup> pneumothorax, subcutaneous emphysema or pleural effusion. Among the diagnostic studies, a radiographic examination of the chest is helpful if it shows free mediastinal air or hydro- or pneumothorax. The earliest roentgenographic finding appeared to be widened mediastinum.<sup>17)</sup> Gastrographin swallow is diagnostic if the contrast material is shown to leak into the mediastinum<sup>29)</sup> as was seen in this case or into the pleural cavity. Endoscopy has also been used successfully as a diagnostic tool in these patients.<sup>27)29)</sup> Correct diagnosis within 12 hours is unusual, and it was given to only 21% of patients.<sup>28)</sup>

The diagnosis is often missed initially to the infrequent occurrence of this syndrome and to the many conditions that in some way mimic it.<sup>29)30)</sup> The most common misdiagnosis is a perforated ulcer,<sup>(2)</sup> and this is followed by myocardial infarction, dissecting aneurysm of the aorta, spontaneous pneumothorax, acute cholecystitis, acute pancreatitis, pulmonary embolism, incarcerated or strangulated diaphragmatic hernia and others. Some of the diagnostic aids already alluded to may be of great value, but a suspicious awareness of the condition is of equal or greater importance in reaching a correct diagnosis. If esophageal rupture or injury is clinically suspected, esophagram is indicated. If a site of rupture is clearly demonstrated in the thoracic esophagus, thoracotomy should be performed. However, if the esophagram is negative, esophagoscopy should be performed to further help in the establishment of the diagnosis.<sup>30)</sup>

There is universal agreement among writers on the subject that surgical repair should be performed as soon as possible. In 1956, DERBES and MITCHELL, in an extensive review of this syndrome, reported that out of 55 cases treated by surgery, 36% died, while out of 71 medically treated cases, 65% died within 24 hours and no one lived longer than 7 days.<sup>4)</sup> The best results are obtained when the diagnosis is made early in the course of

the disease, and surgical repair is performed promptly. However, the perforation may frequently have occurred many hours or many days before the correct diagnosis is given, and in the past the mortality in this group was significantly high.

When subjected to thoracotomy in these critically ill patients, a very perplexing problem was imposed to surgeons. In the late stage of perforation of the esophagus, the distal esophagus is extremely inflamed and oedematous and is surrounded by a suppurative mediastinitis. In these patients, debridement of the necrotic edges of the laceration should be performed as much as possible. These inflamed esophageal tissues do not readily retain sutures placed for repair of the defect, and break down of the suture occurs with a high frequency, resulting in a unfortunate outcome. In delayed (in more than 24 hours) intervention, the best operative therapy is still debated.<sup>22)</sup>

Although the conservative approach provides ample drainage, the source of soilage must be controlled and antibiotics are usually used to control sepsis. In rare instances, when diagnosis is delayed for more than 5 days,<sup>32)</sup> the patient is stable, nonseptic and has no signs or symptoms of empyema, and the perforations are well drained internally, non-operative therapy may be appropriate.<sup>20)33)34)</sup> Previously, such patients were reported. In these cases, several similarities are apparent. The diagnosis was delayed due to misdiagnosis. The patients were stable and nonseptic. The perforation drained completely internally and the pleural space was not contaminated.<sup>32)</sup> Nutritional and antibiotic support was provided. In no instance was the mediastinal pleura ruptured, nor was there respiratory embarrassment.

In 1968, Thal applied his fundic patch valvuloplasty operation to these late post-tetanic perforations, and the duration ranged from 18 to 36 hours, and excellent results were reported in 5 out of 6 cases.<sup>35)</sup> The fundus of the stomach was then readily brought up into the chest and then placed over the esophageal defect and sutured to the edges of the rent. The fundic patch later became lined with squamous epithelium. The right and left posterolateral aspects of the esophagus was invaginated into the remainder of the fundus. At the end of the procedure, the stomach embraced at least two-thirds of the circumference of the esophagus over a length not less than 5cm. Woodward modified this procedure by wrapping the fundus around the complete circumference of the esophagus after the insertion of the fundic patch.<sup>36)</sup> In the past the surgical approach to the esophagus in these cases was through a thoracotomy incision. Since experience with transabdominal vagotomy for peptic ulcer has demonstrated that the distal esophagus can be very easily exposed and mobilized through an upper abdominal incision. BERNE and others presented 5 cases in which the rupture was proved radiographically to exist in the distal esophagus.

All cases were operated on by an upper abdominal midline incision, and a cicumesophageal gastric fundoplication was performed to buttress the repair with a satisfactory outcome in all.

In 1984, YAMASHITA *et al.* reported 173 cases of spontaneous perforation of the esophagus collected from literature in Japan as of 1983. The overall postoperative mortality for patients undergoing all forms of surgery was 27.1 per cent. It was 9.1 per cent for resection of the esophagus, 23.6 per cent for suture of the tear, 29.0 per cent for thoracotomy with drainage and 47.1 per cent for external drainage using a tracar from the thoracic cavity. The patients who underwent suture or resection of the esophagus had significantly excellent results, compared with those having drainage procedure only. In addition, there has been a marked improvement in later years.

We would emphasize that though the Boerhaave syndrome is a very rare condition in female, and surgical intervention with primary suture by early correct diagnosis results in an excellent outcome.

## SUMMARY

Postemetic spontaneous perforation of the esophagus is presented. Clinical suspicion and radiologic confirmation of esophageal perforation resulted in prompt surgical intervention.

Thoracotomy, closure of the rupture and drainage of the pleural cavity resulted in satisfactory outcome. The best prognosticator for the successful outcome in the treatment of this disease is early recognition of the problem. The importance of early diagnosis as a prerequisite to successful treatment is emphasized.

## REFERENCES

- 1) SKINNER, D. B.: Perforation of the esophagus: spontaneous, traumatic, and following esophagoscopy. Davis-Christopher Text book of Surgery, 11th ed. p814, W. B. Saunders Co. Philadelphia.
- 2) KIJIMA, M., ITO, T. and NAGAO, F.: A review of 60 reported case in Japan of spontaneous rupture of the esophagus including a report of authors' case. *Jikeikai Med. J.* 1981, 28 : 21-40
- 3) BOERHAAVE H.: Actrocis, nec descripti prius. morbi historia: secundum medicae artis leges conscripta, Lugduni Batauorum, Boutesteniana, 1724 cited by 4).
- 4) DERBES, V. J., MITCHELL R. E. Jr.: Rupture of the esophagus. *Surgery*, 1956, 39 : 688-709, 865-888.



- 5) HOCHBERG, L. A. and PARLAMIS, N.: Spontaneous and rupture of the esophagus with a report of five cases. *Am. J. Surg.*, 1961, 102 : 428-438.
- 6) COLLIS, J. L., Humphreys, D. R. and Bond, W. H. : Spontaneous rupture of the esophagus. *Lancet* 1944, 2 : 179.
- 7) FOGGITT, K. D. : A case of spontaneous perforation of the esophagus, *Brit. J. Tuberc.* 1946, 40 : 133-134.
- 8) BARRETT, N. R. : Report of a case of spontaneous perforation of the esophagus successfully treated by operation. *Brit. J. Surg.* 1947, 35 : 216-218.
- 9) DORSEY, J. M., HOHF, R. P. and LYNN, T. E. : Relationship of peptic esophagitis to spontaneous rupture of esophagus. *Archs. Surg.* 1959, 78 : 878-888.
- 10) ROSS, J. G. : Spontaneous rupture of the middle third of the esophagus. *Brit. J. Surg.* 1961, 48 : 633-635.
- 11) MC KEOWN, D. R. : Spontaneous rupture of the esophagus with recovery following repair. *Proc. R. Soc. Med.* 1965, 58 : 431-432.
- 12) WYCHULIS, A. R., FONTANA, R. S. and PAYNE, W. S. : Noninstrumental perforation of the esophagus. *Dis. Chest*, 1969, 55 : 190-196.
- 13) BERNE, C. J., SHADER, A. E. and DOTY, D. B. : Treatment of effort rupture of the esophagus by epigastric celiotomy. *Surg. Gynec. Obstet.*, 1969, 129 : 277-280.
- 14) KENNARD, H. W. H. : Rupture of esophagus during child birth. *Brit. Med. J.* 1950, 1 : 417.
- 15) BEAL, J. M. Jr. : Spontaneous rupture of the esophagus. *Ann. Surg.*, 1949, 129 : 512-516.
- 16) FUNATOMI, T., MIMURO, J. and TAKASU, S. *et al.* : A case of Boerhaave's syndrome cured by conservative treatment and review of literature from the endoscopic point of view. *Gastroenterol. Endoscopy*, 1982, 24 :
- 17) BRADHAM RR, BRIDGMAN Ah, SCOTT SM, *et al.* Spontaneous esophageal perforation. Management of the "intermediate" phase. *Am Thorac Surg* 1967, 3 : 6-14.
- 18) MACKLER, S. A. Spontaneous rupture of the esophagus. *Surgery Gynec Obstet* 1952, 95 : 345-356.
- 19) CALLAGHAN. J. : The Boerhaave Syndrome. *Br. J. Surg.*, 1972, 59 : 41-44.
- 20) LARRIEU AJ, KIEFFER R : Boerhaave syndrome. *Ann Surg* 1975, 181 : 452-454.
- 21) PATTEN A. S., LAWSON DW, Shannon JM, Risley TS, Bixby FE. : Reevaluation of the Boerhaave syndrome a review of fourteen cases. *Am J Surg* 1979, 137 : 560-565.
- 22) MOUSAS S. Spontaneous rupture of the esophagus. Is conservative treatment ever justified? *Thorax* 1966, 21 : 11-114.
- 23) ROSOFF L, WHITE EJ. Perforation of the esophagus. *Am. J. Surg* 1974, 128 : 207-218.
- 24) BRADBROOK R. A. : An usual case of spond. Perf. of esophagus. *Brit J Surg* 1973, 60 : 331-333.
- 25) CAMPBELL TC, ANDREWS JL, NEPTUNE WB. Spontaneous rupture of the esophagus (Boerhaave syndrome) necessity of early diagnosis and treatment. *JAMA* 1976, 234 : 526-528.
- 26) NACLERIO, E. A. The "v-sign" in the diagnosis of spontaneous rupture of the esophagus (an early roentgen clue). *Am J Surg* 1957, 93 : 291-298.
- 27) MENGOLI LR, KLASSEN KP. Conservative management of esophageal perforation. *Arch Surg* 1965, 91 : 238-240.

- 28) ABBOTT OA. Atraumatic so-called "spontaneous" rupture of the esophagus. *Ann Surg* 1978, 187 : 634-639.
- 29) SYMBAS PN, HATCHER CR, HARLAFTIS N. Spontaneous rupture of the esophagus. *Ann Surg* 1978, 187 : 634-639.
- 30) CURCIJ JJ, HORMAN MJ. Boerhaave's syndrome : The importance of early diagnosis and treatment. *Ann Surg* 1976, 183 : 401-408.
- 31) CARTER, R., and HINSHAW, D. B. Use of the esophagoscope in the diagnosis of rupture of the esophagus. *Surgery Gynec Obstet* 1965, 120 : 1304-1306.
- 32) IVEY T. D., SIMONOWITZ D. A., DILLAND D. H., MILLER D. W. Jr. Boerhaave syndrome. Successful conservative management in three pts. with late preservation. *Am J Surg* 1981, 141 : 531-539.
- 33) DELUCA RF, TEDESCO FJ, BALLAN K, *et al.* Esophageal perforation. *Am J Gastroenterol* 1977, 67 : 362-365.
- 34) BOBO WO, BILLUPS WA, HARDY JD. Boerhaave's syndrome : A review of six cases of spontaneous rupture of the esophagus secondary to vomiting. *Ann Surg* 1970, 172 : 1034-1038.
- 35) THAL, A. P. : A unified approach to surgical problems of the esophago gastric junction. *Ann. Surg.*, 1968, 168 : 542-550.
- 36) WOODWARD, E. R. Discussion to A. P. THALS' paper. *Ann. Surg.*, 1968, 168 : 549.
- 37) SHAPIRO, R. Conservative management of esophageal perforation. *Archs Surg.*, 1965, 91 : 238-240.
- 38) YAMASHITA, Y *et al.* : A case of spontaneous rupture of the esophagus-review of the literature-. *J. P. S. S.* 45 : 437-442, 1984.