

Evaluation of Cyclosporin A versus Azathioprine in Bronchial Healing of Canine Lung Allografts at Anastomosis

Satoru HASHIMOTO

*First Department of Surgery, Nagasaki University
School of Medicine, Nagasaki, Japan*

Received for publication, May 20, 1987

ABSTRACT

Bronchial healing at anastomosis was compared between autografts and allografts with respect to regeneration of interrupted bronchial artery and tensile strength at the site of bronchial anastomosis following canine lung transplantation, and also compared with the effects between azathioprine and cyclosporin A.

The results were as follows

- (1) In autografts, the bronchial healing at anastomosis was achieved after the 14th day, the regeneration of the bronchial artery was completed at 14 days, keeping satisfactory tensile strength to avoid bronchial disruption.
- (2) In allografts treated with azathioprine, the bronchial healing at anastomosis was delayed at 21 days or more.
- (3) In allografts treated with cyclosporin A, both regeneration of bronchial artery and acquisition of strong tensile strength were confirmed as good as these in autografts at 14 days or more.

It was concluded that bronchial healing in lung allografts was not so impaired by cyclosporin A as observed by azathioprine.

INTRODUCTION

Many problems concerning lung transplantation still remain unsolved in spite of wide clinical use of other organ transplantations such as the kidney, liver and heart. It is well known that the use of immunosuppressive drugs is indispensable for a long graft survival. The reason is that lung allograft, in particular, is more liable to be rejected.

Furthermore, it is a matter of great concern as to whether bronchial healing at anastomosis of lung allografts is favorable or not. It also closely relates to the outcome of lung allotransplantation. Needless to say, it is necessary to suppress the immunoresponse properly and prevent catastrophe of bronchial anastomosis insufficiency as much as possible to obtain a satisfactory result following lung transplantation.

Since cyclosporin A was used as a new immunosuppressive drug in 1974, potent immunosuppressive effect has been recognized and the outcome in clinical cases has become much more improved even in a few so far.

This study was undertaken to clarify the bronchial healing process in terms of tensile strength and regeneration of bronchial artery with elapsing time following canine lung transplantation and to judge the difference in bronchial healing between azathioprine and cyclosporin A.

MATERIAL AND METHOD

Fifty-eight mongrel dogs, weighing 8 to 18kg were anesthetized with pentobarbital of 25mg/kg used intravenously, intubated and ventilated with respirator. Auto- and allotransplantation of the left lung was performed under left thoracotomy, avoiding the injury of the phrenic and vagal nerves and anastomosing in the following order, the left atrial cuff using Prolene 5-0 of running mattress suture, the left main pulmonary artery with Prolene 5-0 of running over and over suture and the left main bronchus with Nylon 4-0 of running over and over suture respectively. After suturing the chest wall, a tube drainage was used for several hours.

The dogs subjected to this study were divided into three groups, that is, Group A included 16 dogs of autotransplantation, Group B 19 dogs of allotransplantation treated with azathioprine and Group C 19 dogs of allotransplantation with cyclosporin A.

Azathioprine was given at a dosis of 4~5mg/kg/day per os and cyclosporin A also was administered at 20mg/kg/day per os. PIPC of 50mg/kg/day were continuously given to prevent postoperative infection. Group A was autopsied at 7, 14 and 28 days after transplantation, in contrast, Group B and C were done at 7, 14 and 21 days. At that time, the bronchial angiography was made and tensile strength to break down at bronchial anastomosis was also measured. Bronchial healing was histologically assessed.

Procedure of Bronchial angiography: Heparine ($5 \times 10^3 \mu$) was given intravenously and the thoracic aorta was ligated at two points directly beneath the origin of the left subclavian artery and just above the diaphragma. After cannulation 1000 to 1500ml of saline solution was infused and then drained out from the opening of the right atrial wall. Following saline infusion 100ml of 30% BaSO₄ was infused, followed by 100ml of 30% BaSO₄ adding gelatin, and cooled at 4°C for 30 minute. Then, heart and lungs including bronchial

anastomosis were removed to take a Softex picture using Fuji Softex Film on condition of 40KVP, 3mA and 10 second.

The bronchial artery connection across the anastomosis was graded by using microangiogram with widely extended specimens along the longitudinal axis and slice one.

The grades of vascular connection drawn from extended specimens were as follows. Grade-0 (G-0): neovascularity was never seen across the anastomotic line. Grade-I (G-I): slight neovascularity was observed across the anastomosis. Grade-II (G-II): regeneration of bronchial artery was seen but development was insufficient as compared with healthy lung. Grade-III (G-III): the bronchial artery markedly developed across the anastomosis showing dense staining of peripheral bronchial artery with contrast medium as shown in Fig. 1.

And also regenerated neovascularity on the microangiogram obtained from sliced specimens were classified into the following four types according to KAWAHARA' classification.¹⁾ grade-0 (g-0): neovascularity extending anastomosis was never visible. grade-1 (g-1): regeneration of bronchial artery limited to the adventitial plane across the anastomosis. grade-2 (g-2): neovessels existed in the adventia and/or the submucosa alone or in combination. grade-3 (g-3): regeneration of the bronchial artery was observed in the whole layer covering the anastomosis as shown in Fig. 2.

Procedure of the tensile strength at bronchial anastomosis: longitudinal incision was added along the membranous portion at bronchial anastomosis. A 1cm slice with right angle to bronchial anastomosis was prepared. The tensile strength of anastomosis was measured with the use of AUTOGRAPH (SHIMAZU Co.), retracting at a speed of 0.5mm/min after extracting the suture material. The specimens with stenosis at bronchial anastomosis were excluded in this study.

Macroscopic and histologic assessment at bronchial anastomosis: The findings of edema, bleeding and ulceration at anastomosis were carefully checked on gross appearance. Wrapping with the regenerated epithelium at bronchial anastomosis was histologically assessed.

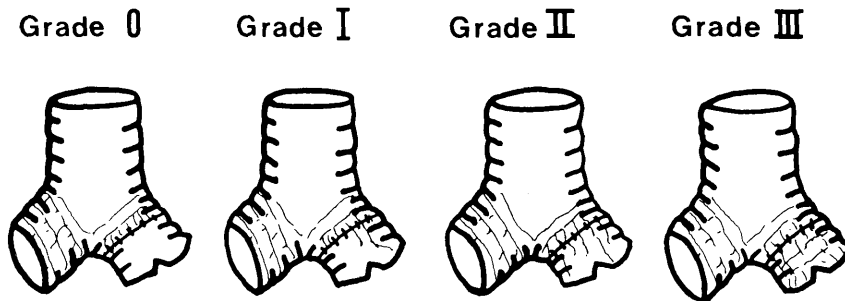


Fig. 1. The newly development bronchial arteries at anastomotic site is shown with grading classified by microangiographic finding.

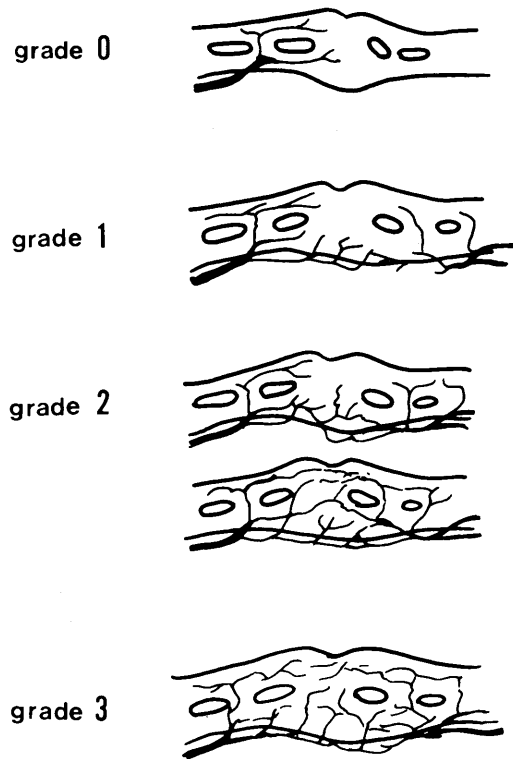


Fig. 2. The newly development arteries arising from the adventitia on the slices are shown with grading classified by microangiographic finding.

RESULTS

The tensile strength was lowered as being 112 ± 75 g at 7 days after transplantation in autografts, although it rapidly increased to 547 ± 238 g at 14 days. At 28 days, it reached 791 ± 93 g showing a slight increase.

Meanwhile, in allografts treated with azathioprine it was a minimum of 86 ± 27 g at 7 days, not demonstration any statistically significant difference from autografts. In contrast, at 14 days it was increased to 294 ± 64 g, demonstrating a statistical significance as compared with that in autografts. At 21 days it showed 663 ± 103 g, almost equivalent to that of autograft. In the allografts treated with azathioprine the breaking point of anastomosis raised much more, from 14th to 21th day rather than from 7th to 14th day.

The tensile strength at 7 days in the allografts treated with cyclosporin A was similar to those in autografts and allografts treated with azathioprine with no statistically significant difference. At 14 days, it showed 559 ± 196 g with rapid rise and was almost equal to that of autografts with a significant difference ($p < 0.01$) as compared with the allografts treated with azathioprine as shown in Fig. 3.

Wound healing at bronchial anastomosis in view of tensile strength test was similar between autografts and allografts treated with cyclosporin A. However, that in the allografts treated with azathioprine was inferior to those in another groups.

The regeneration of the bronchial artery in autografts at 7 days was demonstrated as being G-0 to G-II, including 2 in G-0 out of 6. In contrast, at 14 days it was presented as being G-III except one of G-II, and at 28 days it was completed, showing G-III in all of 2.

In the allografts treated with azathioprine, the development of the bronchial artery at 7 days showed the grades fo G-0 to G-II, including 3 of G-0 out of 7. At 14 days it came to show G-II in over one half of 7 and G-III in a few, although at 28 days all had shown G-III.

In the allografts treated with cyclosporin A, the regeneration of the bronchial artery showed a similar pattern to those in another group at 7 days but G-0 was shown in only one. At 14 days G-III was presented in all but one of G-II as shown in Fig. 4. Photo 1 shows the well developed bronchial artery in allograft treated with cyclosporin A at 14 days.

As for the regeneration of the bronchial artery on the sliced specimen it was compared between auto- and allo- lung grafts. In autografts, the recanalization of the bronchial artery was shown as being the grade of g-0 to g-2 though only one was g-2, gradually progressed to g-2 to g-3 at 14 days, presenting g-3 in 6 out of 8 (75%), and completed at 28 days as shown in all of g-3.

In the allograft treated with azathioprine regeneration was shown as being g-0 to

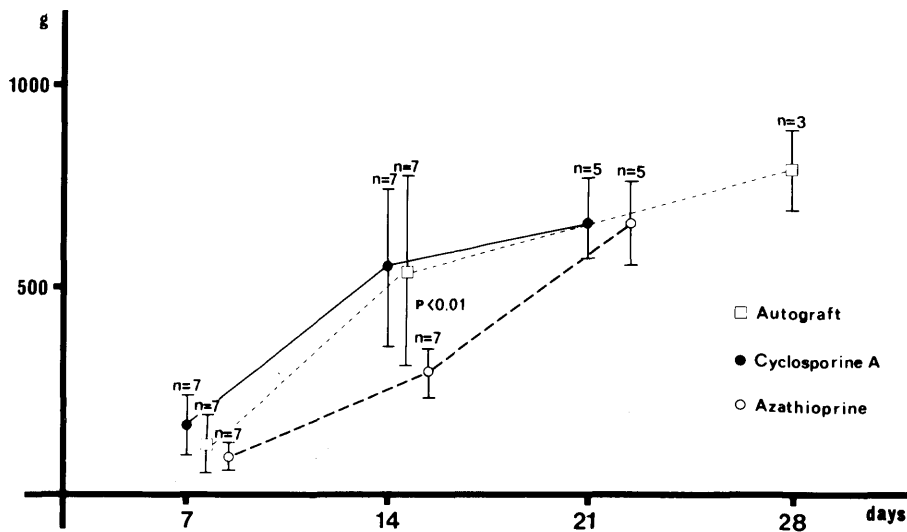


Fig. 3. The tensile strength of bronchial anastomosis.

g-1 at 7 days, though none was in g-2 in spite of g-0 in 5 out of 7, at 14 days all but one of g-3 showed g-2 and at 21 days g-3 was revealed in all. In the allografts treated with cyclosporin A, at 7 days regeneration was shown as being g-0 to g-1, though none was in g-2 in spite of g-1 in one half, gradually progressed to g-2 to g-3 at 14 days, presenting g-3 in 6 out of 8, and at 21 days all of three revealed g-3 as shown in Fig. 5.

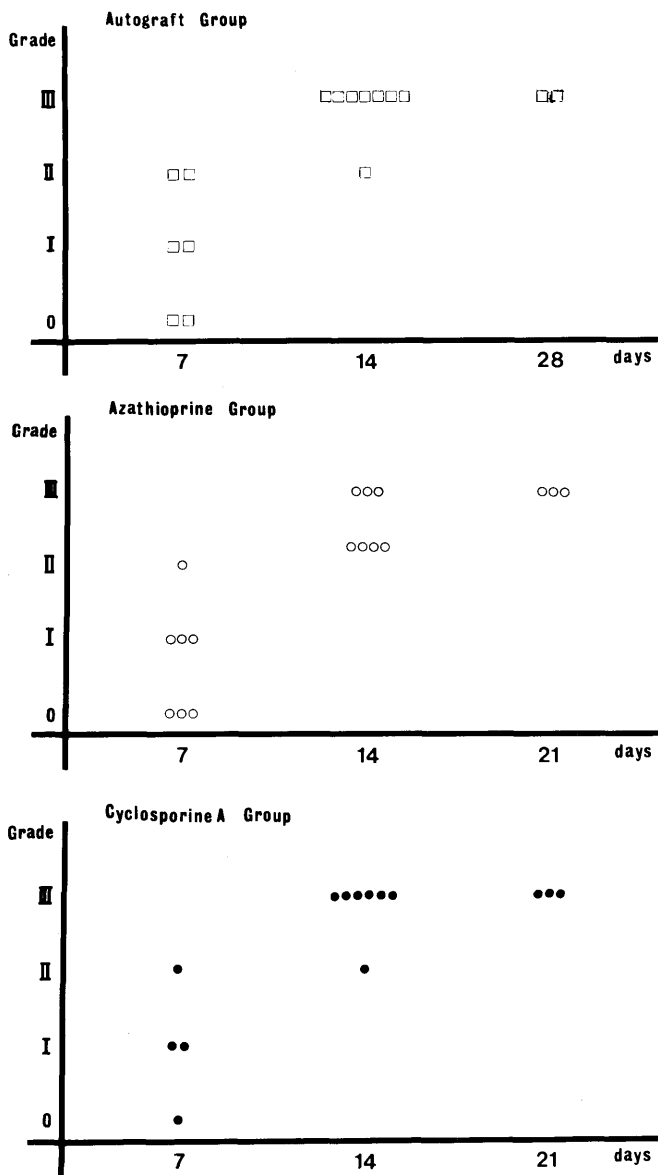


Fig. 4. The degree of the newly developmental bronchial arteries at the anastomotic site.

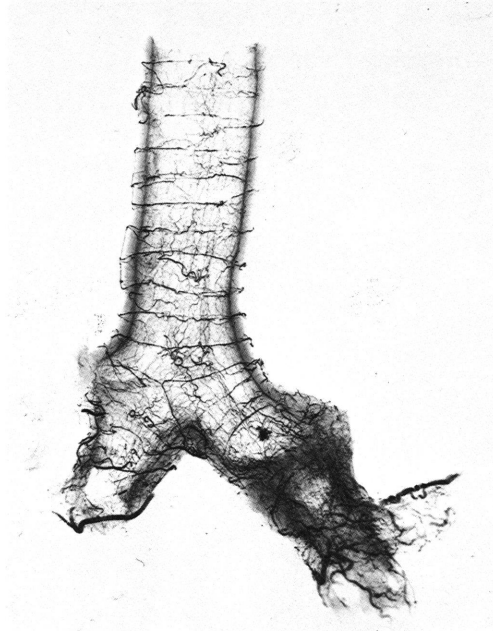


Photo 1. Bronchial angiogram finding of anastomosed bronchus, showing the dense filling of bronchial arteries extended beyond the anastomosis on 14 days in allograft treated with Cyclosporin A.

Photo 2 shows well developed communication between the proximal and distal bronchial arteries in allograft treated with cyclosporin A at 14 days. From the above results, it is defined that regeneration of the bronchial artery initiated at the adventitial plane and was progressed at 14 days in autografts and allografts treated with cyclosporin A, although it was delayed in the allograft treated with azathioprine. Consequently at 21 days, it was completed without only differences among the three groups.

A comparison between tensile strength and regeneration of the bronchial artery at anastomosis was made as shown in Fig. 6. Both these findings had become evident with elapse of time following transplantation showing a nadire at 7 days.

As for macroscopic findings of edema and bleeding at anastomosis, at 14 days those in the allografts treated with azathioprine were much more aggravated than those in either autografts or allografts treated with cyclosporin A, although at 28 days those were improved without a significant difference as shown in Photo 3.

On the basis of histologic findings, it is assumed that histologic healing of anastomosis was initiated at 7 days to 14 days. However, histologic epithelial regeneration was incomplete in allografts treated with azathioprine, whereas it was far advanced, forming stratified epithelium in allografts treated with cyclosporin A.

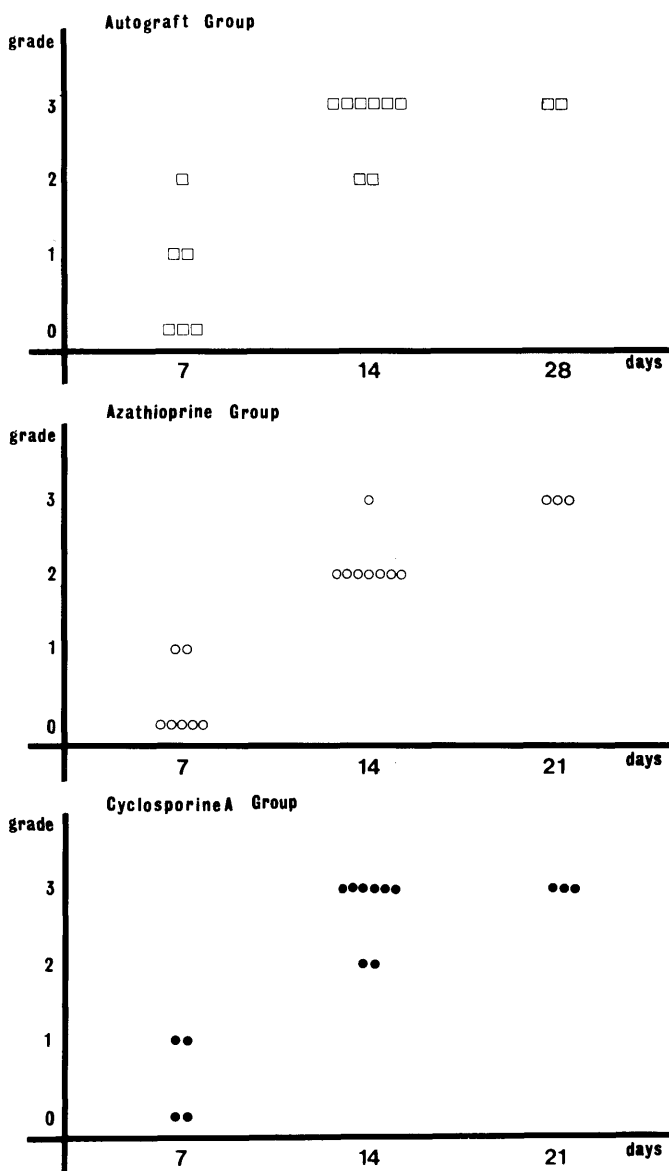


Fig. 5. The degree of the newly growing arteries of the slices at the bronchial anastomosis.



Photo 2. Bronchial angiogram on the slice at the anastomosis, showing well developed bronchial communication between distal and proximal bronchial arteries on 14 days in allograft treated with Cyclosporin A.

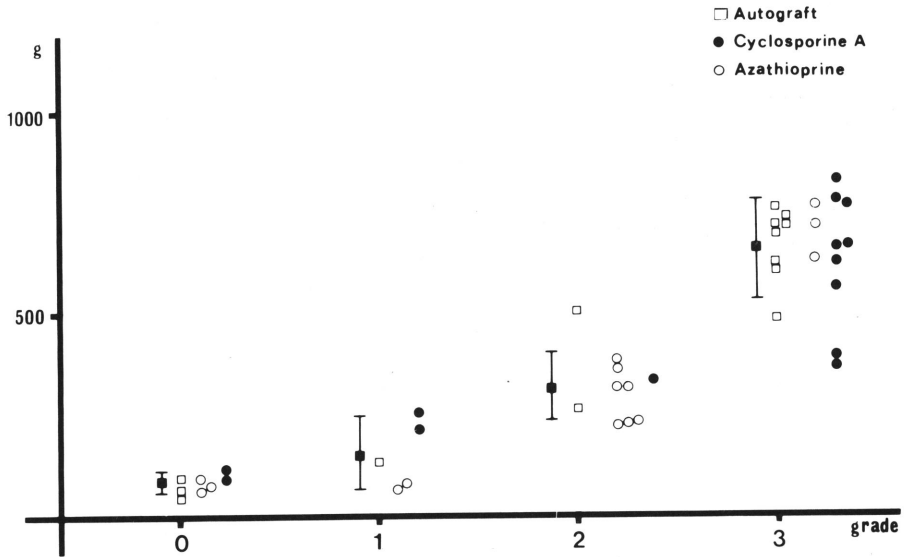
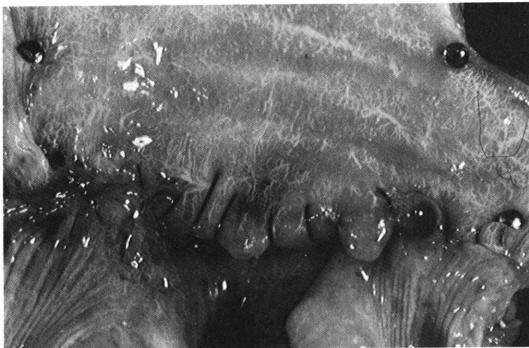

Fig. 6. A relationship between tensile strength and regeneration of the bronchial arteries at anastomosis.

A :



B :

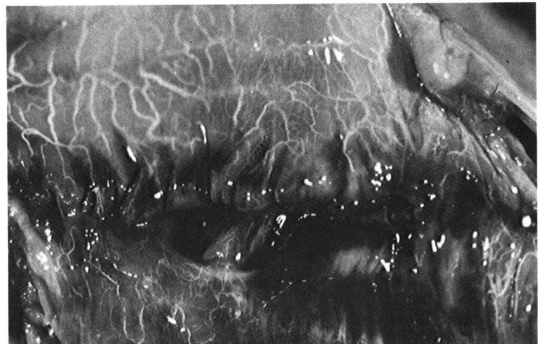


Photo 3. Macroscopic finding of healing in bronchial anastomosis.
A: On 14 days in allograft treated with Cyclosporin A.
B: On 14 days in allograft treated with Azathioprine.

DISCUSSION

Some reports concentrate on the complications of bronchial anastomosis following lung transplantation such as anastomotic insufficiency and/or the ensuing stenosis. It is considered to be associated with immunoresponse, impaired blood supply to bronchial anastomosis, rejection reaction and poor surgical technique.²⁾ It is needless to say that an immunosuppressive drug is required for suppression of the immunoresponse. If the drug, however, exerts an inhibitory effect on adaptation of the wound, its use should be restricted. Since cyclosporin A was developed as a potent immunosuppressive drug, long clinical survivors have been able to obtain. SAUNDERS³⁾ reported that cyclosporin A enabled experimental lung allograft to survive much longer than azathioprine with steroid and benefited by reducing postoperative complications.

The measurement of tensile strength to break down has been used for assessment of bronchial anastomosis healing. LIMA⁴⁾ clarified that azathioprine with steroid used for suppression of immunoresponse played the key role in reducing the tensile strength and retarding the wound healing process.

A comparison on bronchial healing between administering azathioprine and cyclosporin A was made on lung autografts by GOLDBERG *et al.*⁵⁾ It is of interest to emphasize that cyclosporin A administration forced to promote much better improvement of bronchial healing rather than azathioprine with steroid. In contrast, ARUNUGAM⁶⁾ reported that azathioprine did not so significantly hinder the wound healing of the skin stitches as reported by others.

In the present study bronchial healing at anastomosis in the allograft treated with cyclosporin A was not completely achieved at 7 days but gradually increased at 14 to 21 days with a similar step to that of autografts. On the contrary, in the allografts treated with azathioprine the bronchial healing was markedly delayed up to the 14th day, followed by a rapid and excellent healing at the 21th day, demonstrating a complete healing.

There are some reports that wound healing is facilitated and completed by the fibroblast-activating factor released from active macrophages which result in fibroblast proliferation, fibrocollagen deposition and neovascularity. There are some reports regarding that the activity of active macrophage is depressed by prednisolone and azathioprine.^{7,8)} It is believed that azathioprine itself can inhibit the activity of active macrophage and directly suppress the function of the monocyte production by bone marrow.⁹⁾ And also, it is evidenced that azathioprine suspends circling cell cycle of promonocyte. For example, azathioprine of 3mg/kg/day reduces monocyte production to 70% and sets back the cell cycle time of promonocyte to 5.5 hours.¹⁰⁾

Furthermore, prednisolone exerts the reducing effects of monocyte population sufficient to allow for depressed phagocytic activity of monocyte as well as the monocyte

migration to the inflammatory lesion by 33%.¹¹⁾ It is reasonable to consider that these actions of prednisolone and azathioprine against active macrophage enable wound healing¹⁰⁾ to delay.

On the other hand, the cyclosporin A is effective in inhibiting lymphokine production which promotes T-cell production, although remaining to be accounted for.¹²⁾¹³⁾ Generally speaking, it is known that cyclosporin A has nothing to inhibit the function of bone marrow¹⁴⁾ or the activity of macrophage migration.¹⁵⁾

These pharmacologically different actions between azathioprine and cyclosporin A may play an important role in bronchial healing at anastomosis.

It is natural that bronchial blood supply at anastomosis may as well be reduced by division of the bronchial artery which may predispose to ischemia and be compensated by pulmonary bronchial circulation supplemented by peripheral pulmonary arterial flow.¹⁶⁾ The blood of intrapulmonary collateral circulation contains a low oxygen concentration on account of originating from the pulmonary artery.

To improve and promote the bronchial wound healing at anastomosis, one should take it into consideration that regeneration and recanalization of the bronchial artery must be hastened as soon as possible. As a rule, the bronchial artery to the lung originates from the posterior portion of the lung hilum and develops along the adventitial plane and penetrate to the submucosal plane, passing around the cartilage and reaching the bronchial gland, in part forming a vascular network in the submucosal plane.¹⁷⁾

In case of bronchial anastomosis performed surgically, it is acknowledged that regeneration of the bronchial artery initiates from the adventitial layer at anastomosis and communicates with the submucosal vessel of the proximal bronchus. Consequently it is completed throughout the bronchial wall.¹⁾

Regeneration of the bronchial artery following lung transplantation is reported by SIEGELMAN *et al.*¹⁸⁾ According to them it begins to develop at 12 days and is completed in 2 to 3 weeks in combined administrations of azathioprine with prednisolone. PEARSON¹⁹⁾ also reported that 3 or 4 weeks are needed for recovery from interrupted bronchial artery. In the present study, recanalization of the bronchial artery as observed 14 days earlier than would be expected.

PINSKER²⁰⁾ clarified that surgical anastomosis between intercostal artery and peripheral bronchial artery was of great value to improve the bronchial wound healing as well as to reduce the incidence of postoperative complications.

VEITH²¹⁾ also devised a new method of improving the bronchial flow of the transplanted lung. He moved the left lung to the right thoracic cage and made anastomosis between bronchial arteries. Some investigators^{22)~25)} reported that the omental wrapping of the bronchial anastomosis was of use to promote early recanalization for interrupted bronchial artery within 3 to 4 days following lung transplantation.

As far as the immunosuppressive drugs is concerned, cyclosporin A does not thwart

bronchial healing including recanalization of the bronchial artery and new growth of the regenerated epithelium

ACKNOWLEDGEMENT

The author wish to thank greatly Masao Tomita, Professor of Surgery, for his kind guidance and review of the paper and also thank all of the staff of the department for their cooperation.

REFERENCES

- 1) KAWAHARA K.: An Experimental Study on Bronchial Recirculation following Bronchial Reconstruction—Especially the Correlation of Pulmonary Artery Stenosis with Bronchial Artery regeneration. *Nagasaki Igakkai Zasshi* **55**: 199–229, 1980.
- 2) VEITH F. J. *et al.*: Transplantation overview, Lung transplantation 1983. *Transplantation* **35** : 271–278, 1983.
- 3) SAUNDERS N. R.: Cyclosporin and bronchial healing in Canine lung transplantation *J. Thorac. Cardiovasc. Surg.* **88(6)**: 993–999, 1984.
- 4) LIMA O.: Effects of methylpredonisolone and azathioprine on bronchial healing following lung autotransplantation. *J. Thorac. Cardiovasc. Surg.* **82(2)**: 211–215, 1981.
- 5) GOLEBERG M.: A comparison between cyclosporin A and methylpredonisolone plus azathioprine on bronchial healing following canine lung autotransplantation. *J. Thorac. Cardiovasc. Surg.* **85(6)**: 821–826, 1983.
- 6) ARUMUGAN M.: The effect of immunosuppression on wound healing. *Surg. Gynecol. Obstetrics* **133**: 72–74, 1971.
- 7) CLARK R. A.: Role of Macrophages in wound healing. *Surg. Forum.* **27**: 16–18, 1976.
- 8) SHORON M. *et al.*: Regulation of Macrophage Collagenase, Prostaglandin, and Fibroblast-Activating-Factor Production by Anti-inflammatory Agents. Different Regulatory Mechanism of Thissue Injury and Repair. *Cellular Immunology* **92**: 302–312, 1985.
- 9) ELLION GB.: Immunosuppressive agents. *Transplanta. Proc.* **9**: 975–979, 1977.
- 10) VAN FOURTH R.: The effect of azathioprine (Imuran) on the cell cycle of promonocytes and the production of monocytes in the bone marrow. *J. Exp. Med.* **141**: 531–546, 1975.
- 11) LEIBOVICH, SJ.: The role of the macrophage in wound repair. A study with hydrocortisone and antimacrophage serum. *Am. J. Pathol.* **78**: 71–100, 1985.
- 12) BUNJES D.: Cyclosporin A mediate immunosuppression of primary cytotoxic T cell responses by impairing the release of interleukin 1 and interleukin 2. *Eur. J. Immunol.* **11**: 657, 1981.

- 13) ANDRUS L.: Inhibition of T-cell Activity by Cyclosporin A. *Scand. J. Immuno.* 15: 449, 1982.
- 14) HELLMANON A.: Effect of Cyclosporin A on human granulopoiesis in vitro. *Transplantation* 30: 404. 1980.
- 15) BLOCK L.: Inhibition of mitogen-induced lymphokine production by Cyclosporin A. *Kill. Wschr.* 58: 357, 1981.
- 16) PINSKER K. L.: Effect of the donor bronchial length on healing. *J. Thorac. Cardiovasc. Surg.* 77(5): 669–673, 1979.
- 17) NAGAISHI C.: Functional Anatomy and Histology of the Lung. *Igaku Shoin L. T. D.* Tokyo 1972. (p. 79)
- 18) STANLEY S. SIEGELMAN: Restoration of bronchial artery circulation after canine lung allotransplantation. *J. Thorac. Cardiovasc. Surg.* 73(5): 792–795, 177.
- 19) PEARSON F. G.: Bronchial Artery Circulation Restored after of Canine Lung. *Can. J. Surg.* 13: 243–250, 1970.
- 20) PINSKER K. L.: Influence of bronchial circulation and corticosteroid therapy on bronchial anastomotic healing. *J. Thorac. Cardiovasc. Surg.* 87: 439–444, 1984.
- 21) VEITH F. J.: Transplantation of the left lung into the right hemithorax of facilitate immediate reconstruction of bronchial artery flow. *J. Thorac. Cardiovasc. Surg.* 75(1): 141–146, 1978.
- 22) KIMINO K.: Experimental Study on Healing Process in Bronchial Anastomosis - Especially Availability of Omental Wrapping and Pericardial Covering-. *The Acta Medica Nagasakiensia* Vol. 30. No. 1–3, October, 1985.
- 23) MORGAN E.: Improved bronchial healing in canine left lung reimplantation using omental pedicle wrap. *J. Thorac. Cardiovasc. Surg.* 85(1): 134–139, 1983.
- 24) DUBOIS P.: Bronchial Omentopexy in Canine Lung Allotransplantation. *The Ann. Thorac. Surg.* 38(3): 211–213, 1984.
- 25) MORGAN E.: Successful revascularization of totally ischemic bronchial autografts with omental pedicle flap in dogs. *J. Thorac. Cardiovasc. Surg.* 84(2): 204–210, 1982.