

## The New Treatment of Hepatocellular Carcinoma — Hepatic Arterial Infusion of <sup>131</sup>I-Lipiodol —

Shigenobu Nagataki, Kouichi Johya

*The First Department of Internal Medicine,  
Nagasaki University School of Medicine*

**ABSTRACT :** We performed intrahepatic arterial infusion of <sup>131</sup>I-labelled Lipiodol (<sup>131</sup>I-Lipiodol) as an internal radiation therapy in twenty patients with (HCC). Tumor sizes were reduced in all attempted patients, and serum AFP levels were also decreased in the patients with high levels of serum AFP. Furthermore, the resected specimens of the tumors revealed complete or nearly complete necrosis in 2 patients who were underwent the surgical resection after the treatment. No significant side effects were observed in all attempted patients.

These results suggest that intrahepatic arterial infusion of <sup>131</sup>I-Lipiodol is a safe and effective therapeutic method for HCC.

### INTRODUCTION

HCC is the most common form of primary liver carcinoma, and is one of the highly malignant cancers in Japan. Current therapies for HCC includes surgical resection, transcatheter arterial embolization (TAE) and intrahepatic arterial infusion of anticancer agents. However, the prognosis is not satisfactory.

Grady ED and others reported the intrahepatic arterial infusion of yttrium-90 (<sup>90</sup>Y) microspheres in the treatment for HCC in 1979 (1). The anticancer effects such as the decrease in tumor size, the relief of symptom and the prolongation of the survival time were recognized after the treatment. However, since the radioactive particles accumulated in non-tumor region as well as the tumor region of liver, inevitable side effect also occurred (1).

In 1979, lipid contrast medium, Lipiodol was found to remain selectively in the tissue of HCC when injected into the hepatic artery (2, 3).

Lipiodol is an ethylester of the fatty acid of poppy seed with 38% iodine by weight, and the iodine residue was found to be replaced by

<sup>131</sup>I with almost 100% efficiency. We reported previously that the resected specimens of the tumor revealed histologically complete necrosis, when <sup>131</sup>I-Lipiodol was injected into hepatic arteries of rats with chemically induced hepatoma (4).

Based on these findings, we attempted this method as a new therapeutic approach in treatment for HCC.

### MATERIALS AND METHODS

#### *Patients :*

Thirteen patients with HCC, 11 men and 2 women, aged from 44 to 76 years (mean age 61) were subjected in the present study (Table 1). Five of all patients had solitary tumor and the other had multiple or diffuse tumor. Liver cirrhosis was coexisted in 11 patients. Tumor thrombi in major portal branches were also recognized in 3 patients. Serum levels of AFP had been elevated in 12 patients. Four patients were seropositive for HBs-Ag. In 2 of 3 patients with resectable HCCs, operation was underwent after the treatment.

All patients and their families consented to the treatment protocol.

Table 1.

SUBJECTS					
Case	Age, Sex	Location	Type of HCC	Liver cirrhosis	AFP ng/ml
1	64, M		S	+	6
2	55, M		S	+	98
3	71, F		S	+	723
4	76, F		S	-	8098
5	70, M		M	+	667
6	61, M		S	+	141
7	56, M		M	+	140
8	55, M		M	+	16114
9	58, M		M	+	222
10	61, M		M	+	139
11	44, M		M, D	-	111684
12	60, M		D	+	539482
13	59, M		M	+	180

S=Solitary M=Multiple D=Diffuse

#### Preparation and injected doses of $^{131}\text{I}$ -Lipiodol

Lipiodol is a product of Andre-Gelbe Laboratories, France.  $^{131}\text{I}$ -Lipiodol was produced by replacing iodine residue of Lipiodol to  $^{131}\text{IClO}_4^-$  under aseptic condition with almost 100% efficiency. The radioactivity of  $^{131}\text{I}$ -Lipiodol was 20mCi per ml in content.

We determined an adequate therapeutic dose of  $^{131}\text{I}$ -Lipiodol to deliver less than 30Gy to normal liver tissue and more than 70Gy to tumor tissue.

#### Evaluation of the effect of $^{131}\text{I}$ -Lipiodol :

After injection, computed tomography, ultrasonography, and hepatic angiography were performed regularly and the sizes of the tumors were compared before and after the treatment. Serial changes in serum level of AFP were also determined. Histological studies of the resected specimen were performed in two operated cases after the treatment. Hematologic tests, liver function tests, renal function tests, respiratory function test, and thyroid function tests were all carried out in order to monitor the adverse effects.

## RESULTS

#### Accumulation of $^{131}\text{I}$ -Lipiodol in tumor :

Selective accumulation of  $^{131}\text{I}$ -Lipiodol was

clearly demonstrated as the high density area on CT scan and hot area on the scintigram of the liver.

#### Anticancer effect :

##### 1) The changes in tumor size,

The result of changes in tumor size was shown in Figure 1. The size of the tumor represented in area ( $\text{cm}^2$ ) was measured from CT scan. The decreases in tumor size were recognized in all cases. Especially in two cases, the tumors were decreased to less than 5% of the original size, and the tumor stain on hepatic angiography had disappeared nearly completely 6 months after the treatment.

## Changes in Tumor Sizes

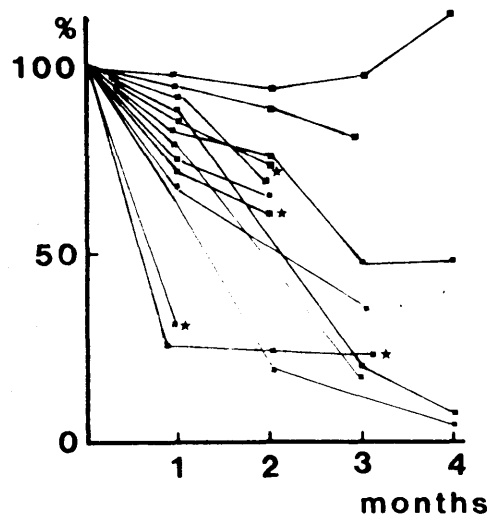


Fig. 1. Changes in Tumor Sizes

##### 2) The serial changes in serum level of AFP

The serial changes in the serum level of AFP were shown in Figure 2. The decreases of serum level of AFP were recognized in all 5 solitary cases, from 11 to 63% two months after the treatment. In 8 multiple or diffuse cases, the decreases in serum level of AFP were also recognized, from 20 to 92% one month later, but there were 3 cases showed the reevaluation 2 months after the treatment. In two cases, the reevaluation of serum AFP was due to the progression of the tumors in untreated lobes

because we could not treat both lobes simultaneously. In one case it was due to the extrahepatic metastasis found 2 months after the treatment.

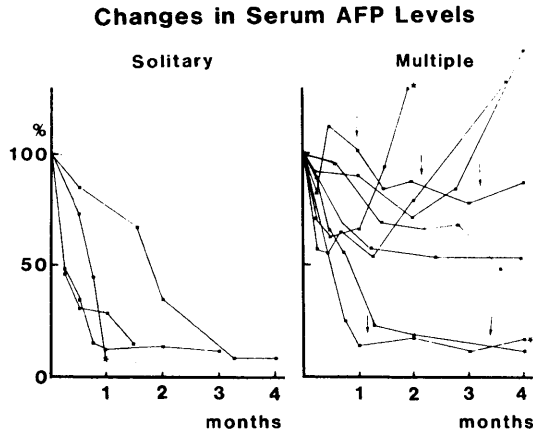


Fig. 2. Changes in Serum AFP Levels

### 3) Histological examination,

The histological examination of the resected specimens revealed complete necrosis in one case and remarkable necrotic change in one case.

### Side effect :

After 32 times of hepatic arterial infusion of  $^{131}\text{I}$ -Lipiodol, no adverse effects of embolization in critical organ such as lung, heart or brain have been noted, and concerning radiation injury, no adverse effects such as neurological, gastrointestinal, renal or pulmonary damage were noted.

As regard as the liver, mild and transient elevation of glutamic-pyruvic transaminase and mild decline of cholinesterase were only seen in 4 and 5 respectively. Only mild and transient leukopenia was seen in 2 of 13 patients. The thyroid function, renal function and respiratory function showed no significant changes after the treatment.

## DISCUSSION

TAE occupies main position in medical treatment for HCC. TAE, however, has been found to have several disadvantages such as rapid development of collateral vessels and toxicity

in the non tumor tissues, and it has little effect on daughter nodules. Furthermore, it is out of indication in cases with tumor emboli in major portal branches.

In 1979, Lipiodol was found to remain selectively in HCC when injected into the hepatic artery (2, 3). The principles of the selective delivery and the retention of Lipiodol have been explained by the developed neovasculature, the enhanced permeability, and poor reticulo-endothelial systems in HCC (3).

The liver can tolerate a massive amount of internal radiation as to 50-500 GY (1). According to these facts Grady ED and others attempted the intrahepatic arterial infusion of  $^{90}\text{Y}$  radioactive microspheres in the treatment of HCC, but the adverse effects were also recognized (1).

We previously reported the effect of  $^{131}\text{I}$ -Lipiodol on chemically induced rat hepatoma (4).  $^{131}\text{I}$ -Lipiodol, when injected into the hepatic feeding arteries, it remained in the small arteries for 48 hours, then extravasated. Based on these results, we applied  $^{131}\text{I}$ -labeled Lipiodol in the treatment of patients with HCC.

Tumor sizes decreased in all attempted patients two months after the treatment. The decrease in serum levels of AFP on the 1st month after the treatment were recognized in all patients with high levels of serum AFP. The decreases in serum levels of AFP was more remarkable in solitary cases than in multiple or diffuse cases. In comparison with TAE, there were large differences in serial changes in serum levels of AFP between  $^{131}\text{I}$ -Lipiodol treatment and TAE. After TAE serum levels of AFP decreased rapidly by mechanical ischemic changes, but the reelevations were also seen in early period. These results may suggest the disadvantages of TAE such as the rapidly developing collateral vessels or the toxicity in normal liver tissues around the tumors. On the other hand, the decrease in serum levels of AFP after  $^{131}\text{I}$ -Lipiodol infusion were more slowly and maintained for a longer time than that after TAE, furthermore obstruction of the feeding arteries or developed collateral vessels have never seen in this treatment. Therefore we could perform the

additional treatments in the cases that recurrence had been indicated.

No significant side effects, such as liver damage, renal disorder, bone marrow suppression, thyroid dysfunction, respiratory dysfunction, were recognized in this treatment.

### REFERENCE

- 1) Grady ED, M. D. ; Internal Radiation Therapy of Hepatic Cancer. American Society of Colon and Rectal Surgeons 22 : 371, 1979.
- 2) Nakamura K, Tashiro S, Uemura K, Konno T, Tanaka M, Yokoyama I ; An attempt for increasing effects of hepatic artery ligation for advanced hepatoma (in Japanese). Jap-Deutsche Med Berichte 24 : 675-682, 1979.
- 3) Iwai K, Maeda H, Konno T ; Use of oily contrast medium for selecting drug targeting to tumors ; Enhanced therapeutic effect and x-ray imaze. Cancer Res. 44 : 2115-2121, 1984.
- 4) Tsai T, Kusumoto Y, Nagataki S. et al. ; Effect of intrahepatic arterial infusion of <sup>131</sup>I-labelled lipiodol on hepatocellular carcinoma of rat. Annals Academy of Medicine. 15 : 521-524, 1986.