

Abdominotransanal Rectal Resection for Distal Carcinoma of the Rectum

Hiroshi Ishikawa, Keiji Kajiwara, Yuzuru Nakamura, Fusao Kubota, Hiroyuki Minami, Takahiro Nishida, Eiichirou Yamaguchi, Hiroyuki Nakatani, Masumi Ifuku

Department of Surgery, Sasebo City General Hospital

Introduction

In the surgery for carcinoma of the rectum, radical resection should be performed while preserving the bowel function. Because the EEA stapler technique has been disseminated, anterior resection is indicated in most cases of carcinoma of the upper rectum, without causing any problem in the bowel function. In cases of carcinoma of the lower rectum, however, anterior resection is often difficult, and selection of a technique appropriate for each case is necessary. The authors recently performed abdominotransanal rectal resection (transanal anastomosis) in four cases of carcinoma of the lower rectum in which anterior resection had been considered difficult, and obtained satisfactory results in terms of the postoperative bowel function and manometric studies.

Subjects and Techniques

Subjects were four patients (two men and two women) with carcinoma of the lower rectum treated with abdominotransanal rectal resection at the Department of Surgery of Sasebo City General Hospital between April 1991 and today. They were 60-69 years old (63.8 years on average).

Operative Technique

Under general anesthesia, a perineal approach begins in prone jack knife position. Saline containing adrenaline (1:300000) is injected into the submucosa above the dentate line. Dissection is performed between the puborectalis muscle and the internal sphincter. The external sphincter, puborectalis muscle and levator ani muscles are not disturbed, and 1-2 cm of internal sphincter ani are preserved. The proximal rectal stump is then closed by simple over and over suture. The patient is positioned as for asynchronous combined abdominoperineal excision with the legs elevated on Lloyd-Davies support. After exploration of the abdomen, proctosigmoidectomy is performed transabd-

minally with proximal ligation of the inferior mesenteric artery. The sigmoid colon is pulled through the anal canal, then an anastomosis is performed in the anal canal using one-layer interrupted suture of 000 polyglycolic acid. Finally, a temporary loopileostomy is constructed.

Results

The outline of the patients' profile is shown in Table 1. The tumor was located in the lower rectum in all patients, with the bottom line at 1.0-2.5 cm apart from the dentate line (DL). Three patients had early carcinoma of sm in the depth of invasion. Case 1 had I s-v carcinoma of 5.0 x 6.5 cm in size. Case 3 showed advanced multiple carcinoma of ss in the depth of invasion. Lymph node involvement was graded as n0 in all cases (Table 1).





Case 1. A 66-year-old woman. Villous tumors were observed in a wide range of the area immediately above the DL (Fig. 1). In the resected specimen, elevated lesions of 5.0 x 6.5 cm in size was observed immediately above the DL. Most of the lesions were histopathologically observed to be tubulovillous adenoma, while well differentiated adenocarcinoma of sm was noted in some area (Fig. 2).

Case 2. A 69-year-old man. Lesions of Ila+IIc was observed at 2.5 cm above the DL. Well differentiated adenocarcinoma of 3.0 x 2.5 cm in size was noted in the resected specimen. The depth of invasion was graded as m in most of the area while sm infiltration was noted in some area, and was diagnosed as sm₁ (Fig. 3)

Case 3. A 60-year-old woman. Elevated lesions were observed at two sites in the lower rectum on the contrast enema (Fig. 4). Ultrasonic endoscopy suggested infiltration of slightly deeper area than the pm layer (Fig. 5). In the resected specimen, an advanced carcinoma of type 2, 3.5 x 2.5 cm in size, ss mural invasion, and an m carcinoma of I sp on the anal side were observed. Moreover, an Is, sm carcinoma was observed at 1 cm above the DL, which was diagnosed as sm₃ (Fig. 6).

Case 4. A 60-year-old man. Elevated lesions were observed in the lower rectum on the contrast enema (Fig. 7),

Table 1. Clinicopathologic features of patients with abdominotransanal rectal resection

| Age | Sex | DL~ (cm) | Gross type | Tumor size (cm) | Histological classification | Depth of invasion | n | |
|-----|-----|-------------------|-----------------|-------------------------------------|--------------------------------|----------------------|-------------|---|
| 66 | F | 1 | I s-v | 5.0 × 6.5 | well (tubulovillous) | sm (1) | 0 |  |
| 69 | M | 2.5 | II a+ II c | 3.0 × 2.5 | well | sm (1) | 0 |  |
| 60 | F | 1.0 3.0 4.0 | I s I p 2 | 1.2 × 1.0 0.7 × 0.8 3.5 × 2.5 | well well mode | sm (3) m ss | 0 0 0 |  |
| 60 | M | 2.5 | I s | 2.5 × 2.0 | well | sm (3) | 0 |  |

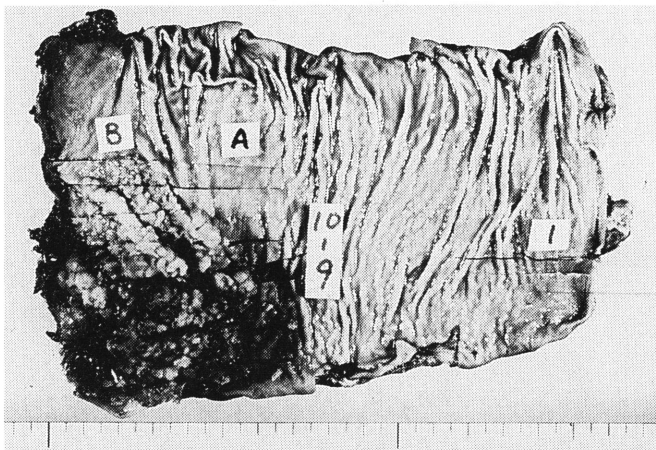


Fig. 1. Case 1. A 66-year-old woman. Villous tumors were observed in a wide range of the area above the dentate line.

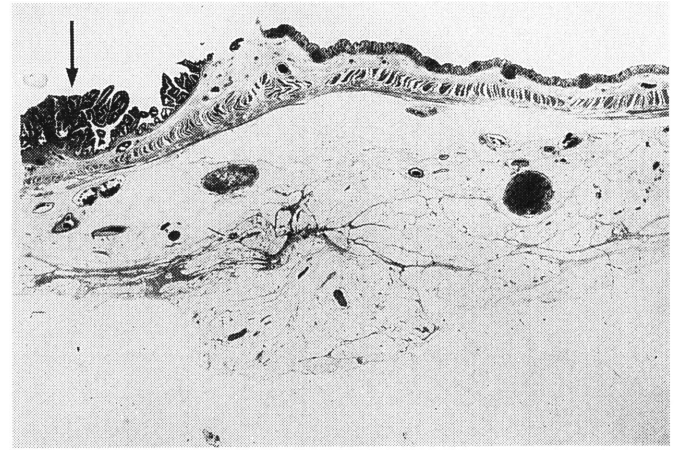


Fig. 2. Case 1. well differentiated adenocarcinoma of sm was noted in some area (arrow)

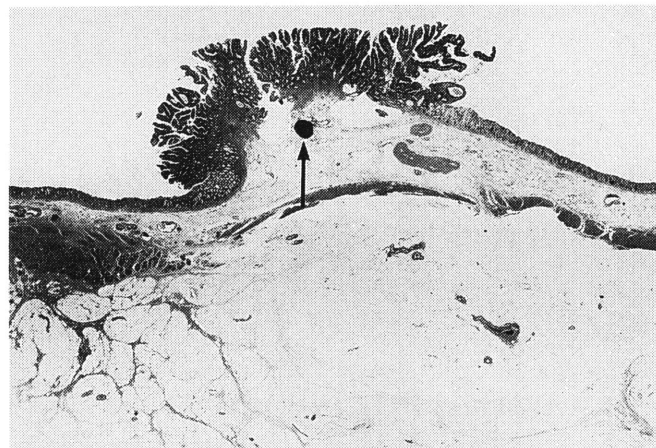


Fig. 3. Case 2. A 69-year-old man. II a+ II c adenocarcinoma (well differentiated) was observed. (arrow: sm invasion)

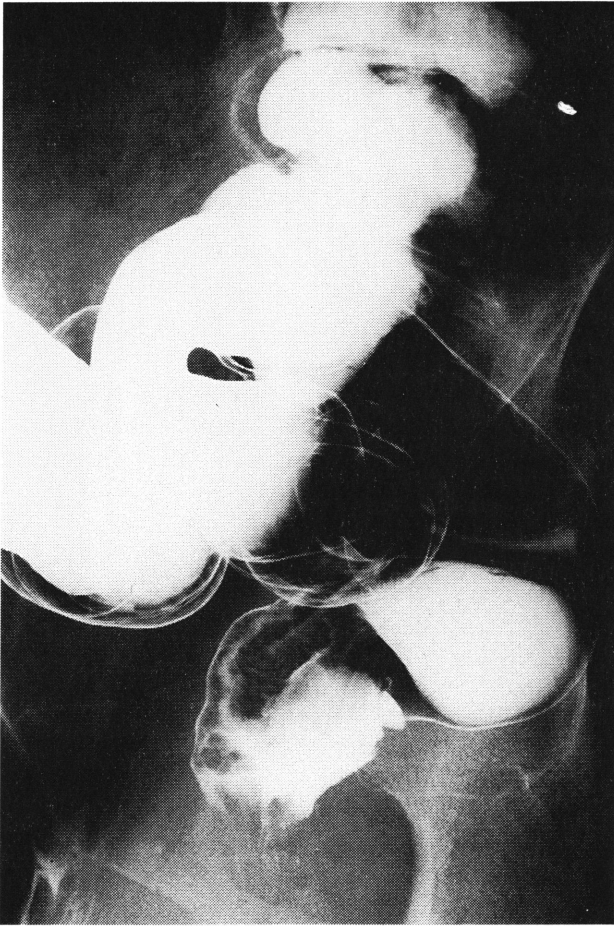


Fig. 4. Case 3. A 60-year-old woman. Elevated lesions were observed on the contrast enema.

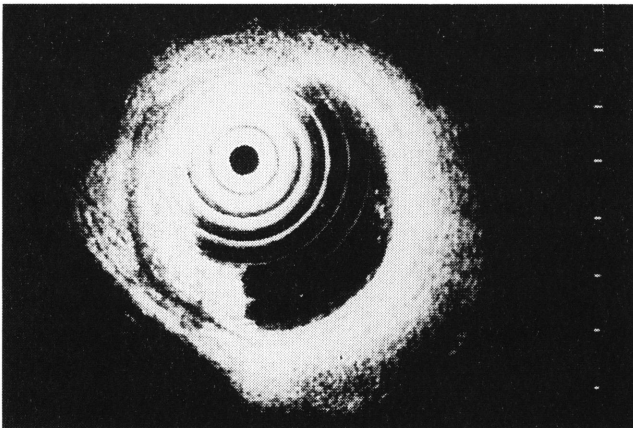


Fig. 5. Case 3. Ultrasonic endoscopy.

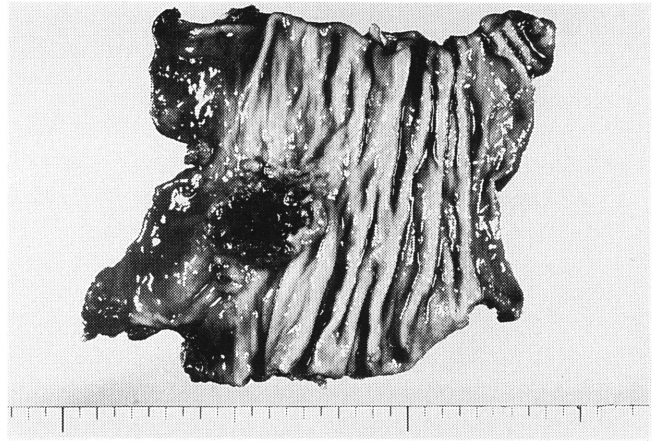


Fig. 6. Case 3. In the resected specimen, multiple carcinoma of type 2. Isp and Is were observed.

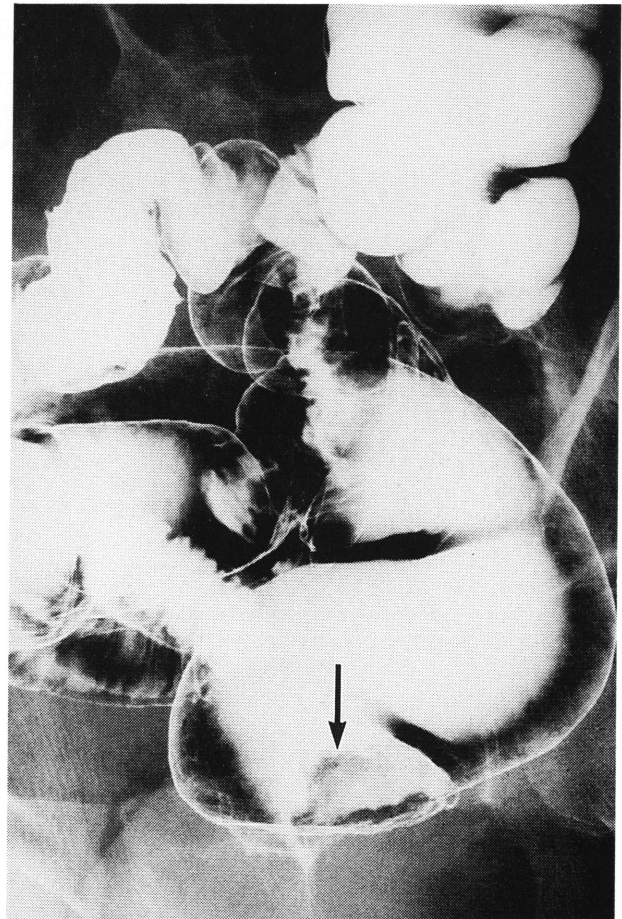


Fig. 7. Case 4. A 60-year-old-man. Elevated lesion was observed on the contrast enema.

and well differentiated adenocarcinoma was diagnosed on biopsy. Although transanal local resection was performed, because the tumor was 2.5 x 2.0 cm in size, ow (-), aw (+) and sm₃ (Fig. 8), abdominotransanal rectal resection was carried out for the purpose of radical resection.

Since diverting colostomy or ileostomy was performed

in all cases, anastomotic leakage was not observed, and oral uptake became possible within one week after the surgery. Stoma was closed two months after the surgery. The frequency of defecation decreased from about 10 times a day immediately after surgery to 3-5 times a day 3-4 months later. The manometric study in the rectum con-

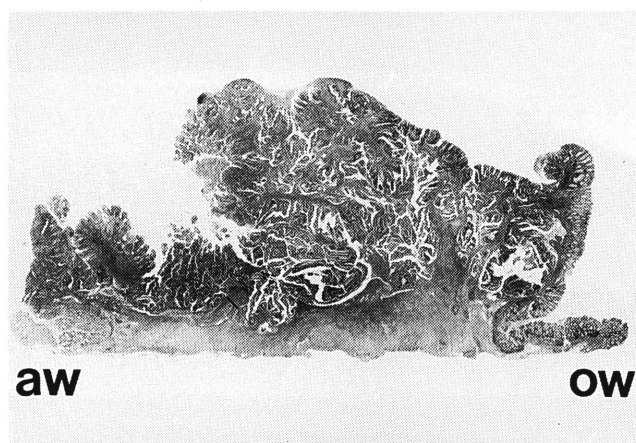


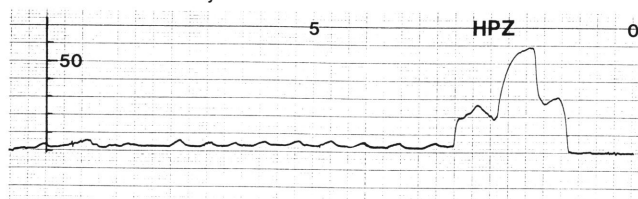
Fig. 8. Case 4. The tumor was 2.5 × 2.0 cm in size, aw (-), aw (+) and sm₃.

ducted four months after surgery demonstrated favorable function of the sphincter muscle and intrarectal response to balloon stimulation was also satisfactory (Fig. 9).

Discussion

For the surgical treatment of carcinoma of the lower rectum, abdominoperineal rectal resection established in 1908 by Miles has been extensively performed. Recently, however, along with the spread of the idea of quality of life, sphincter-saving operations have been indicated to an increasing number of cases. The sphincter-saving operations can be roughly classified into three types: 1) sacral resection by Mason et al.,¹⁾ 2) abdomino resection, and 3) abdomino anal resection.^{2,3)} Because the abdominotransanal rectal resection preserves the internal sphincter ani and levator ani muscles, it provides satisfactory bowel function after surgery, and, in addition, it enables lymph node dissection to the same extent as anterior resection. Thus, it can be indicated to a wide range of cases of carcinoma of the lower rectum. Yamamura et al.⁴⁾ revised the technique of Parks,²⁾ and attempted colonic J pouch reservoir to neutralize the peristalsis of the sigmoid colon and to obtain the retention pouch mechanism. They have applied the technique to cases of carcinoma of the lower rectum and reported satisfactory results. They suggested its indications are 1) cases of carcinoma mainly localized in the lower rectum, in which the depth of invasion is graded to be pm, and the border of the tumor on the anal side is 1 cm or more apart from the dentate line on the adoral side; 2) cases of carcinoma which is mainly localized in the upper rectum but some area occupies Rb; and 3) cases in which the lower border of the tumor is within one cm from the dentate line on the adoral side, or the invasion is deeper than pm, but can be considered an indication of this technique as a result of preoperative intraluminal irradiation and partial resection of the internal sphincter ani. With respect to our cases,

Case 2. A 69 - year - old man.



Case 3. A 60 - year - old woman.

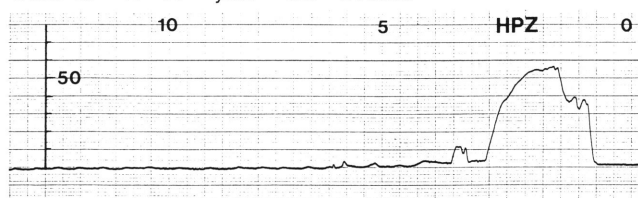


Fig. 9. The manometric study.

Case 1 was regarded as a good indication of this technique because the lower border of the tumor was one cm apart from the dentate line on the adoral side, and the tumor was relatively large (5.0 × 6.5 cm in diameter). In Case 3 with advanced carcinoma, there will be on problem about the type 2 advanced carcinoma with ss mural invasion, because lymph node dissection to the same extent as anterior resection was conducted. The sm₃ mural invasion in the Is lesion at one cm above the DL on the anal side is considered a risk factor of local recurrence, and strict follow-up is required.

Because transanal anastomosis is conducted, the procedure of this technique is not necessarily more difficult than anterior resection in which mechanical anastomosis is performed at a very low position. Moreover, creation of diverting stoma makes this technique a safe method with low risks of anastomotic leakage. Experiences in a larger number of patients and expansion of the indication are desired in the future.

Acknowledgment

The authors would like to thank Dr. Nobuko Kurosaki for her technical assistance on manometric study.

References

- 1) Mason AY: Transphincteric approach to rectal lesions. *Surg Annu* 1977, 9, 171-174
- 2) Parks AG, Percy JP: Resection and sutured colo-anal anastomosis for rectal carcinoma. *Br J Surg* 67, 301-304, 1982
- 3) Basso N, Mineruini S and Marcelli M: Modified abdominotransanal resection for cancers of the lower third of rectum. *Dis Colon Rectum*. 30, 641-643, 1987
- 4) Yamamura T, Utsunimiya J, Kusunoki M et al: Anoabdominal rectal resection and colonic J pouch anal anastomosis for distal carcinoma of the rectum, *Gastroente Surg*. 12, 1381-1392, 1989