

Left Ventricular Thrombus in Cardiomyopathy : Echocardiographic Assessment

Noriyuki KOSE, M. D.,¹⁾ H. MORI, M. D.,²⁾ H. YAMANAKA, M. D.,²⁾ Y. HAGA, M. D.,²⁾ K. IZUMIKAWA, M. D.,²⁾
A. SHIMIZU, M. D.,³⁾ K. YANO, M. D.,³⁾ K. HARA, M. D.,⁴⁾

Department of Internal Medicine, Nagasaki Memorial Hospital, Nagasaki, Japan.¹⁾

Department of Internal Medicine, Izumikawa Hospital, Nagasaki, JAPAN.²⁾

Third Department of Internal Medicine, School of Medicine, Nagasaki University³⁾

Second Department of Internal Medicine, School of Medicine, Nagasaki University⁴⁾

24-year-old female presented congestive heart failure caused by dilated cardiomyopathy and two patterns of the left ventricular thrombus.

Protruding thrombus, formed on the 8th day of hospitalization, was successfully dissolved by the intravenous administration of urokinase within a day. Echo-lucent thrombus, formed on the 23rd day of hospitalization, revealed dynamic intracardiac motion during cardiac cycle and has remained all through the clinical course. The pulsed Doppler echocardiography showed altered, disturbed flow patterns and low flow velocity in the region adjacent to the apex.

It is concluded that the intraventricular thrombus was possibly formed by blood stasis.

Case report : 24-year-old female was admitted to hospital on June 4th, 1993 because of general malaise which had been continuing for two months. The chest x-ray demonstrated cardiomegaly (CTR = 63.4%) with dilatation of the left atrium and bilateral pulmonary congestion (Fig. 1).

The patient presented short stature with 143 cm in height, and weighed 42 kg. She had webbed neck, shield-like appearance of anterior chest, cubitus valgus, low hairline, scoliosis, brachydactyly of the fifth digit in both fingers and toes. Neither mental retardation nor gonadal abnormality was detected. Complete blood count was normal. Serum GOT was 46 U; GPT 33 U, LDH 857 U. Chromosome analysis demonstrated a normal 46, xx karyotype. Clinical features were consistent with Noonan syndrome.

Echocardiography on admission revealed global hypokinesis of the left ventricular wall with mild dilatation of the left atrium (LAD = 44 mm) (Fig. 2). EF (ejection fraction) was 11% and FS (fractioning shortening) was 6% (Fig. 2). Although no left ventricular thrombus was detected, mild pericardial effusion was detected (Fig. 3). The left ventricular wall thickness was 15.9 mm in the anterior wall, 13.3 mm in the posterior and the lateral wall

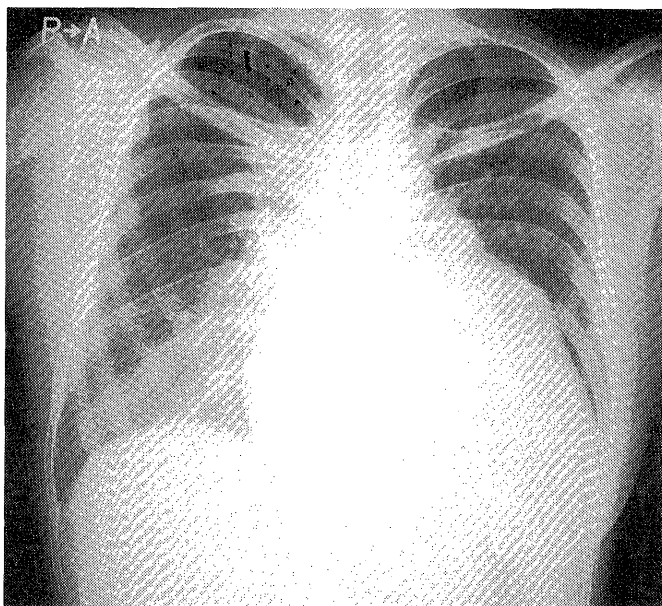


Fig 1. Chest x-ray on admission showing cardiomegaly with dilatation of the left atrium.

respectively, 18.8 mm in the anterior part of IVS (inter-ventricular septum) and 16.2 mm in the posterior part of IVS (Fig. 3). SAM (systolic anterior movement of the mitral leaflet) was not detected. Colour flow images showed mild MR (mitral regurgitation), moderate TR (tricuspid regurgitation) and mild PR (pulmonary regurgitation). TR was possibly caused by coaptation failure between the anterior and the posterior leaflet of the tricuspid valve.

On the eighth day of hospitalization, left ventricular protruding thrombus (30.2 mm in length, 19.1 mm in width) was detected with mildly broad base attached to the endocardium of the inferior wall of the left ventricle (Figure 4-a, b). It revealed no abnormal intracavitary

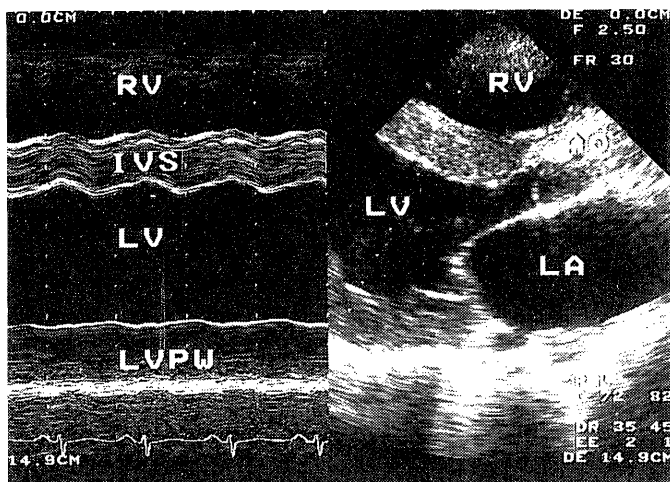


Fig 2. Long axis view of the echocardiography (right figure) and M-mode recording shows akinesis of the left ventricular posterior wall (left figure).

Ao : aorta, IVS : interventricular septum,
 LA : left atrium, LV : left ventricle,
 LVPW : left ventricular posterior wall,
 RV : right ventricle

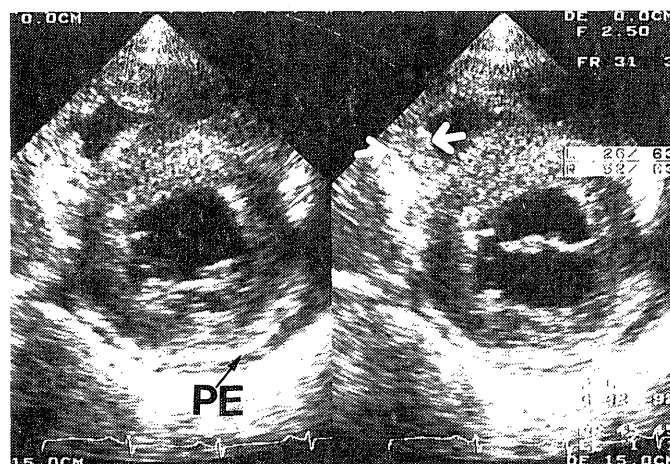


Fig 3. Short axis view at the level of the mitral valves. Slender arrow indicates mild pericardial effusion (left figure). Although biventricular free wall and IVS are diffusely thickened, anterior part of IVS is thickened particularly. Right ventricular free wall is interlocated between two arrows (right figure).

PE : pericardial effusion

motion. The acoustic echoic density was heterogeneous. Although the base of the thrombus showed a little higher echoic density than that of the adjacent myocardium, the tip of the thrombus revealed bright and much higher echoic density than that of its base (Fig. 4-a).

72,000 Unit of urokinase was administered intravenously for two hours and 10,000 Unit of heparin was administered intravenously at the rate of 417 U/hr. The protruding thrombus had disappeared completely twenty-one hours

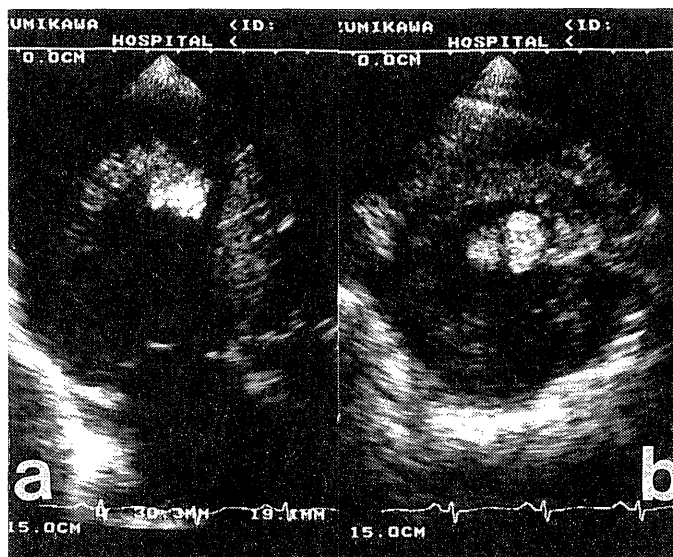


Fig 4. Left anterior view of the left ventricle demonstrates protruding thrombus based at the endocardium of the inferior wall. (Figure a). Transverse section at the tip of the thrombus reveals bright and high echoic density, which indicates fresh thrombus (Figure b).

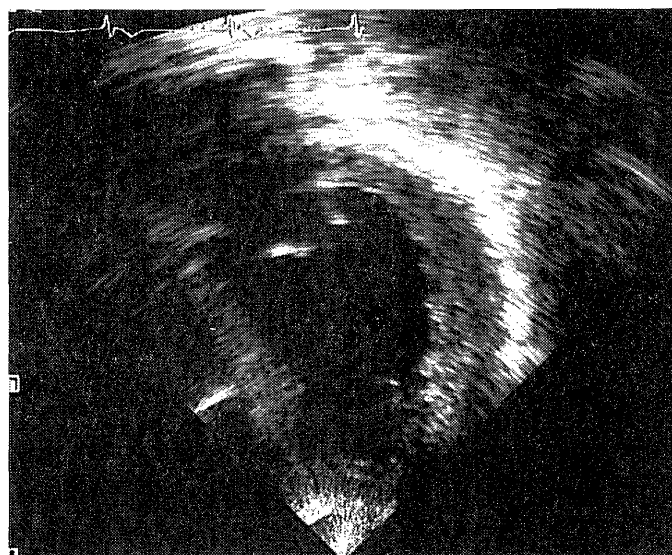


Fig 5. The protruding thrombus had completely disappeared 21 hours after thrombolytic therapy.

after the thrombolytic therapy. (Fig. 5). Another 10,000U of heparin was intravenously administered one more day and 60,000 U of urokinase was bolously injected intravenously more three days consecutively.

On the twenty-third day of hospitalization, EF was 20%. Another semifluid type of the thrombus was detected in the left ventricle, which was broadly based along the endocardium of the inferior wall and the inter-ventricular septum from the apex to the left ventricular

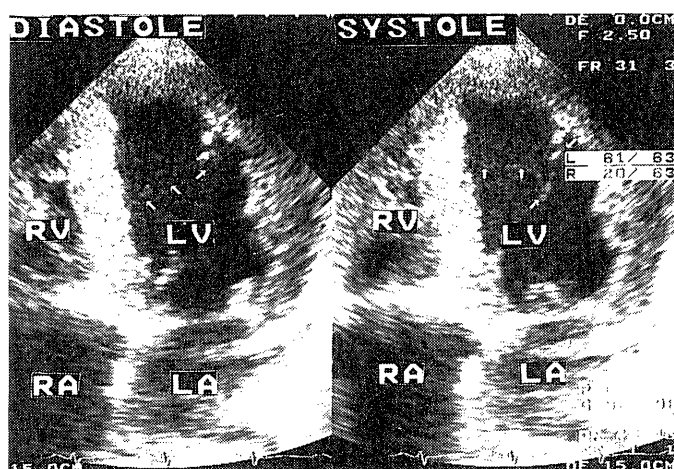


Fig 6. Four chamber view of the heart on the 23 rd day of the hospitalization. Semifluid type of thrombus is detected along the endocardium of the inferior wall to the left ventricular outflow tract (arrow indicates the margin of the thrombus).

LA : left atrium, LV : left ventricle,
RA : right atrium, RV : right ventricle

outflow tract. The density of the semifluid thrombus was echo-lucent containing floating glittery materials. The surface of the thrombus was covered by a thin, higher echoic layer. The margin of the echo-lucent lesion showed dynamic undulating motion from the inferior wall toward the left ventricular outflow tract in accordance with the cardiac cycle (Fig. 6). The pulse Doppler technique on the same day revealed variable blood flow patterns. The velocity of early diastolic filling of the transmitral flow was 0.4 m/sec, the atrial velocity was 0.22 m/sec (Fig. 7-a). Two or three distinct peaks of inflow was also detected with displaying sampling volume at the center of the left ventricle : 5 cm away centrally from the endocardium of the apex (the velocity of passive filling was 0.22 m/sec ; atrial velocity was 0.31 m/sec) (Fig. 7-b). Only disturbed signals with bidirectional low flow velocities (0.15 m/sec, respectively) were observed from the apex to 4 cm away centrally all through cardiac cycle (Fig. 7-c), which were not accompanied by two or three distinct peaks. The echo-lucent thrombus has been observed constantly since then regardless of anticoagulant therapy.

The patient revealed increased value of serum LDH consistently. Enhanced abdominal CT revealed multiple infarctions in the liver and small wedge-shaped infarctions in the bilateral kidneys. The patient followed a uneventful course.

-DISCUSSION-

The incidence of Noonan syndrome has been estimated to occur one in 1000 to 2000 of the population¹⁾²⁾. It may be the

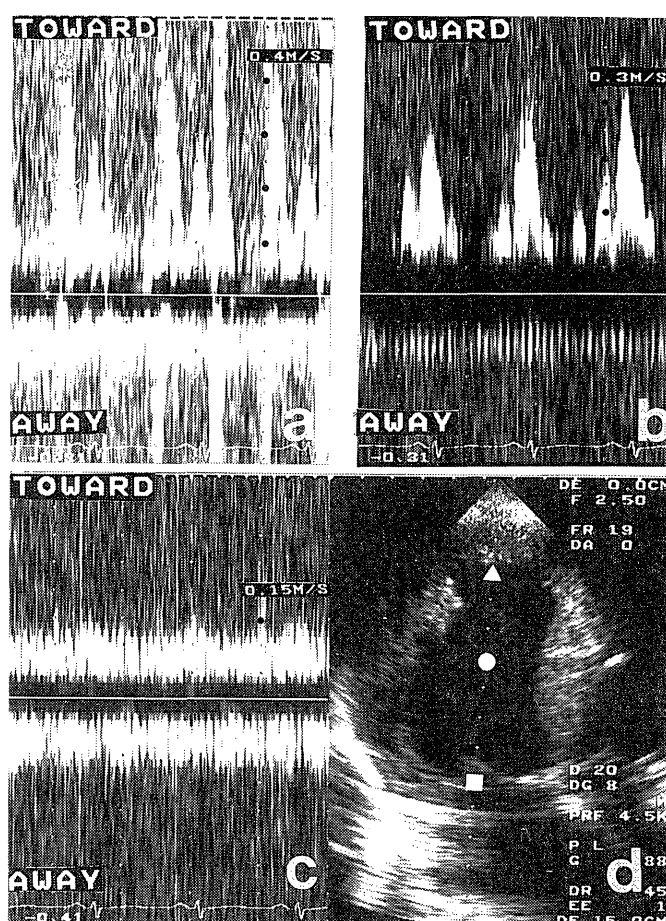


Fig 7. Pulsed Doppler echocardiography demonstrates normal two peaks of the transmitral inflow pattern when the sampling volume is placed just above the closure point of the mitral valves (Fig 7-a, d). When displacing the sampling volume at the center of the left ventricular cavity, the velocity of the rapid filling is lower than that of the atrial contraction (Fig 7-b, d). Bidirectional, disturbed flow is observed with shifting the sampling volume at the apex. (Fig 7-c, d), The site of the sampling volume of Figure. a, b, c is noted as the white sign of square, circle and triangle respectively.

second commonest syndrome associated with congenital heart disease after Down's syndrome³⁾. Approximately 50 % of the patients with Noonan syndrome have cardiac defect²⁾. The commonest cardiac lesions are pulmonary stenosis (62 %), and hypertrophic cardiomyopathy (20 %) in the study of 151 patients with Noonan syndrome³⁾. Others are ASD (atrial septal defect), VSD (ventricular septal defect), PDA (patent ductus arteriosus) and ECD (endocardial cushion defect)³⁾. Numerous cases associated with HCM have been reported up to date^{4), 5), 6), 7), 8)}.

Generally, left ventricular thrombus is detectable in the patients with acute myocardial infarction, left ventricular aneurysm and DCM^{10), 11), 12)}. Apex is the most susceptible to the thrombus formation in the case of acute myocardial infarction^{11), 13)}. High incidence of the left ventricular

thrombus is indicated in the patients with a low ejection fraction (EF) : particularly in the patients with EF under 30 %¹¹⁾. Our patient showed marked low EF and appeared to have abnormal intracardiac hemodynamic circumstances to produce the left ventricular thrombus.

Mikel et. al.¹⁴⁾ describes three patterns of the left ventricular thrombus : (1) endocardial thrombus (mural or protruding) ; (2) tail-shaped mass ; (3) intracavitary echocardiographic pattern of regional blood stasis. The tail-shaped mass and intracavitary echocardiographic pattern is supposed to be identical with mobil tail (red tail) and vigorous motion of the intracavitary margin of a left ventricular thrombus respectively, which were classified by Hawgland et. al.¹⁵⁾. The first protruding thrombus in our case may comprise lines of Zahn, platelet-fibrin lamella with leukocytic margination interspersed among fragmented erythrocytes¹⁶⁾. The histological components of the thrombus could reflect the high echoic density of it. In case of our second thrombus, the central echo-lucent thrombus may be liquid rather than solid nature, and may indicate the red cell and fibrin components histologically^{14), 15)}. The liquid nature is deduced from dynamic, undulating motion of the intracavitary margin of the echo-lucent thrombus in accordance with cardiac cycle. The echo-lucent lesion contained floating, glittery materials and was covered by a thin outer layer with acoustically high density. Although the exact histological components of them are not clear, echo-lucent lesion was possibly sluggish blood stasis containing scattered fibrin, and without platelet lamella. The quantities of fibrin and platelet within the echo-lucent lesion may be smaller than that of tail-shaped thrombus with non-fragmented erythrocytes enmeshed in a fibrin net work, with minimal or no platelet lamella^{14), 15), 16)}.

Mural thrombus occurs in up to 60 % of cases of DCM and 50 % of cases of left ventricular aneurysm at postmortem examination¹⁰⁾. The protruding thrombus in our case was possibly formed by blood stasis following aggravation of congestive heart failure induced by DCM, in addition to poor anticoagulant therapy. The blood stasis can be proved from the results of pulsed Doppler echocardiography. It showed altered blood flow, stagnation and low flow velocity within the left ventricular cavity near apex. It has not been proven why blood in areas of stasis can obtain echogenicity. Mikel et. al.¹⁴⁾ infers that the echogenicity of blood components may also depend on factors related to blood flow, including rheologic and biochemical properties, and changes in the physical alignment of potentially echogenic blood components in the area of blood stasis. Our results can support the notion of Mikel et. al.

The lasting increase of serum LDH value may reflect the multiple liver infarction and bilateral renal infarctions as

well as the destruction of cardiac muscle induced by aggravated cardiomyopathy. The embolic episode is significantly higher for thrombi that displayed intracavitary motion, protruding shape and central echo lucency¹⁵⁾. Therefore, either protruding thrombus or red tail and echo-lucent thrombus had possibly been formed more than once in the past, and had some chances of general thromboembolism in this case.

Well-controlled anticoagulant therapy and strict echocardiographic observation are necessary in order to prevent the intracavitary thrombus formation and thromboembolism in the patients with DCM.

REFERENCES

- 1) Sharland M, Burch M, McKenna WM, Paton MA. A clinical study of Noonan syndrome. *Arch Dis Child* 67 (2) : 178-183, 1992.
- 2) Pongratz G, Friedrich M, Unverdorben M, Kunkel B, Bachmann K. Hypertrophic obstructive cardiomyopathy as a manifestation of a cardiocutaneous syndrome (Noonan syndrome). *Klin Wochenscher* 69 (20) : 932-936, 1991.
- 3) Goens MB, Campbell D, Wiggins JW. Spontaneous chylothorax in Noonan syndrome. *Am J Dis Child* 146 (12) : 1453-1456, 1992.
- 4) Woo YC, Foo KF, Chan A. Hypertrophic cardiomyopathy in Noonan's syndrome --A case report. *Singapore Med J* 28 (5) : 462-467, 1987.
- 5) Fisher E, Weiss EB, Michals K, DuBrow IW, Hastrieter AR, Matalon R. Spontaneous chylothorax in Noonan's syndrome. *Eur J Pediatr* 138 (3) : 282-284, 1982.
- 6) Doiyama K, Hirose K, Fujiwara H. Asymmetric septal hypertrophy in a 41-year-old woman with Noonan's syndrome. *Chest* 97 (6) : 1480-1481, 1990.
- 7) Sonesson SE, Fouron JC, Lessard M. Intrauterine diagnosis and evolution of a cardiomyopathy in a fetus with Noonan's syndrome. *Acta Paediatr* 81 (4) : 368-370, 1992.
- 8) Alday LE, Moreyra E. Secondary hypertrophic cardiomyopathy in infancy and childhood. *Am Heart J* 108 (4) : 996-1000, 1984.
- 9) Shimizu A, Oku Y, Matsuo K, Hashiba K. Hypertrophic cardiomyopathy progressing to a dilated cardiomyopathy-like feature in Noonan's syndrome. *Am Hear J* 123 (3) : 814-816, 1992.
- 10) Reeder GS, Tajik AJ, Seward JB. Left ventricular mural thrombus : two-dimensional echocardiographic diagnosis. *Mayo Clin Proc* 56 : 82-86, 1981.
- 11) Beppu S, Park YD, Sakakibara H, Nagata S, Nimura Y. Clinical features of intracardiac thrombosis based on echocardiographic observation. *Jap Cir J* 48 : 75-81, 1984.
- 12) Asinger RW, Mikell FL, Elsperger J, Hodges M. Incidence of left ventricular thrombosis after acute transmural myocardial infarction. *New Eng J Med* 305 (6), 297-302, 1981.
- 13) Asinger RW, Mikell FL, Sharma B, Hodges M. Observations on detecting left ventricular thrombus with two dimensional echocardiography : Emphasis on avoidance of false positive diagnosis. *Am J Cardiol* 47 : 145-156, 1981.
- 14) Mikell FL, Asinger RW, Elsperger KJ. Regional stasis of blood in the dysfunctional left ventricle : Echocardiographic detection and differentiation from early thrombosis. *Circulation* 66 (4) : 755-763, 1982.
- 15) Haugland JM, Asinger RW, Mikell FL, Elsperger J, Hodges M. Embolic potential of left ventricular thrombi detected by two-dimensional echocardiography. *Circulation* 70 (4) : 588-598, 1984.
- 16) Mikell FL, Asinger RW, Elsperger KJ, Anderson WR, Hodges M. Tissue acoustic properties of fresh left ventricular thrombi and visualization by two dimensional echocardiography : Experimental observations. *Am J cardiol* 49 : 1157-1165, 1982.