

Decreasing the Pressure Gradient of the Left Ventricular Outflow Tract by Single-lead VDD Pacing in a Patient with Hypertrophic Obstructive Cardiomyopathy

Satoshi IKEDA¹⁾, Takayuki YOSHINAGA¹⁾, Kikuko OBASE¹⁾, Kouichirou SONODA¹⁾, Kousuke SHIOGUCHI¹⁾, Eisuke KAWAHARA¹⁾, Norihiko SENJYU¹⁾, Kyouji NISHIJIMA¹⁾, Yoshiyuki MIYAHARA¹⁾, Tsuneo FUJIWARA²⁾, Hironobu KOGA²⁾, Shigeru KOHNO¹⁾

1) Second Department of Internal Medicine, Nagasaki University School of Medicine

2) Miyazaki Hospital

A 59-year-old woman with hypertrophic cardiomyopathy of 8 years duration, who had been taking β -blocker, was admitted to our hospital for exertional dyspnea and previous syncope. Cardiac catheterization showed a prominent left-ventricular outflow tract (LVOT) pressure gradient, and hypertrophic obstructive cardiomyopathy (HOCM) was diagnosed. To reduce LVOT obstruction, we implanted a single-lead VDD-mode pacemaker. Cardiac catheterization after the implantation revealed a remarkable decrease in the LVOT pressure gradient with short atrioventricular delay, 80 msec, and her symptoms disappeared. A single-lead VDD pacemaker is also a useful treatment for an HOCM patient due to the relative ease with which it can be implanted.

Key words: single-lead VDD pacing, hypertrophic obstructive cardiomyopathy (HOCM), left-ventricular outflow tract obstruction

Introduction

The degree of obstruction of the left ventricular outflow tract (LVOT) is an important determining factor in the clinical course of patients with hypertrophic cardiomyopathy (HCM). To relieve the LVOT obstruction, the initial therapeutic approach is pharmacotherapy such as β -blocker and verapamil¹⁻⁴⁾. However, many patients develop a resistance to such therapies. The next approach is either surgery involving left ventricular septal myectomy or mitral

valve replacement⁵⁻⁹⁾, or atrioventricular sequential pacing¹⁰⁻¹⁵⁾. But surgery frequently fails to reduce LVOT obstruction and leads to a 2-11 % possibility of early mortality⁵⁾. Dual-chamber pacing has been shown to induce the reduction of the LVOT pressure gradient and to lead to improvement in symptoms of hypertrophic obstructive cardiomyopathy (HOCM). Recently single-lead VDD pacing^{16, 17)} has been used widely to patients with advanced atrioventricular block. We report a decrease in the LVOT pressure gradient by single-lead VDD pacing in an HOCM patient.

Case Report

On 25 December 1998, a 59-year-old woman was admitted to our hospital for further examinations due to exertional dyspnea, chest pain and a history of syncope. She had been diagnosed as having HCM in another hospital about 8 years before and had received medicinal treatment, β -blocker, and antiplatelet therapy. On admission, electrocardiography (ECG) showed T inversion in leads I, II, aVL, aVF, and V4-V6; ST elevation in leads V1 and V2; and high voltage ($SV_1 + RV_5 = 8.59$ mV). Cardiomegaly (cardiothoracic ratio: 63.7 %) was observed by thoracic radiography (Fig. 1, left). Concentric left-ventricular hypertrophy with 17- to 19-mm wall thickness and LVOT narrowing were shown by echocardiography (Fig. 2). Hematology and biochemistry results showed iron deficiency anemia and high LDH (679 IU/l). We performed cardiac catheterization on the day of admission. Pressure study revealed a left ventricle (LV)-aorta (Ao) pressure gradient of 112 mmHg, and left ventriculography of right-anterior, oblique view showed a spade-like shape, which was compatible with HCM, during systolic phase. Coronary angiography showed no significant stenosis.

Address Correspondence: Satoshi Ikeda M.D.

Second Department of Internal Medicine, Nagasaki University School of Medicine, Sakamoto 1-7-1, Nagasaki 852-8501, Japan
TEL: +81-95-849-7280 FAX: +81-95-849-7280

E-mail: sikedan-ags@umin.u-tokyo-ac.jp

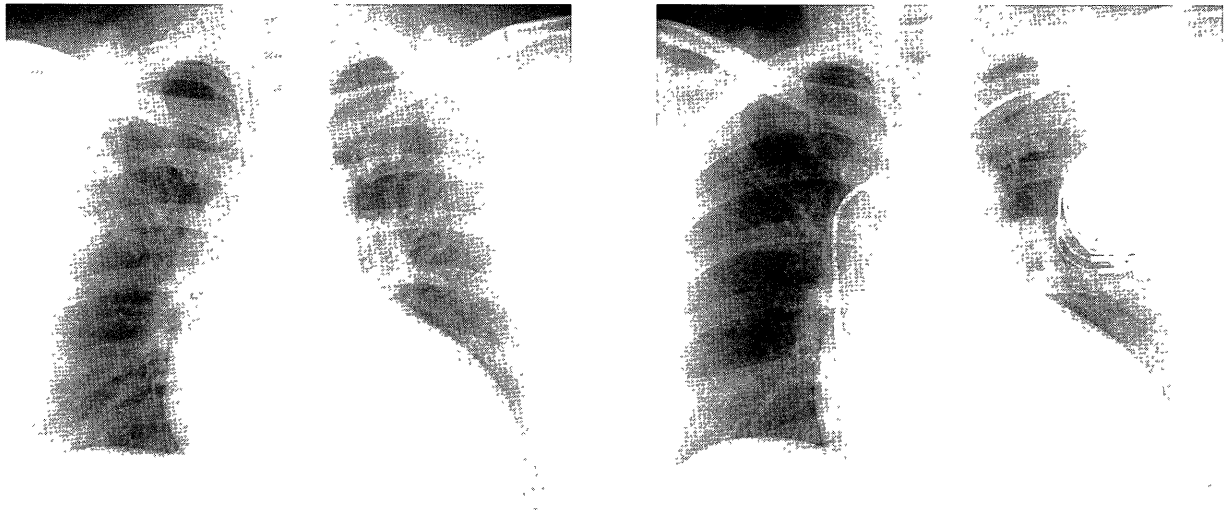


Fig. 1. Chest X-ray. Left, before implantation of pacemaker (CTR: 63.7%); right, after single-lead VDD pacemaker implantation (CTR: 61.0%). CTR: cardiothoracic ratio

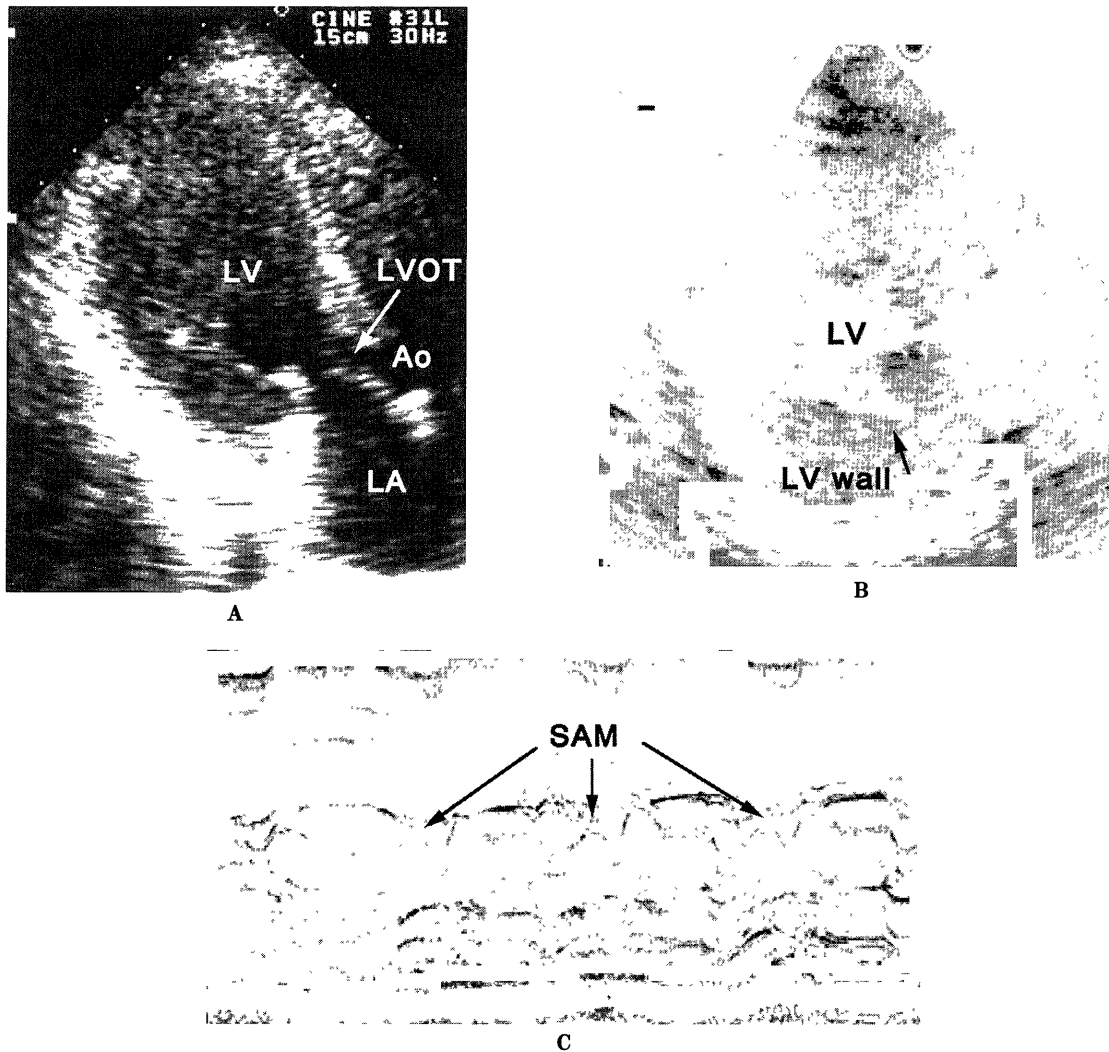


Fig. 2. Echocardiography. A, two-dimensional apical view during systolic phase; B, short axis view of LV at end-diastolic phase; C, systolic anterior movement (SAM) of mitral valve on M-mode. LV: left ventricle; LVOT: left ventricular out flow tract; Ao: Aorta; LA: left atrium.

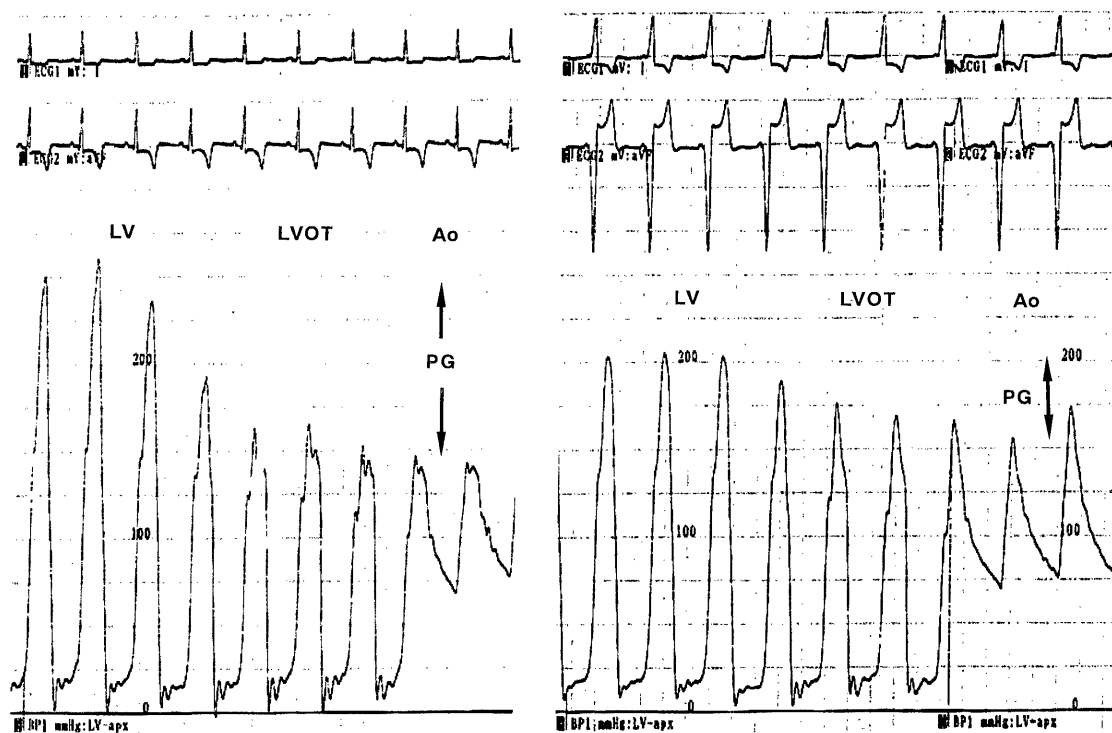


Fig. 3 Pressure curve from left ventricle to aorta before (left) and after VDD pacing (right). LV: left ventricle; LVOT: left ventricular out flow tract; Ao: Aorta; PG: pressure gradient.

Holter ECG recording showed occasional premature atrial contractions, including atrial tachycardia, but no long pause and no ventricular tachycardia that caused syncope, and no significant ST-T change.

We thought her symptoms were caused by HOCM and the pharmacotherapy was not enough to decrease the high degree of pressure gradient in LV. Therefore it was necessary for her to undergo further treatment, either atrioventricular (AV) sequential pacing or surgery. She hoped the treatment of the pacing, and we implanted her a single-lead VDD-mode pacemaker (Unity 292-07, Intermedics) on 13 January (Fig. 1, right). Before this procedure, we did not identify the acute useful effects of this treatment with temporary pacing. One reason was that she hoped early treatment and short hospitalization. Another reason was that Fananapazir et al¹²⁾ reported the acute study is not always necessary because chronic effects are more beneficial than acute effects. One week after the implantation, the second cardiac catheterization was performed. We measured the LVOT pressure gradient (Fig. 3) while changing the AV delay intervals (AV delay). As AV delay was shortened, the LV systolic pressure and the LVOT pressure gradient decreased (Table 1). There were, however, no remarkable changes under 80 msec AV delay, and so we programmed the AV delay at 80 msec. Cardiac output

Table 1. Changes of pressure in LV and Ao at various AV delay

AV delay	LVSP	AoSP	LV-AoPG
250	250	152	98
120	218	171	47
100	210	174	36
80	202	163	39
70	204	160	44
60	198	163	35

LV: left-ventricle. Ao: Aorta. LVSP: left-ventricular systolic pressure, mmHg. AoSP: Aortic systolic pressure, mmHg. LV-AoPG: Pressure gradient between left-ventricle and aorta, mmHg.

was not measured with the thermo-dilution method, because the manipulation involved in such measurements might displace the pacing lead from the endocardium. Echocardiography revealed no differences in LV function between before and after implantation of the pacemaker. After the implantation of pacemaker, her symptoms were not occurred during the hospitalization.

Discussion

Dual-chamber pacing for patients with HOCM has been shown to be an effective treatment for reduction of

LVOT obstruction and improvement of symptoms¹⁰⁻¹⁵. Jeanrenaud et al.¹² reported that decrease of the LVOT pressure gradient without decrease of arterial pressure and cardiac output was observed immediately after implantation of a DDD pacemaker, and after 3 to 30 months, the symptoms such as dyspnea, angina, and syncope, were also reduced. In another study that included a 1.5 to 3 months follow-up, the nearly identical hemodynamic changes to those reported by Jeanrenaud et al. were apparent, even when DDD pacing was discontinued¹³. A long term study (2.3 years) revealed that the LVOT pressure gradient and LV systolic pressure continued to decrease overtime, indicating an excellent prognosis¹⁴. It has been considered that these beneficial effects of DDD pacing to HOCM patients were due to the right ventricular apical preexcitation, which occurred asynchronous ventricular contraction and consequently decreased LVOT pressure gradient. Furthermore, in the long term study, chronic DDD pacing was reported to reduce LV wall thickness, especially of the basal anterior and distal anterior septal segments. Jeanrenaud and Kappenberger¹⁵ also demonstrated by echocardiography that DDD pacing reduces ventricular septal wall motion, which contributes to relieving LVOT obstruction. Regarding VDD pacing, Pak et al.¹⁸ reported that pacing shifts the end-systolic pressure-volume relation to rightward and increases end-systolic volume in LV, which reduces intracavity pressure gradient and lowers total chamber workload in HCM. Short AV delay VDD pacing is apparently superior to DDD pacing because it does not influence mean arterial pressure and stroke volume of the LV in patients with poor left ventricular function who have undergone coronary bypass surgery¹⁹. Single-lead VDD pacing was established about 10 years ago, and its use has spread. It is easier to implant a VDD pacemaker than that a DDD pacemaker because the VDD uses only one lead. Furthermore, a VDD pacemaker preserves the patients' own sinus beat better than a DDD pacemaker does. Therefore we chose VDD pacing for our patient.

The optimal AV delay is an important factor when using atrioventricular sequential pacing for HOCM patients. The pacing must always excite the right ventricular apex before normal cardiac conduction and must induce atrial contraction with sufficient ventricular volume. Reports of the optimal AV delay have varied: 75-125 msec¹³, 76 msec on average¹⁵, and 75 msec¹⁸. Jeanrenaud et al.¹² suggested that optimal AV delay should be programmed individually. We determined the most beneficial AV delay to reduce LVOT obstruction in our particular patient and programmed in the delay of 80 msec. At this delay, echocardiography

showed no remarkable change in her LV function before and after implantation of the pacemaker.

The implantation of a single-lead VDD pacemaker improved hemodynamics and symptoms in our patient. However, her intracavity pressure has remained high, about 200 mmHg, and further follow-up examination, therefore, will be required.

References

- 1) Flamm MD, Harrison DC, Hancock EW: Muscular subaortic stenosis: Prevention of outflow obstruction with propranolol. *Circulation* 38: 846-858, 1968.
- 2) Frank MJ, Abdullah AM, Watkins O, Prisant L, Stedadourous MA: Long-term medical management of hypertrophic cardiomyopathy: Usefulness of propranolol. *Eur Heart J* 4:155-164, 1983.
- 3) Rosing DR, Condit JR, Maron BJ, Kent KM, Leon MB, Bonow RO, Lipson LC, Epstein SE: Verapamil therapy: A new approach to the pharmacologic treatment of hypertrophic cardiomyopathy: III. Effects of long term administration. *Am J Cardiol* 48: 545-553, 1981.
- 4) Bonow RO, Dilsizian V, Rosing DR, Maron BJ, Bacharach SL, Green MV: Verapamil-induced improvement in left ventricular diastolic filling and increased exercise tolerance in patients with hypertrophic cardiomyopathy: Short-and long-term effect. *Circulation* 72: 853-864, 1985.
- 5) Morrow AG, Reitz BA, Epstein SE, Henry WL, Conkle DM, Itscoitz SB, Redwood DR: Operative treatment in idiopathic hypertrophic subaortic stenosis: Techniques, and the results of pre and postoperative assessments in 83 patients. *Circulation* 52: 88-102, 1975.
- 6) Maron BJ, Merrill WH, Frier PA, Kent KM, Epstein SE, Morrow AG: Long-term clinical course and symptomatic status of patients after operation for hypertrophic subaortic stenosis. *Circulation* 57: 1205-1213 1978.
- 7) McIntosh CL, Maron BJ: Current operative treatment of obstructive hypertrophic cardiomyopathy. *Circulation* 78: 487-495, 1988.
- 8) Cooley DA, Wukasch DC, Leachman RD: Mitral valve replacement for idiopathic hypertrophic subaortic stenosis: Results in 27 patients. *J Cardiovasc Surg* 17: 380-387, 1976.
- 9) Cannon RO III, McIntosh CL, Schenke WH, Maron BJ, Bonow RO, Epstein SE: Effect of surgical reduction of left ventricular outflow obstruction on hemodynamics, coronary flow, and myocardial metabolism in hypertrophic cardiomyopathy. *Circulation* 79: 766-775, 1989.
- 10) Johnson AD, Daily PO: Hypertrophic subaortic stenosis complicated by high degree heart block: Successful treatment with atrial synchronous ventricular pacemaker. *Chest* 67: 491-499, 1975.
- 11) McDonald K, McWilliams E, O'Keefe B, Maurer B: Functional assessment of patients treated with permanent dual chamber pacing as primary treatment for hypertrophic cardiomyopathy. *Eur Heart J* 9: 893-898, 1988.
- 12) Fananapazir L, Epstein ND, Curiel RV, Panza JA, Tridodi D, McAreavey D: Long-term results of dual-chamber (DDD) pacing in obstructive hypertrophic cardiomyopathy. Evidence for progressive symptomatic and hemodynamic improvement and reduction of left ventricular hypertrophy. *Circulation* 90: 2731-2742, 1994.

- 13) Janerenaud X, Vogt P, Goy JJ, Kappenberger L: Intérêt de la stimulation cardiaque physiologique dans le traitement de la cardiomyopathie hypertrophique obstructive (CMO). *Schweiz med Wschr* 122: 593-596, 1992 (in French).
- 14) Fananapazir L, Cannon RO III, Tripodi D, Panza JA: Impact of dual-chamber permanent pacing with obstructive hypertrophic cardiomyopathy with symptoms refractory to verapamil and β -adrenergic blocker therapy. *Circulation* 85: 2149-2161, 1992.
- 15) Janerenaud X, Kappenberger L: Regional wall motion during pacing for hypertrophic obstructive cardiomyopathy. *PACE* 20: 1673-1681 1997.
- 16) Percoco GF, Ansani L, Barbieri D, Guardigli G, Toselli T, Audoglio R, Antonioni GE: A new single lead VDD pacing system. *Pacing Clin Electrophysiol* 13: 1906-1909, 1990.
- 17) Katrasis D, Camm AJ: Single-lead VDD pacing: excellence or expedience? *Clin Cardiol* 14: 917-922, 1991.
- 18) Pak PH, Maughan L, Baughman KL, Kieval RS, Kass DA: Mechanism of acute mechanical benefit from VDD pacing in hypertrophied heart. Similarity of responses in hypertrophic cardiomyopathy and hypertensive heart disease. *Circulation* 98: 242-248, 1998.
- 19) Liebold A, Rogig G, Merk J, Birnbaum DE: Short atrioventricular delay dual-chamber pacing early after coronary artery bypass grafting in patients with poor left ventricular function. *J Cardiothorac Vasc Anesth* 12: 284-287, 1998.