

## Review Article

# Gastritis with Distinctive Histopathology (Non-*Helicobacter Pylori* Gastritis)

Kunihiko MURASE

Second Department of Internal Medicine, Nagasaki University School of Medicine

**Distinctive gastritis refers to gastritis with distinctive histological and endoscopic features, including the presence of granulomas, the increased number of intraepithelial lymphocytes, eosinophilic infiltration, thickening of the subepithelial collagen band, and foveolar hyperplasia. Several forms of distinctive gastritis are reviewed in this issue, since understanding of its pathogenesis and the accurate diagnosis are implicated in clinical prognostic biomarkers and lead to a new therapeutic approach.**

ACTA MEDICA NAGASAKIENSIA 46 : 9–14, 2001

**Key Words:** distinctive histology, gastritis, granulomatous gastritis, focal active gastritis, lymphocytic gastritis

## Introduction

*Helicobacter pylori* (*H. pylori*) and nonsteroidal antiinflammatory drugs (NSAIDs) are the most common causes of gastritis (1, 2). Many studies have shown that successful eradication of *H. pylori* markedly reduces the rate of peptic ulcer relapse, together with a low recurrence rate of *H. pylori* infection (3-5). Only a few patients with *H. pylori* infection treated successfully develop reflux esophagitis and other symptoms without reinfection with *H. pylori* (6-8).

A distinctive form of gastritis has recently been described in association with *H. pylori* infection (9-11). A major problem in classifying gastritis is the simultaneous coexistence of two or more types of gastritis. A low frequency of *H. pylori* infection is reported in patients with inflammatory bowel disease (IBD) (12, 13), however, there is some evidence to suggest that Crohn's disease-associated gastritis are masked by *H. pylori*

gastritis (10, 11).

Here I review several distinctive forms of gastritis to help clinicians to make the accurate diagnosis and to manage patients with non-*H. pylori* gastritis or those in whom *H. pylori* had been previously eradicated.

## Granulomatous gastritis

Granulomatous gastritis occurs in association with systemic granulomatous diseases such as tuberculosis (14), sarcoidosis (15), neoplastic disease (16), and idiopathic granulomatous gastritis (17), where the most common cause is Crohn's disease (18-20).

Crohn's disease is a chronic disease of unknown etiology that can affect any part of the gastrointestinal tract, and is characterized by aphthoid ulceration, cobble stoning, transmural chronic inflammation, and granuloma formation (18). In the proximal gastrointestinal tract, the gastric antrum and the duodenum are most frequently affected, and the encountered lesions on endoscopic examination consist of aphthoid erosions, ulcers, thickening of folds, nodules, erythema and stenosis (21). It has recently been suggested that a bamboo joint-like appearance is a characteristic endoscopic finding of Crohn's disease, representing swollen longitudinal folds traversed by erosive fissures in Crohn's disease (Fig. 1-A), although its pathogenesis is unclear (22, 23). When upper gastrointestinal symptoms are present, the clinical course may progress in parallel with activities in the ileum or the colon (19).

Chronic gastritis and duodenitis are common in patients with Crohn's disease; however, the majority of cases are not associated with *H. pylori* infection (12, 13). A few reports have stressed that previous use of sulphasalazine is associated with a reduced risk of infection with *H. pylori* in patients with Crohn's disease (24, 25). Epithelioid granuloma is considered a histological hallmark of Crohn's disease (Fig. 1-B), but such granulomas are only found in 2-5% of patients with gastric Crohn's disease (18, 19). Recently, focal active gastritis is recognized as a form of inflammation that

**Address Correspondence:** Kunihiko Murase, M.D.

Second Department of Internal Medicine, Nagasaki University School of Medicine, 1-7-1. Sakamoto, Nagasaki 852-8102, Japan  
TEL: +81-95-849-7273, FAX: +81-95-849-7285  
E-mail: murasek@net.nagasaki-u.ac.jp

seems to be typical of gastric Crohn's disease (Fig. 1-C) (26-28), which resembles focal cryptitis observed in the colonic mucosa. In our study, focal active gastritis was detected in 28% of patients with known Crohn's disease. The prevalence rate increased to 54% in *H. pylori*-negative patients with Crohn's disease, but it was not found in patients with ulcerative colitis or non-IBD patients (28). Thus, we believe that gastric involvement in Crohn's disease is not rare as previously thought. *H. pylori*-associated gastritis may mask focal active gastritis in patients with Crohn's disease, which may be identified a successful eradication of *H. pylori* (11).

Oberhuber *et al* (26) reported a high incidence of focal active gastritis in Crohn's disease and described accumulation of CD68-positive macrophages in this lesion. In our study (28), mast cells accumulated in the peripheral area of focal active gastritis, whereas macrophages accumulated in the center of the lesion. Such accumulation of mast cells and macrophages might be associated with the pathogenesis of focal active gastritis in patients with Crohn's disease.

### Lymphocytic gastritis

Lymphocytic gastritis is a new entity described in 1985 by Haot *et al* (29), and is histopathologically characterized by accumulation of intraepithelial lymphocytes on the surface and foveolar epithelium. Endoscopically, enlarged folds bearing small nodular elevations surmounted by erosions are found particularly in the corpus and the fundus.

Lymphocytic gastritis is associated with celiac disease (30, 31), *H. pylori* gastritis (31, 32), varioliform gastritis (33, 34), mucosal associated lymphoid tissue (MALT) lymphoma (35, 36), and gastric cancer (35). This suggests that the lymphocytic gastritis may be associated with an increased risk of developing lymphoma or carcinoma. We have a case of lymphocytic gastritis associated with signet ring cell carcinoma of the stomach (Fig. 2).

Patients with lymphocytic gastritis show infiltrations of neutrophils and eosinophils and mononuclear inflammatory cells, and foveolar hyperplasia in the corpus mucosa. The diagnostic threshold for accumulation of inflammatory cells in lymphocytic gastritis is usually taken as > 25 intraepithelial lymphocytes per 100 epithelial cells (37). Immunohistochemical studies have shown that the intraepithelial lymphocytes in lymphocytic gastritis are exclusively CD3 positive T cells, and approximately 80% of them are CD8 positive (37, 38). Intraepithelial lymphocytes are likely to participate in

regulation of mucosal inflammatory reaction (39, 40).

There are smaller numbers of *H. pylori* in lymphocytic gastritis than in *H. pylori*-positive patients who did not have lymphocytic gastritis (31, 41). Few studies have indicated that eradication of *H. pylori* or treatment with histamine 2 (H2) receptor antagonists or proton pump inhibitors in these patients results in a significant improvement in intraepithelial lymphocytic infiltration (42-45), although lymphocytic gastritis may, in part, represent a specific immune response to *H. pylori* (46, 47).

### Collagenous gastritis

Collagenous gastritis is an extremely rare disorder with only seven case reports in the English literature, and little is known about its etiopathogenesis and natural history (48-54). Nodular and erythematous lesions in the gastric corpus are common endoscopic findings. Biopsy specimens show a thick subepithelial band, and thickening of the collagen plate of more than 10  $\mu$ m has been proposed as a threshold criterion for the histological diagnosis of collagenous gastritis (53). Recently its associations with lymphocytic gastritis, sprue, and lymphocytic colitis as well as collagenous and lymphocytic colitis suggest a common pathogenesis that may empirically include collagenous gastritis in the same disease spectrum (50, 55). Ultrastructural examination of the gastric biopsy specimens shows a patchy subepithelial band of collagen fibers. Capillaries, lymphocytes, eosinophils, mast cells, and fibroblasts were seen entrapped in this band (53). Mast cells can induce migration and proliferation of fibroblasts and can also stimulate collagen synthesis. Mast cells entrapped in the collagen band and located in the lamina propria also showed evidence of degranulation (53, 54).

Immunohistochemical studies have shown signs of the local immune activation in all biopsy specimens, including overexpression of HLA-DR by epithelial cells, increased numbers of CD3-positive intraepithelial lymphocytes, and CD25-positive cells in the lamina propria (53, 54). These findings suggest that the histopathological lesions of collagenous gastritis may be mediated by a local immune process.

### Eosinophilic gastritis

Eosinophilic gastritis is defined as eosinophilic infiltration into the gastric wall with no evidence of parasitic or extraintestinal disease (56). Peripheral blood eosinophilia is often present, but some patients do not have this

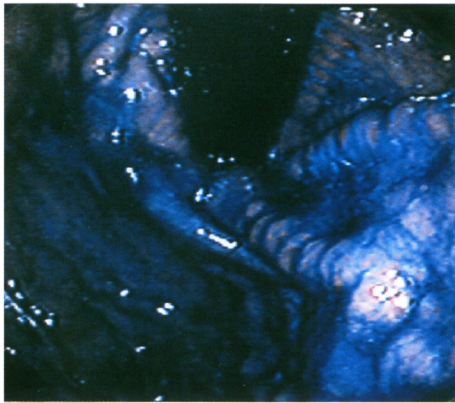


Fig. 1-A

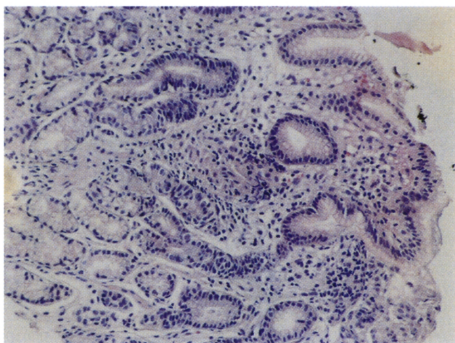


Fig. 1-B

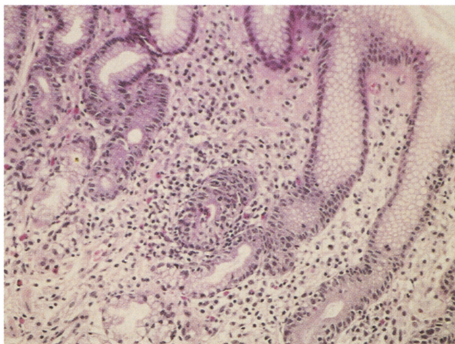


Fig. 1-C

**Fig. 1** Crohn's disease. A: Gastroendoscopy showing bamboo joint-like appearance with swollen longitudinal folds. B: Noncaseous granuloma with giant cells. Magnification,  $\times 100$  C: Focal infiltration of polymorphs and mononuclear inflammatory cells in the foveola or gastric glands. Magnification,  $\times 200$ .

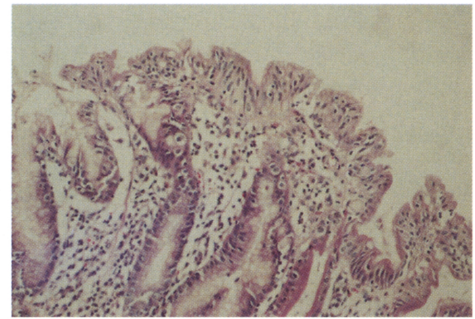


Fig. 2

**Fig. 2** Lymphocytic gastritis; Numerous lymphocytes in the epithelium. Magnification,  $\times 200$ .

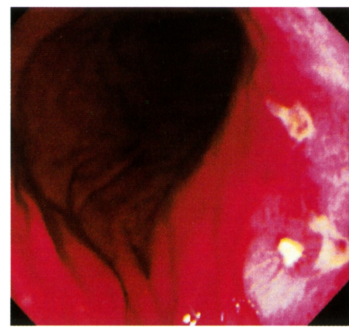


Fig. 3-A

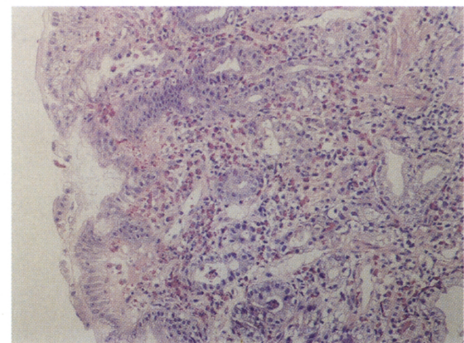


Fig. 3-B

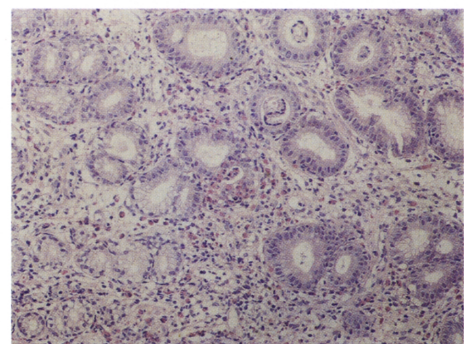


Fig. 3-C

**Fig. 3** Eosinophilic gastritis. Gastroendoscopy showing multiple gastric ulcers (A). Note the eosinophils particularly beneath the luminal epithelium (B) and sometimes within the epithelium and foveola (C). Magnification,  $\times 100$ .

finding. A portion of patients develop symptoms following ingestion of specific food, suggesting that food allergy plays a role in the pathogenesis of eosinophilic gastritis (57). Eosinophilic infiltration into the stomach occurs commonly in a variety of different inflammatory conditions, including collagen disease (58), parasitic infection (59), and drug allergy such as interferon (60).

The clinical manifestations of eosinophilic gastritis depend upon the layers of stomach involved. The involvement of a predominantly mucosal layer with ulcers tends to lead malabsorption, anemia and protein loss from gut (61) (Fig. 3-A). When the muscle layers are predominantly involved, the condition may be confused with malignancy because it often causes the gastric outlet obstruction (62, 63), in addition, the serosal involvement is frequently accompanied by eosinophilic ascites (64). Gastric antral biopsies are more productive, and eosinophils may be found prominently beneath the luminal epithelium or sometimes within the foveolum (Fig. 3-B, C).

Eosinophilic gastritis usually responds to corticosteroid, H<sub>2</sub> receptor antagonists, and proton pump inhibitor therapy (58, 61), although cases resistant to these therapies (64, 65) or those with spontaneous resolution have been reported (66).

### Hyperplastic gastropathies

Hyperplastic gastropathy can be divided into the two main categories, Menetrie's disease and hyperplastic hypersecretory gastropathy. Patients with Menetrie's disease have giant gastric folds and hypoproteinemia, on the endoscopic examination, large gastric folds (>10 mm in diameter) are found, which correspond to the echogenic thickening of the mucosal layer with or without cystic components on ultrasonography. Histopathologically, these folds represent the increased epithelial cell mass mainly consisting of mucous cells presenting elongated and sometimes cystically dilated foveola without parietal cell hyperplasia, and mildly infiltrated inflammatory cells (67). The cause of this disease is unknown, although various factors such as autoimmune, allergic, neoplastic, and infective (primarily cytomegalovirus and occasionally *H. pylori*, herpes simplex and mycoplasma) mechanisms have been proposed (68-71). Lymphocytic gastritis may share a common pathogenesis with Menetrier's disease (72). Menetrier's disease is associated with *H. pylori* in more than 90% of patients (69), and it is thought to be a special form of *H. pylori* gastritis in these patients.

In hypertrophic hypersecretory gastropathy, the parietal cells rather than the foveolar cells proliferate to form the

enlarged folds (70). Some patients with hypertrophic hypersecretory gastropathy are ultimately confirmed to have Zollinger-Ellison syndrome.

It has been reported that eradication of *H. pylori*, or the use of proton pump inhibitors or antibiotic therapy improves fold width, foveolar length, and inflammatory infiltrates in patients with hyperplastic gastropathy (71-77). Increased productions of interleukin-1 $\beta$  and hepatocyte growth factor caused by *H. pylori* infection may contribute to the fold thickening of the stomach by stimulating epithelial cell proliferation and foveolar hyperplasia in patients with enlarged fold gastritis (78).

### Acknowledgment

The author thanks Drs. Hisashi Furusu, Ken Ohnita, and Hajime Isomoto, and Prof. Shigeru Kohno from Second Department of Internal Medicine, Nagasaki University School of Medicine for their support and review of this manuscript.

### References

1. Appelman HD. Gastritis: terminology, etiology, and clinicopathological correlations: another biased view. *Hum Pathol* 25: 1006-1019, 1994
2. Dixon MF, Genta RM, Yardley JH, *et al.* Classification and grading of gastritis. The updated Sydney System. International Workshop on the Histopathology of Gastritis, Houston 1994. *Am J Surg Pathol* 20: 1161-1181, 1996
3. Cutler AF, Schubert TT. Long-term *Helicobacter pylori* recurrence after successful eradication with triple therapy. *Am J Gastroenterol* 88: 1359-1361, 1993
4. Tytgat GN. Long-term consequences of *Helicobacter pylori* eradication. *Scand J Gastroenterol (Suppl)* 205: 38-44, 1994
5. Chen TS, Chang FY, Lee SD, Lee SC. Recurrence of *H. pylori* infection and dyspeptic symptoms after successful eradication in patients cured of duodenal ulcer disease. *Hepato-Gastroenterology* 46: 252-256, 1999
6. Koster ED. Adverse events of HP eradication: long-term negative consequences of HP eradication. *Acta Gastroenterol Belg* 61: 350-351, 1998
7. Fraser AG, Schreuder V, Chua LE, Moore L. Follow up after successful eradication of *Helicobacter pylori*: symptoms and reinfection. *J Gastroenterol Hepatol* 13: 555-559, 1998
8. Bojarski C, Epple HJ, KIRSTEIN FW, *et al.* Patients with dyspepsia benefit from eradication of *Helicobacter pylori* if other organic causes for dyspepsia were carefully ruled out. *Z Gastroenterol* 38: 211-219, 2000
9. Correa P. Chronic gastritis; a clinico-pathological classification of chronic gastritis. *Am J Gastroenterol* 83: 504-509, 1988
10. Herz R, Schaube J, Meining A, *et al.* Gastritis associated with Crohn disease can be masked by *Helicobacter pylori* gastritis. *Scand J Gastroenterol* 34: 471-473, 1999
11. Jovanovic IR, Milosavljevic TN, Jankovic GP, *et al.* Clinical onset of the Crohn's disease after eradication therapy of *Helicobacter pylori* infection. Does *Helicobacter pylori* infection interact with natural history of inflammatory bowel diseases? *Med Sci Monit* 7: 137-141, 2001
12. Halme L, Karkkainen P, Rautelin Kounen TU, *et al.* High frequency of *Helicobacter* negative gastritis in patients with Crohn's disease. *Gut* 38: 379-383, 1996



13. D'Inca R, Sturniolo G, Cassaro M, *et al.* Prevalence of upper gastrointestinal lesions and *Helicobacter pylori* infection in Crohn's disease. *Dig Dis Sci* 43: 988-992, 1998
14. Singh B, Moodley J, Ramdial P, *et al.* Primary gastric tuberculosis. A report of 3 cases. *S Afr J Surg* 34: 29-32, 1996
15. Tukiainen H, Vaara J, Syrjanen K, *et al.* Granulomatous gastritis as a diagnostic problem between sarcoidosis and other granulomatous disorders. *Sarcoidosis* 5: 66-67, 1988
16. Newton C, Nochomovitz L, Sackier JM. Gastric adenocarcinoma associated with isolated granulomatous gastritis. *Ann Surg Oncol* 5: 407-410, 1998
17. Shapiro JL, Goldblum JR, Petras RE. A clinicopathologic study of 42 patients with granulomatous gastritis. Is there really an "idiopathic" granulomatous gastritis? *Am J Surg Pathol* 20: 462-470, 1996
18. Farmer RG, Hark WA, Turnbull RB. Clinical patterns in Crohn's disease: A statistical study of 615 cases. *Gastroenterology* 68: 627-635, 1975
19. Lewin KJ, Riddell RH, Weinstein WM. *Gastrointestinal Pathology and its Clinical Implications*. New York. Igaku-Shoin 858-902, 1992
20. Ectors NL, Dixon MF, Geboes KJ, *et al.* Granulomatous gastritis: a morphological and diagnostic approach. *Histopathology* 23: 55-61, 1993
21. Alcántara M, Rodríguez R, Potenciano JL, *et al.* Endoscopic and biptic findings in the upper gastrointestinal tract in patients with Crohn's disease. *Endoscopy* 25: 282-286, 1993
22. Yokota K, Saito Y, Einami K, *et al.* A bamboo joint-like appearance of the gastric body and cardia: possible association with Crohn's disease. *Gastrointest Endosc* 46: 268-272, 1997
23. Hirokawa M, Shimizu M, Terayama K, *et al.* Bamboo-joint-like appearance of the stomach: a histopathological study. *APMIS* 107: 951-6, 1999
24. El-Omar E. Low prevalence of *Helicobacter pylori* in inflammatory bowel disease association with sulphasalazine. *Gut* 35: 1385-1388, 1994
25. Parente F, Molteni P, Bollani S, *et al.* Prevalence of *Helicobacter pylori* infection and related upper gastrointestinal lesions in patients with inflammatory bowel diseases. A cross-sectional study with matching. *Scand J Gastroenterol* 32: 1140-1146, 1997
26. Oberhuber G, Puspok A, Oesterreicher C, *et al.* Focally enhanced gastritis; A frequent type of gastritis in patients with Crohn's disease. *Gastroenterology* 112: 698-706, 1997
27. Wright CL, Riddell RH. Histology of the duodenum and stomach in Crohn's disease. *Am J Surg Pathol* 9: 698-706, 1998
28. Furusu H, Murase K, Nishida Y, *et al.* Accumulation of mast cells and macrophages in focal active gastritis. *Hepato-Gastroenterology* 2001 (in press)
29. Haot J, Wallez L, Jouret-Mourin A, *et al.* La gastrite a lymphocyte. Une nouvelle entite? *Acta Endosc* 15: 187-188, 1985
30. DuBois RN, Lazenby AJ, Yardley JH, *et al.* Lymphocytic enterocolitis in patients with refractory sprue. *JAMA* 262: 935-937, 1989
31. Wu TT, Hamilton SR. Lymphocytic gastritis: association with etiology and topology. *Am J Surg Pathol* 23: 153-158, 1999
32. Dixon MF, Wyatt JL, Burke DA, *et al.* Lymphocytic gastritis--relationship to *Campylobacter pylori* infection. *J Pathol* 154: 125-132, 1988
33. Haot J, Berger F, Andre C, *et al.* Lymphocytic gastritis versus varioliform gastritis. A historical series revisited. *J Pathol* 158: 19-22, 1989
34. Wolber RA, Owen DA, Anderson FH, *et al.* Lymphocytic gastritis and giant gastric folds associated with gastrointestinal protein loss. *Mod Pathol* 4: 13-15, 1991
35. Griffiths AP, Wyatt J, Jack AS, *et al.* Lymphocytic gastritis, gastric adenocarcinoma, and primary gastric lymphoma. *Pathology* 47: 1123-1124, 1994
36. Miettinen A, Karttunen TJ, Alavaikko M. Lymphocytic gastritis and *Helicobacter pylori* infection in gastric lymphoma. *Gut* 37: 471-476, 1995
37. Feeley KM, Heneghan MA, Stevens FM, *et al.* Lymphocytic gastritis and coeliac disease: evidence of a positive association. *J Clin Pathol* 51:207-210, 1998
38. De Giacomo C, Gianatti A, Negrini R, *et al.* Lymphocytic gastritis: a positive relationship with celiac disease. *J Pediatr* 124: 57-62, 1994
39. Brandtzaeg P, Halstensen TS, Kett K, *et al.* Immunobiology and immunopathology of human gut mucosa; humoral immunity and intraepithelial lymphocytes. *Gastroenterology* 97: 1562-1584, 1989
40. Engstrand L, Scheynius A, Pahlson C. An increased number of gamma/delta T-cells and gastric epithelial cell expression of the groEL stress-protein homologue in *Helicobacter pylori*-associated chronic gastritis of the antrum. *Am J Gastroenterol* 86: 976-980, 1991
41. Wolber R, Owen D, DelBuono L, *et al.* Lymphocytic gastritis in patients with celiac sprue or spruelike intestinal disease. *Gastroenterology* 98: 310-315, 1990
42. Chakravarty B, Riley J. Treatment of lymphocytic gastritis with H2 receptor antagonist. *Aust N Z J Med* 25: 180-181, 1995
43. Bouaniche M, Chassagne P, Landrin I, *et al.* Successful treatment of protein-losing lymphocytic gastritis with proton pump inhibitor. *J Clin Gastroenterol* 25: 694-695, 1997
44. Hayat M, Arora DS, Dixon MF, *et al.* Effects of *Helicobacter pylori* eradication on the natural history of lymphocytic gastritis. *Gut* 45: 495-498, 1999
45. Muller H, Volkholz H, Stolte M. Healing of lymphocytic gastritis by eradication of *Helicobacter pylori*. *Digestion* 63: 14-19, 2001
46. Sirigu F, Dessi A, Usai P, *et al.* A retrospective study on the incidence of lymphocytic gastritis in patients with *Helicobacter pylori* infection. *Riv Eur Sci Med Farmacol* 17: 85-89, 1995
47. Niemela S, Karttunen T, Kerola T, *et al.* Ten year follow up study of lymphocytic gastritis: further evidence on *Helicobacter pylori* as a cause of lymphocytic gastritis and corpus gastritis. *J Clin Pathol* 48: 1111-1116, 1995
48. Colletti RB, Trainer TD. Collagenous gastritis. *Gastroenterology* 97: 1552-1555, 1989
49. Stolte M, Ritter M, Borchard F, *et al.* Collagenous gastroduodenitis on collagenous colitis. *Endoscopy* 22: 186-187, 1990
50. Groisman GM, Meyers S, Harpaz N. Collagenous gastritis associated with lymphocytic colitis. *J Clin Gastroenterol* 22: 134-137, 1996
51. Cote JF, Hankard GF, Faure C, *et al.* Collagenous gastritis revealed by severe anemia in a child. *Hum Pathol* 29: 883-886, 1998
52. Castellano VM, Munoz MT, Colina F, *et al.* Collagenous gastroduodenitis and collagenous colitis. Case report and review of the literature. *Scand J Gastroenterol* 34: 632-638, 1999
53. Pulimood AB, Ramakrishna BS, Mathan MM. Collagenous gastritis and collagenous colitis; a report with sequential histological and ultrastructural findings. *Gut* 44: 881-885, 1999
54. Vesoulis Z, Lozanski G, Ravichandran P, *et al.* Collagenous gastritis: a case report, morphologic evaluation, and review. *Mod Pathol* 13: 591-596, 2000
55. Christ AD, Meier R, Bauerfeind P, *et al.* Simultaneous occurrence of lymphocytic gastritis and lymphocytic colitis with transition to collagenous colitis. *Schweiz Med Wochenschr* 123: 1487-1490, 1993
56. Klein NC, Hargrove RL, Slesinger MH, *et al.* Eosinophilic gastroenteritis. *Medicine* 49: 299-319, 1970
57. el Mouzan MI, al Quorain AA, Anim JT. Cow's-milk-induced erosive gastritis in an infant. *J Pediatr Gastroenterol Nutr* 10: 111-113, 1990
58. Buchman AL, Wolf D, Gramlich T. Eosinophilic gastrojejunitis associated with connective tissue disease. *South Med J* 89: 327-330, 1996
59. Prociw P, Croese J. Human enteric infection with *Ancylostoma caninum*: hookworms reappraised in the light of a "new" zoonosis. *Acta Trop* 62: 23-44, 1996
60. Talley NJ, Shorter RG, Phillips SF, *et al.* Eosinophilic gastroenteritis; a clinicopathological study of patients with disease of the mucosa, muscle layer, and subserosal tissues. *Gut* 31: 54-58, 1990
61. Kakumitsu S, Shijo H, Akiyoshi N, *et al.* Eosinophilic enteritis observed during alpha-interferon therapy for chronic hepatitis C. *J Gastroenterol* 35: 548-551, 2000
62. Milman PJ, Sidhu GS. Case report: eosinophilic gastritis simulating a neoplasm. *Am J Med Sci* 276: 227-230, 1978
63. Karande T, Oak SN, Trivedi A, *et al.* Proximal jejunal obstruction due to eosinophilic gastroenteritis. *J Postgrad Med* 42: 121-123, 1996
64. Stolte M, Gail K, Mihaljevic L. Failure of ranitidine and proton pump inhibitor treatment in eosinophilic gastritis with ulceration. *Z Gastroenterol* 29: 426-428, 1991

65. Quan SF, Sedgwick JB, Nelson MV, *et al.* Corticosteroid resistance in eosinophilic gastritis; relation to *in vitro* eosinophil survival and interleukin 5. *Ann Allergy* 70: 256-260, 1993
66. Cazana JL, Blanco Guerra C, Crespo JF, *et al.* Eosinophilic gastritis: its spontaneous resolution. *Rev Esp Enferm Dig* 82: 51-52, 1992
67. Stamm B. Localized hyperplastic gastropathy of the mucous cell- and mixed cell-type (localized Menetrier's disease): a report of 11 patients. *Am J Surg Pathol* 21: 1334-1342, 1997
68. Jouini M, Ksontini R, Kacem MJ, *et al.* Menetrier disease associated with a gastric adenocarcinoma. Apropos of 2 cases. *Ann Gastroenterol Hepatol* 31: 341-345, 1996
69. Badov D, Lambert JR, Finlay M, *et al.* *Helicobacter pylori* as a pathogenic factor in Menetrier's disease. *Am J Gastroenterol* 93: 1976-1979, 1998
70. Komorowski RA, Caya J. Hyperplastic gastropathy. Clinicopathological correlation. *Am J Surg Pathol* 15: 577-585, 1991
71. Hochman JA, Witte DP, Cohen MB. Diagnosis of cytomegalovirus infection in pediatric Menetrier's disease by in situ hybridization. *J Clin Microbiol* 34: 2588-2589, 1996
72. Suter WR, Neuweiler J, Borovicka J, *et al.* Cytomegalovirus-induced transient protein-losing hypertrophic gastropathy in an immunocompetent adult. *Digestion* 62: 276-279, 2000
73. Charton-Bain MC, Paraf F, Bruneval P. Superficial gastric carcinoma developed on localized hypertrophic lymphocytic gastritis: a variant of localized Menetrier's disease ? *Pathol Res Pract* 196: 125-128, 2000
74. Bayerdorffer E, Ritter MM, Hatz R, *et al.* Healing of protein losing hypertrophic gastropathy by eradication of *Helicobacter pylori*; is *Helicobacter pylori* a pathogenic factor in Menetrier's disease? *Gut* 35: 701-704, 1994
75. Yoshikawa I, Murata I, Tamura M, *et al.* A case of protein-losing gastropathy caused by acute *Helicobacter pylori* infection. *Gastrointest Endosc* 49: 245-248, 1999
76. Murayama Y, Miyagawa J, Shinomura Y, *et al.* Morphological and functional restoration of parietal cells in *Helicobacter pylori* associated enlarged fold gastritis after eradication. *Gut* 45: 653-661, 1999
77. Ladas SD, Tassios PS, Malamou HC, *et al.* Omeprazole induces a long-term clinical remission of protein-losing gastropathy of Menetrier's disease. *Eur J Gastroenterol Hepatol* 9: 811-813, 1999
78. Yasunaga Y, Shinomura Y, Kanayama S, *et al.* Increased production of interleukin-1 beta and hepatocyte growth factor may contribute to foveolar hyperplasia in enlarged fold gastritis. *Gut* 39: 787-794, 1996