

Case Report

Skull Cryptococcal Osteomyelitis Complicated with Pulmonary Tuberculosis

Shintaro YOSHIDA¹⁾, Kiyoshi NAKAZAKI²⁾, Toshiyuki OE³⁾, Masahito INUYAMA³⁾, Sadamu CHIFU³⁾, Shuji SAKATA²⁾, Kuniaki HAYASHI⁴⁾

1) Department of Radiology, Higashi Saga National Hospital

2) Department of Neurosurgery, Saga Prefecture Hospital Kouseikan

3) Department of Respiratory Medicine, Higashi Saga National Hospital

4) Department of Radiology, Nagasaki University School of Medicine

A rare case of bone cryptococcosis solely involving the skull is presented. A 63-year-old man had received an antituberculous treatment for pulmonary tuberculosis. His initial symptom was a headache that was followed by a development of slow growing elastic soft mass in the right parietal region. CT scan showed a well-circumscribed smooth margined mass in the parietal bone associated with osteolytic changes. On aspiration biopsy an abscess containing abundant *Cryptococcus neoformans* was observed. He was treated with drainage and irrigation of abscess and craniectomy of the right parietal bone. He also received 200mg of oral fluconazole. About half of the patients with skeletal cryptococcosis have underlying diseases that cause abnormalities of cellular immunity (e.g., lymphoma, leukemia, sarcoidosis, TB etc), or are receiving therapies that affect cell mediated immunity (e.g., a long-term steroid therapy). It is assumed that his cell-mediated immunity was decreased because of his low lymphocyte value and his underlying disease. Clinical and radiological manifestations of bone cryptococcosis are non-specific. It should be included in the differential diagnosis, especially in the patients with bone abscess who has underlying diseases.

ACTA MEDICA NAGASAKIENSIA 48 : 77–80, 2003

Key Words: bone, infection, cryptococcosis, pulmonary tuberculosis, cell mediated immunity, fluconazole

Address Correspondence: Shintaro Yoshida, M.D.

Department of Radiology, Higashi Saga National Hospital, 7324 Nakabaracho, Miyakigun, Saga, 849-0101 Japan

E-mail: shintaro@esaga.hosp.go.jp

Introduction

Bone cryptococcosis occurs in only 5 to 10% of the patients with disseminated cryptococcosis. Moreover the disease localized to bone is very rare. A case of cryptococcal osteomyelitis of the skull that developed during the treatment of pulmonary tuberculosis is presented with review of the literature.

Case Report

A 63-year-old man had received an antituberculous treatment for 6-months using INH, REF, EB and PZA, since September 2001. He began to complain of a headache at the end of November 2001, and it became a right-sided migraine-like headache on December 2001. No abnormal neurological findings were observed. CT scan of the head obtained on December 17th was reported normal (Fig 1). Retrospectively it showed subtle abnormality in the right parietal region. He was followed-up under the treatment with anodyne but his symptom did not improve, and he developed an elastic soft mass gradually growing in the painful region. Follow up CT scan showed a mass formation in both the inner and outer tables of cranial bone with osteolytic changes (Fig. 2). The mass was well circumscribed and its margin was smooth. There was slight compression of the right parietal lobe of the brain, but no invasion into the brain parenchyma. Intracranial component of the mass showed an appearance of epidural lesion. The attenuation of the mass was slightly lower than that of the soft tissue. Bone metastasis was first suspected because of its frequency and the age of the patient. In addition, an abscess (e.g., cold abscess) was also considered as a differential diagnosis.

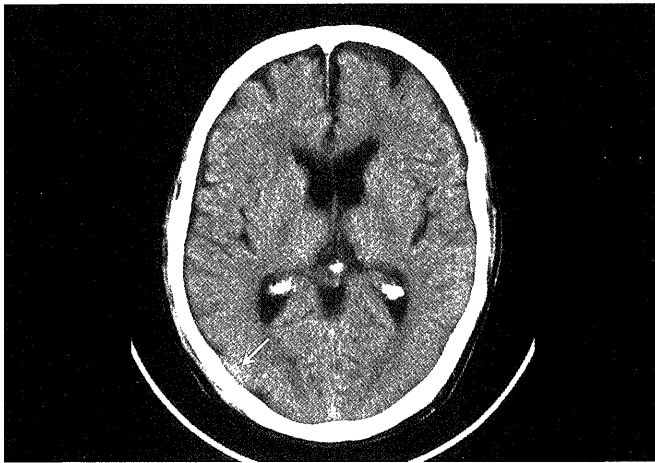


Figure 1. Initial CT scan showing minute abnormality in the right parietal bone (arrow), only appreciated retrospectively.

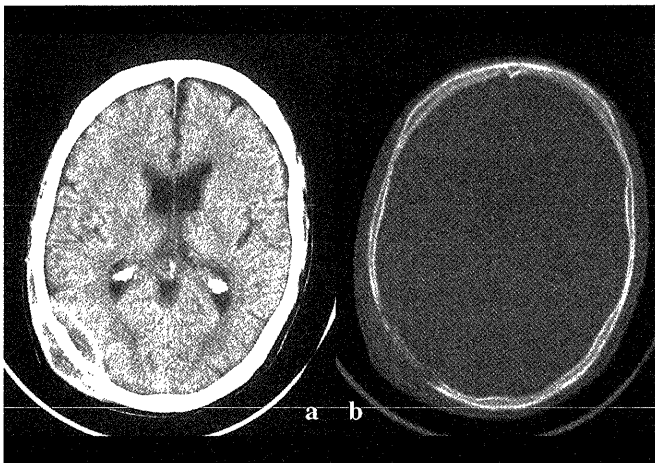


Figure 2. a: Non-enhanced transverse CT scan of the head showing a mass formation in both the inner and outer tables of the cranial bone. b: Different window setting of the same slice better showing lytic changes of the parietal bone.

Main laboratory data, on admission of September 2001 and on January 2002 when the second head CT was taken, are shown in Table 1. The erythrocyte sedimentation rate (ESR) and C-reactive protein (CRP) were high, but a white blood cell count was not remarkably high. CRP improved in four months. Anemia and hypoproteinemia observed on admission also improved. Since liver dysfunction was not observed, chemotherapy for pulmonary tuberculosis using drugs including PZA was continued as initially planned. Renal function was normal. A tuberculin skin test on admission was positive, but its erythema diameter was less than 30mm, and there was no induration. In differential white blood count, lymphocyte value was low, only 6% (absolute value: 546/ l). As bone metastasis was suspected, tumor marker carcinoembryonic antigen (CEA) was examined but it was not high.

Table 1.

	Sep. 2001	Jan. 2002	
ESR (1h)	78	100	mm
CRP	14.9	6.2	mg/l
WBC	9100	7100	/ μ l
(Nt 87 Ly 6 Mo 6 Ba 1)			
RBC	407	460	$\times 10^4$ / μ l
(Hb 10.3 Ht 31.2)		(Hb 12.9 Ht 39.1)	
TP	5.9	8.4	g/dl
Alb	2.3	4.0	g/dl
AST	52	25	IU/l
ALT	49	15	IU/l
LDH	202	165	U/l
ALP	423	418	IU/l
BUN	14	15	mg/dl
Cre	0.4	0.8	mg/dl
Tuberculin test	0 \times 0/10 \times 20 (mm)	CEA 5.2 ng/ml	

Main laboratory data which were obtained on September 2001 when he was hospitalized and on January 2002 when he received the second head CT.

Cytological diagnosis on the initial aspiration biopsy indicated the mass of class I, and there were no malignant cells in the sputum. The mass gradually enlarged afterwards, and a fluid like abscess and abundant *Cryptococcus neoformans* were observed on re-aspiration biopsy (Fig.3).

Chest radiographs and chest CT obtained on admission and at the time of biopsy are presented in Fig.4. Lung opacity with multiple cavity formations of the bilateral upper lung fields observed on admission was decreased by anti-tuberculous therapy. The middle and lower lung fields were clear. No new lesions or opacities indicating Cryptococcal pneumonia or lung tumor were observed. Bone scintigram was not performed.

Based on above findings, the patient was diagnosed as having isolated cranial bone cryptococcosis with abscess formation. He was sent to the department of neurosurgery of another hospital, and received

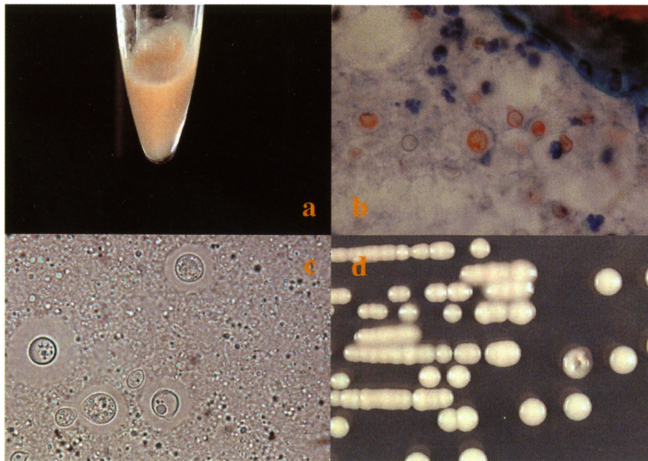


Figure 3. a: Fluid acquired by aspiration biopsy of the mass. b: Abundant *Cryptococcus neoformans* with the neutrophils and epithelioid cells. c: Indian ink smear revealing encapsulated yeast-like fungi whose capsule shell is very thick and transparent. d: Many smooth, creamy-white colonies on Sabouraud's media.

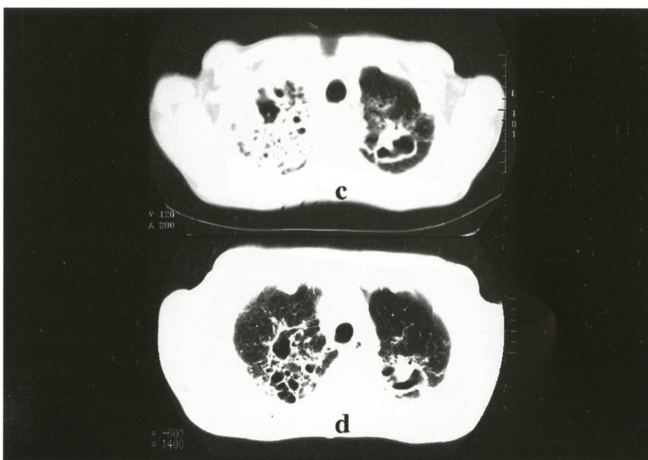
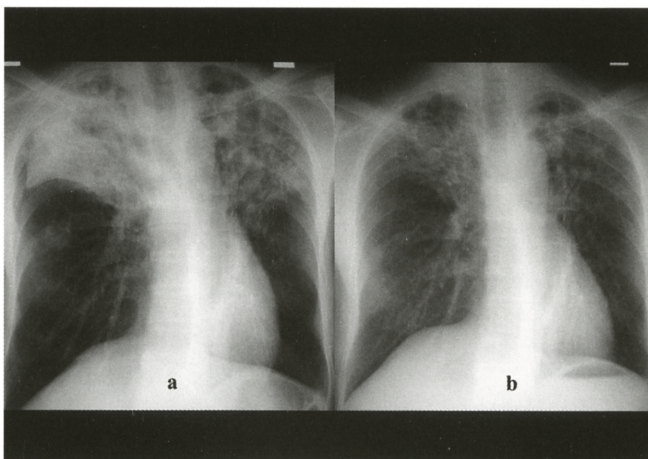


Figure 4. Chest radiographs (a, b) and plain chest CTs (c, d). On admission, lung opacities with multiple cavity formations of bilateral upper lung fields were observed (a, c). They improved after anti-tuberculous therapy for about 5 months (b, d).

drainage and irrigation of abscess and craniectomy of the right parietal bone on March 8th 2002. He was treated with 200mg of oral fluconazole afterwards, but cryptococcal antigen in serum, as of July 18th 2002 was positive (titer 1:128). When the infection disappears completely, he is to receive cranioplastic surgery.

Discussion

Pathogen of cryptococcosis is yeast like fungus, *Cryptococcus neoformans*, which is a ubiquitous fungus widely distributed and found especially in the bird droppings and in the soil. It dries and floats in the air. Human is infected by inhalation of its airborne particles. Therefore, it is considered that one of the important precautions is to remove droppings of birds such as pigeon. There is no evidence of direct infection (e.g., human to human, and animal to human). It is believed that any organ can be invaded by hematogenous spread from primary pulmonary infection. Bone cryptococcosis occurs in only 5 to 10% of the patients with disseminated disease, and the disease localized in bones without involvement of other organ is very rare.^{1, 2)}

According to Wood et al. (1996), about a half of the patients with skeletal cryptococcosis have underlying diseases that cause abnormalities of cellular immunity (e.g., lymphoma, leukemia, sarcoidosis, diabetes mellitus, cancer, SLE and TB), or have had treatment that affect cell mediated immunity (e.g., a long-term steroid therapy).^{1, 2, 3, 5)} In addition, even seemingly immunocompetent patients frequently have laboratory abnormalities of cell-mediated immunity.^{2, 6)} In our case, lymphocyte value was low and the result of tuberculin test was relatively weak, although he had advanced pulmonary tuberculosis of 10 Gaffky scale. Therefore his cell-mediated immunity must have been decreased.

The disease may involve any bone, but the vertebrae, pelvis and ribs are most frequently involved. The disease may occur in either a single site or multiple sites (1-10). Symptoms of skeletal cryptococcosis include soft tissue swelling and pain. Fever is not frequently observed (18%). ESR rises in variable ranges and white blood cell count is often normal. The cryptococcal antigen in serum has high sensitivity and specificity, but serum cryptococcal antibodies are present in only 30 to 40% of the patients. Therefore, the value of the antibody examination is limited.²⁾

Radiologically, the disease is manifested as an osteolytic lesion with overlying soft tissue mass.¹⁻⁶⁾ The lesion is usually not accompanied with sclerotic change or periosteal reaction around the lesion: a non-specific

finding. As differential diagnosis, infectious diseases, neoplasms and other benign diseases should be considered.²⁾ Infectious diseases include other mycotic and bacterial infectious diseases such as *Staphylococcus aureus*, *brucella*, *actinomyces*, *mycobacterium tuberculosis* and atypical mycobacteria. Neoplasms include primary osteogenic sarcoma, myeloma, and bone metastasis. In addition, parietal foramina, dermoid cyst, hemangioma and meningocele should also be considered as differential diagnosis. Since clinical or radiological findings of skeletal cryptococcosis are not specific, its correct diagnosis is often delayed or not made ante-mortem.²⁾

The treatment for skeletal cryptococcosis is medication using amphotericin B with or without surgical intervention.¹⁻¹⁰⁾ The dosage and duration of medication has not been clearly established yet. The oral azoles have been used for cryptococcosis, especially for cryptococcal meningitis in AIDS patients. There are some reports indicating the effectiveness of oral azoles for cryptococcal diseases not involving the central nervous system in patients without AIDS.⁸⁻¹⁰⁾ Amphotericin B causes adverse effects such as nephrotoxicity. It takes 4 to 5 hours to intravenously infuse, and long-term administration is required. Therefore, in our case, fluconazole was selected from the beginning.

In summary we reported a case of bone cryptococcosis, one of the rare manifestations of cryptococcosis, accompanied by pulmonary tuberculosis. Our patient had abnormalities of cell mediated immunity that was in

agreement with those reported in the literature. Because bone cryptococcosis is clinically and radiologically non-specific, it is important to include it in a differential diagnosis, especially in patients with bone abscess who has underlying diseases.

References

- 1) Woolfitt R, Park H-M and Greene M: Localized Cryptococcal Osteomyelitis. *Radiology* 120: 290, 1976
- 2) Wood L and Miedzinski L: Skeletal cryptococcosis: Case report and review of the literature. *CAN J INFECT DIS* 7 : 125-133, 1996
- 3) Liu P: Cryptococcal Osteomyelitis: Case report and Review. *Diagn Microbiol Infect Dis* 30: 33-35, 1998
- 4) Shaff MI, Berger JL and Green NE: Cryptococcal Osteomyelitis, Pulmonary Sarcoidosis, and Tuberculosis in a Single Patient. *Southern Medical Journal* vol. 75, no.2 February 1982
- 5) Tokunaga M, Imanaga T, Tsuda T et al : Bone cryptococcosis in a case with sarcoidosis. *Jpn J Chest Dis* 59: 784-789, 2000
- 6) Kumlin U, Elmqvist LG, Granlund M, Olsen B and Taernvik A: CD4 Lymphopenia in a Patient with Cryptococcal Osteomyelitis. *Scand J Infect Dis* 29: 205-206, 1997
- 7) Bryan C : Vertebral Osteomyelitis due to *Cryptococcus neoformans* Case Report. *The Journal of Bone and Joint Surgery* vol 59-A: 275-276, 1977
- 8) Lee F, Kar PM and Aronoff GR: Treatment of Cryptococcal Arthritis with Fluconazole Monotherapy. *KMA Journal* 96: 449-450, 1998
- 9) Singh N, Gayowski T and Marino IR: Successful treatment of disseminated cryptococcosis in a liver transplant recipient with fluconazole and flucytosine, an all oral regimen. *Transpl Int* 11: 63-65 1998
- 10) Cook PP: Successful Treatment of Cryptococcal Osteomyelitis and Paraspinal Abscess with Fluconazole and Flucytosine. *Southern Medical Journal* 94: 936-938, 2001