

# Right Middle Lobe Atelectasis: Chest Radiographic and CT Appearances Correlating with the Clinical Features

Atsushi MIYAZAKI<sup>1,2)</sup>, Kazuto ASHIZAWA<sup>2)</sup>, Masakazu MORI<sup>1)</sup>, Mayumi OHTSUBO<sup>1)</sup>

1) Department of Radiology, Japanese Red Cross Nagasaki Atomic Bomb Hospital

2) Department of Radiology and Radiation Biology, Nagasaki University Graduate School of Biomedical Sciences

**Purpose:** To evaluate chest radiographic and CT findings of right middle lobe (RML) atelectasis correlating with the clinical features.

**Materials and Methods:** We reviewed 47 patients with RML atelectasis and classified their chest radiographic findings into four types (Type 1-4) based on the shape of the opacity. The degree of RML atelectasis was classified into three types according to CT findings, namely severe (>90%), moderate (50-90%), and mild (10-50%). Then we correlated them with chest radiographic types and patient's symptoms.

**Results:** In severe atelectasis (n=10), no definite abnormalities were detected on chest radiographs (Type 1). In moderate atelectasis (n=24), 14 cases (58%) showed triangular opacity (Type 2) and nine cases (38%) showed band-like opacity (Type 3) along the right cardiac border. In mild atelectasis (n=13), 11 cases (85%) showed vague opacity at the right lower lung field (Type 4). In severe atelectasis, only one case (10%) had symptoms. In contrast, 14 cases (58%) in moderate atelectasis and six cases (46%) in mild atelectasis had symptoms.

**Conclusion:** Our results indicate that RML atelectasis has a very wide spectrum of imaging finding of chest radiograph and CT, and patient's symptoms are related to the degree of atelectasis.

ACTA MEDICA NAGASAKIENSIA 48 : 159–166, 2003

**Key Words:** middle lobe atelectasis, chest radiograph, chest CT

## Introduction

Right middle lobe (RML) atelectasis is one form of the lobar collapses, and has been well known both to clinicians and radiologists. It has often been called "right middle lobe syndrome". At our daily clinical

works we have often noticed that RML atelectasis varies greatly from case to case in its radiographic appearances. Some cases can only be diagnosed by CT. Clinical presentations of RML atelectasis also have many variations. There have been many reports describing various aspects of both clinical and imaging features of RML atelectasis. However, there has been no study correlating the imaging findings and clinical features. The purpose of this report is to describe the results of our investigation of radiographic and CT appearances of RML atelectasis correlating with the clinical features.

## Materials and Methods

Eighty hundred seventy three cases were examined on chest CT scan in our hospital between 1996 and 2000. According to our CT records, 182 patients had RML atelectasis, and both chest radiographs and CT films were available in 108 patients out of them. Some cases, with concomitant severe involvement by other disease or postoperative change were excluded. 56 cases showing only slight volume loss (less than 10%) on CT were also excluded. The remaining 47 patients were included in this study. Fourteen were men and 33 were women. The age ranged from 14 to 87 years with a mean age of 64 years. Clinical information of the patients was obtained from their medical records. The bronchi were patent in all of the 47 cases. Lateral chest radiographs, available in 18 patients, were not analyzed. Parameters for PA chest radiograph were 105 KVp and 4-10 mAs. CT with helical scanning was performed at 120 KVp and 100 mAs, 5-mm collimation, pitch 1.4, and 7-mm reconstruction intervals. All CT scans were obtained on a X-Vigor (Toshiba Medical Systems, Tokyo, Japan). All scans were obtained at end-inspiratory lung volumes and photographed at window levels and widths appropriate for lung parenchyma (level, -700 HU; width, 1800 HU) and mediastinum (level, 25 HU; width, 430 HU).

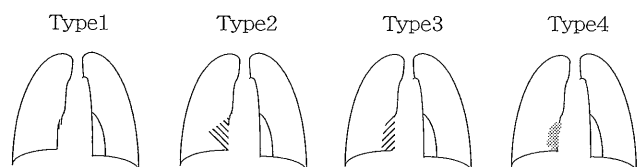
**Address Correspondence:** Atsushi Miyazaki, M.D.

Department of Radiology, Japanese Red Cross Nagasaki Atomic Bomb Hospital, 3-15 Mori, Nagasaki, 852-8511, Japan  
TEL: +81-95- 847-1511, FAX: +81-95- 847-8036  
E-mail: dive0318@hotmail.com

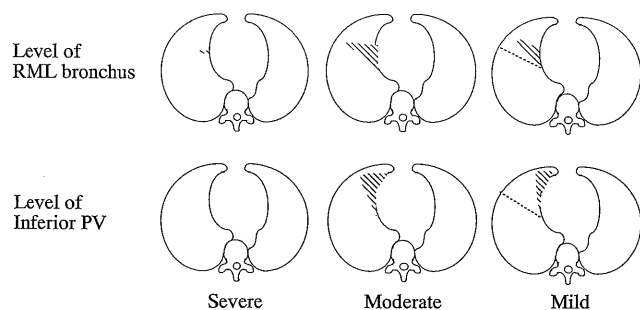
Two experienced radiologists interpreted chest radiographs and CT in 47 patients.

Posteroanterior (PA) chest radiographs of RML atelectasis were classified into four types (Fig. 1). In Type 1, no abnormalities were detected or only slight obliteration of the right cardiac border was seen. In Type 2, a triangular opacity was seen with its base on the right cardiac border. In Type 3, a band-like opacity was seen along the right cardiac border. In Type 4, there was a small vague opacity near the right cardiac border. The degree of volume loss of RML was classified into three types according to CT findings; namely, severe, moderate and mild. Volume loss of 90 percent or more was defined as severe, between 50 and 90 percent as moderate, and between 10 and 50 percent as mild. The judgment was made visually, taking the appearances of whole lung fields into consideration. Figure 2 shows a schematic drawing of CT classification of RML atelectasis, at the levels of the RML bronchial bifurcation and the right inferior pulmonary vein.

Correlation was made between the degree of atelectasis and chest radiographic classification. Correlation was also made between the degree of atelectasis and the symptoms of patients.



**Figure 1.** Classification of chest radiographic appearances. The visualization of minor fissure and right cardiac border was not taken into consideration in this classification.



**Figure 2.** Classification of chest CT appearances. RML: right middle lobe PV: pulmonary vein

### Results

Table 1 shows correlation between the degree of volume loss and chest radiographic classification. All ten cases of severe atelectasis were classified as Type 1 showing either no abnormality or only slight obliteration of the right cardiac border on PA chest radiograph. The lung fields were clear in all ten cases. Even on CT, in severe RML atelectasis, a small triangular opacity with mild bronchiectasis was the sole finding that could be easily overlooked (Fig. 3). In moderate atelectasis (n=24), 14 cases (58%) showed a triangular opacity as Type 2 (Fig. 4) and nine cases (38%) showed a band like opacity as Type 3 (Fig. 5) on PA chest radiograph. One case (4%) of moderate atelectasis showed a vague opacity near the right cardiac border as Type 4 (Fig. 6). In mild atelectasis (n=13), 11 cases (85%) showed a localized vague opacity near the right cardiac border as type 4 (Fig. 7). In the remaining two cases, triangular opacity was revealed along the right cardiac border as Type 2 on PA chest radiograph.

Table 2 shows the correlation between the degree of

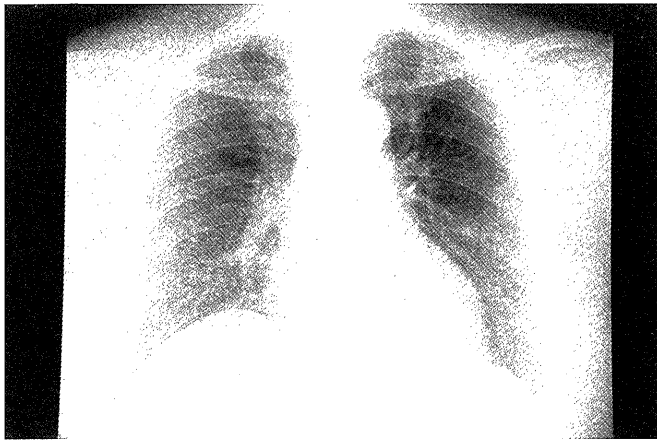**Table 1.** Correlation between the degree of atelectasis and chest radiographic classification

Degree of atelectasis (on CT)	Chest radiographic classification			
	Type 1	Type 2	Type 3	Type 4
Severe	10			
Moderate		14	9	1
Mild		2		11
Total	10	16	9	12

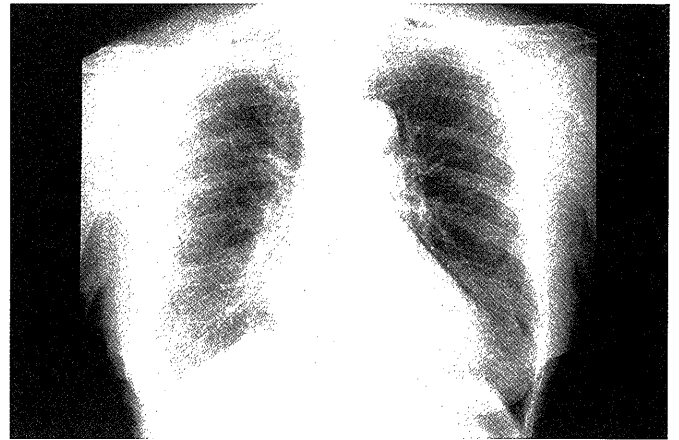
**Table 2.** Correlation between the degree of atelectasis and the presence of symptoms

Degree of atelectasis (on CT)	Symptoms *	
	present	absent
Severe	1	9
Moderate	14	10
Mild	6	7
Total	21	26

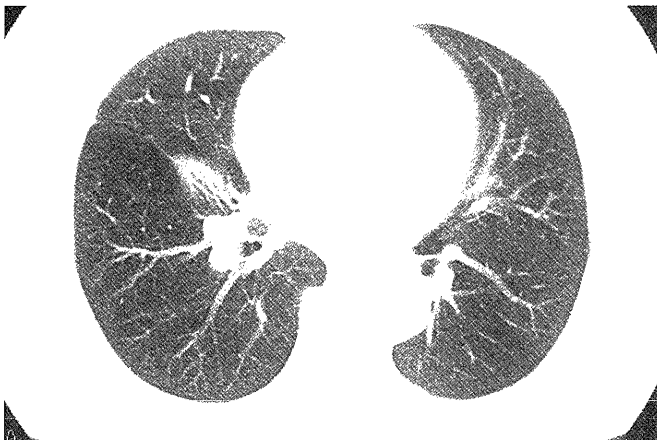\* Symptoms include cough, sputum, bloody sputum and chest pain.



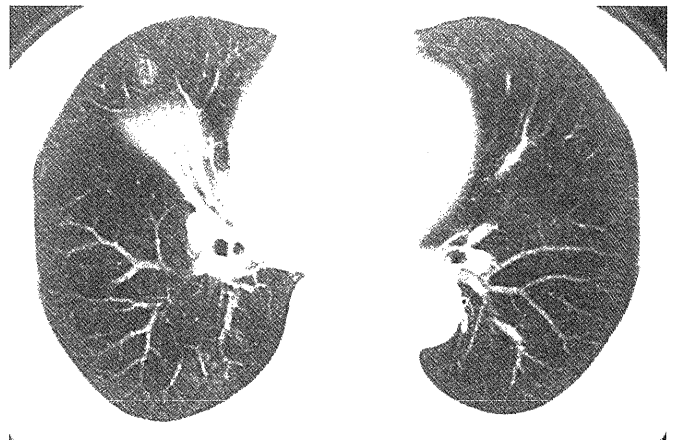**Figure 3a.** Severe RML atelectasis in a 57-year-old woman with no symptoms (medical checkup case). The right cardiac border is clear and no abnormalities can be pointed out on PA chest radiograph. (Type 1)



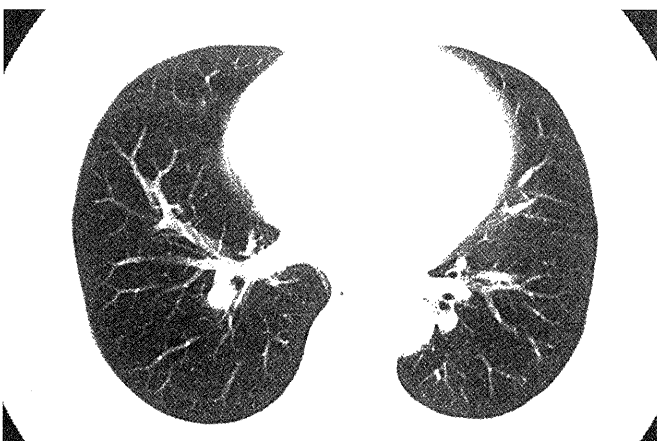**Figure 4a.** A case of moderate RML atelectasis. The patient is an 87-year-old woman with cough and sputum. The right cardiac border is obliterated by a triangular opacity on PA chest radiograph. (Type 2)



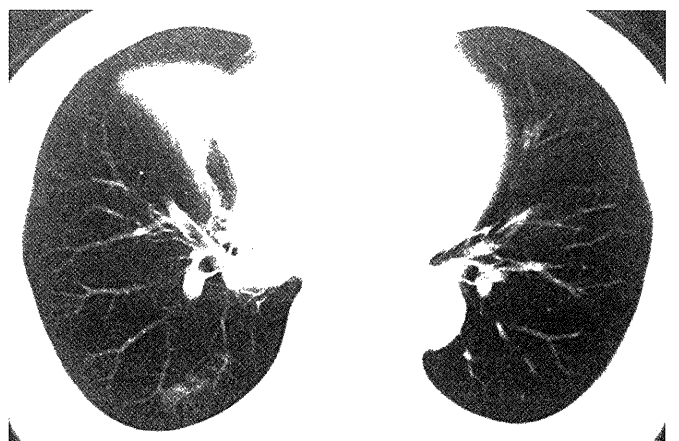
**Figure 3b.** Atelectasis is so severe that the shrunken RML can only be seen at the level of proximal bronchi of RML on CT.



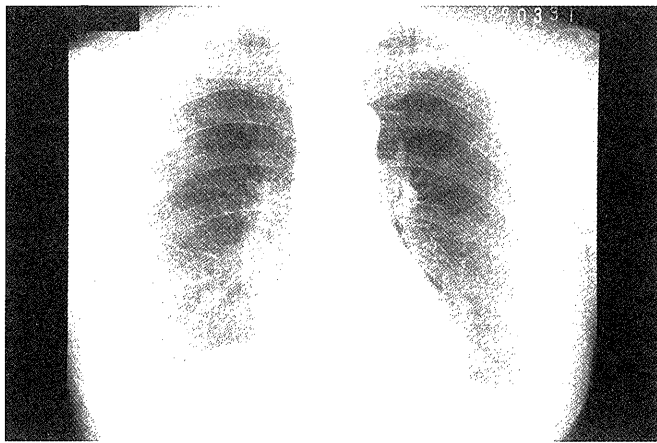
**Figure 4b.** A broad triangular opacity with bronchiectasis is seen at the level of RML bronchus on CT.



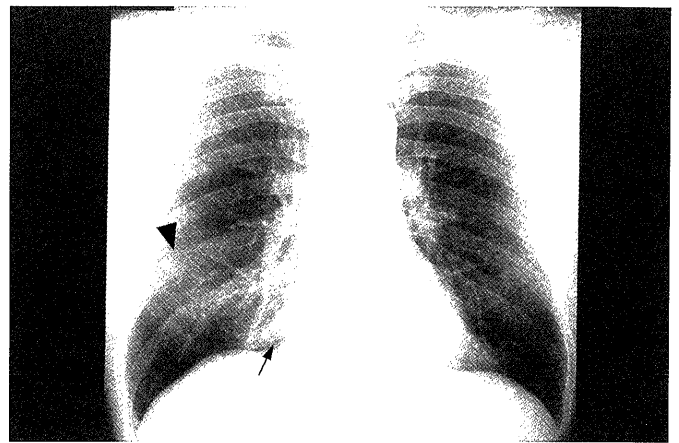
**Figure 3c.** RML atelectasis is not shown at the level of inferior PV, 14 mm caudal to 3b.



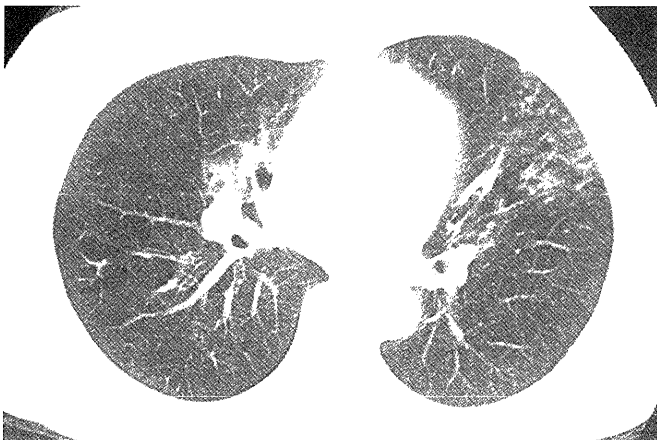**Figure 4c.** 14 mm caudal to 4b. A broad triangular opacity contacting with the right cardiac border is observed.



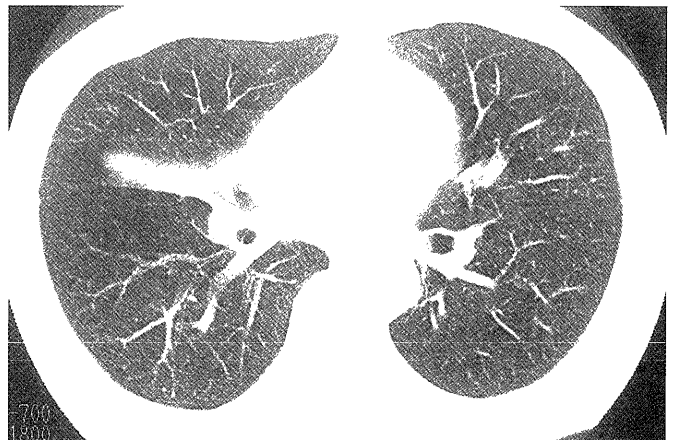**Figure 5a.** A case of moderate RML atelectasis. The patient is a 56-year-old woman with cough and hemoptum. A band-like opacity is observed along the right cardiac border on PA chest radiograph. (Type 3)



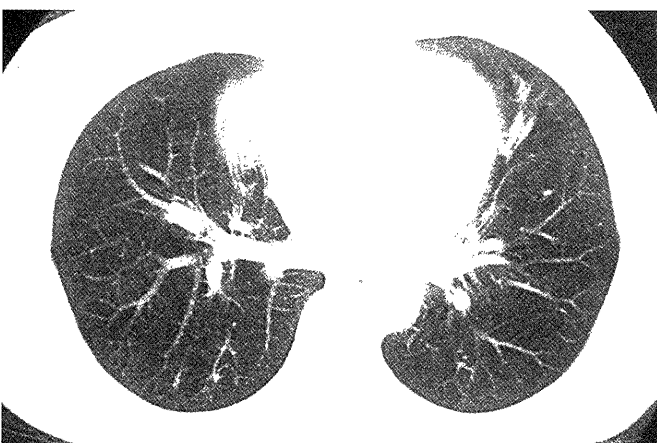**Figure 6a.** A case of moderate RML atelectasis. The patient is a 49-year-old man with no symptom in medical checkup. On PA chest radiograph a vague opacity (arrow) is seen near the right cardiac border, and cardiac border is totally obliterated. The minor fissure shows slight downward displacement (arrow head). (Type 4)



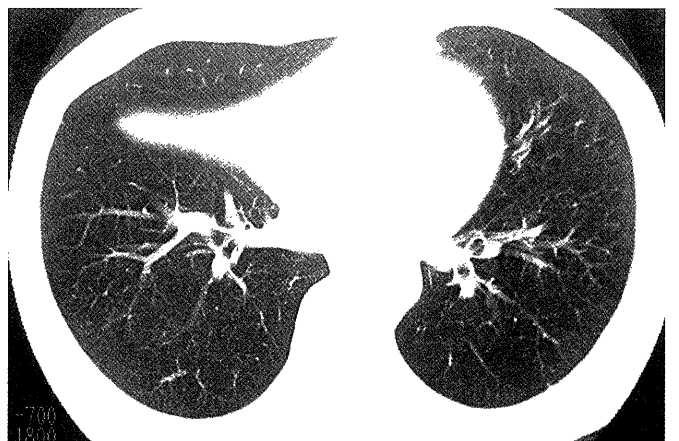
**Figure 5b.** An irregular opacity with bronchiectasis is seen at the level of RML bronchial bifurcation on CT. Centrilobular small nodules are observed in the lingula of the left upper lobe.



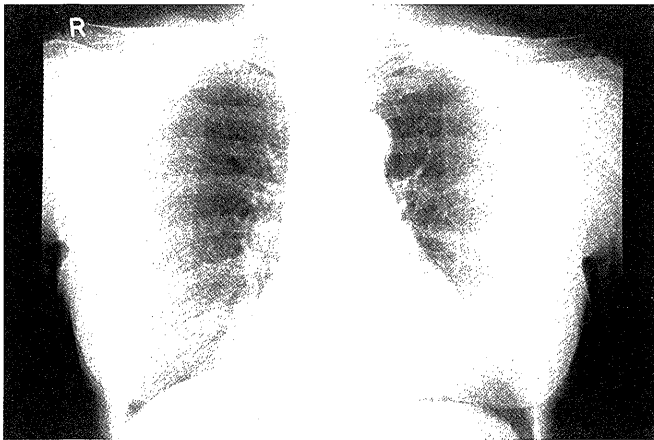
**Figure 6b.** A broad transverse opacity extending laterally is seen between the right upper and lower lobes at the level of RML bronchus. A small opacity is noted in the lingula.



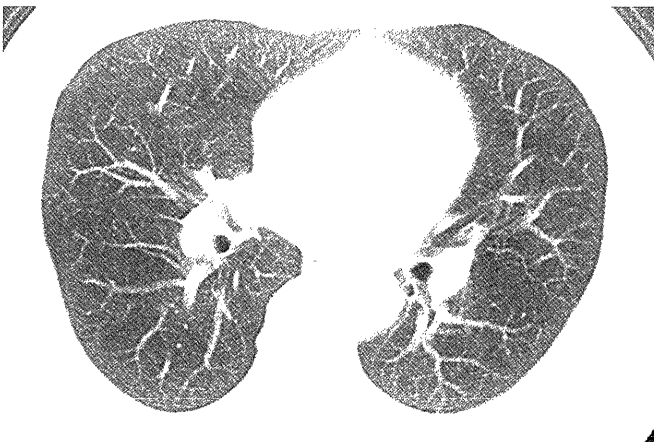
**Figure 5c.** An oval opacity contacting with the right cardiac border with bronchiectasis is seen at the level of inferior PV in RML. Liner opacities are observed in the lingula, 14 mm caudal to 5b.



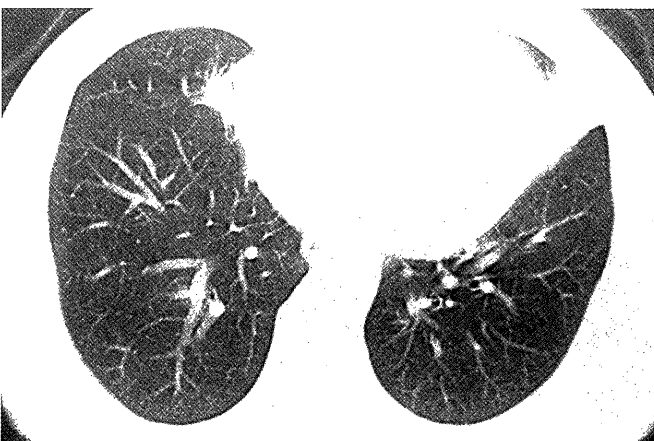
**Figure 6c.** A broad triangular opacity having wide contact with the right cardiac border is noted at the level of inferior PV on CT, 21 mm caudal to 6b.



**Figure 7a.** A case of mild RML atelectasis. The patient is a 59-year-old woman with no symptom. On PA chest radiograph, a small vague opacity near the right cardiac border is noted. (Type 4)



**Figure 7b.** Aeration is maintained at the level of RML bronchial bifurcation on CT.



**Figure 7c.** A small opacity with bronchiectasis is observed along the right cardiac border at the level 42 mm caudal to 7b. Similar opacity is seen along the left cardiac border in the inferior portion of the lingula.

atelectasis and the presence of symptoms. In severe atelectasis, 1 out of 10 cases (10%) had symptoms. In moderate atelectasis, 14 out of 24 cases (58%) had symptoms. In mild atelectasis, 6 out of 13 cases (46%) had symptoms. The presenting symptoms included cough, sputum, bloody sputum and chest pain. Some patients had more than one symptom, and the severity of the symptoms varied from case to case. Ten out of 47 cases underwent bronchoscopy and 2 cases were diagnosed as having mycobacterial infection.

## Discussion

Graham and his associates coined the term "middle lobe syndrome" and reported 12 cases in which there was compression of the RML bronchus secondary to enlarged lymph nodes. Pathologically, the lobes were atelectatic with varying degrees of interstitial fibrotic changes and bronchiectasis. Their patients were seen with hemoptysis, chronic cough, and recurrent episodes of pulmonary infection<sup>1)</sup>. Since then there have been many reports describing various aspects of this disease entity including its etiology, pathophysiology as well as symptoms. The definition and usage of the term "middle lobe syndrome" has been debated<sup>2-4)</sup>. A term "atelectasis syndrome" has been proposed by Ring-Mrozik<sup>5)</sup>, but we consider the simple term "right middle lobe atelectasis" is the most appropriate, to include all the cases in which there is volume loss of the RML, minimal to marked, regardless of the cause and clinical presentation.

Many theories have been proposed regarding the reason why atelectasis easily occurs in the RML in comparison with other lobes. RML bronchus is surrounded by the lymph nodes that drain the middle as well as the lower lobes, and compression of the RML bronchus is often a consequence of chronic infection and lymphadenitis<sup>6)</sup>. Relatively long length of the RML bronchus before it divides into segmental bronchi<sup>7)</sup> and relatively narrow caliber of the RML bronchus as compared to other lobes<sup>8)</sup> are also described. Moreover, the RML bronchus arises from the intermediate bronchus at almost right angle, causing poor drainage<sup>9)</sup>. All of these factors may predispose the RML bronchus to its obstruction.

The other important factor is a lack of collateral ventilation. Bradham proposed that complete fissures surrounding the RML interfere with the rapid resolution of an inflammatory process<sup>8)</sup>. Culiner hypothesized that an inflammatory process first produces secretions that obstruct the airways in the RML and that absent or ineffective collateral ventilation results

in alveolar collapse of the lung parenchyma distal to the obstructed airways<sup>3)</sup>. Inners proposed that a high resistance and a long-time constant relative to the upper lobes characterize collateral ventilation of the RML, because ratio of pleural surface to nonpleural surface is greater in the RML than in the upper lobes<sup>10)</sup>. So they suggested that ineffective collateral ventilation is a major factor in the pathophysiology of the RML atelectasis<sup>10)</sup>.

Both chest radiographic and CT findings of RML atelectasis have been described. With various degree of volume loss, the imaging findings of RML atelectasis vary greatly. The diagnosis of RML atelectasis is one of the most difficult tasks on PA chest radiographs. The difficulty in detecting atelectasis in this projection is related to the obliquity of the atelectatic lobe to the superoinferior plane and the thickness of the collapsed lobe itself<sup>11)</sup>. There are some articles that have correlated the chest radiographic findings with the CT findings<sup>11-15)</sup>, but there is no article that has correlated the degree of volume loss with clinical significance of RML atelectasis.

We have demonstrated in this study that in severe atelectasis, no abnormalities are detected or only slight obliteration of the right cardiac border is seen on PA chest radiograph. Because the shrunken middle lobe is very small, there is no discernible increase in opacity. Moreover, because the right upper and/or lower lobes show compensatory expansion, the greater part of the right cardiac border becomes clearly visible on PA chest radiograph and CT in severe atelectasis of the RML. Felson pointed out that obliteration of the right cardiac border is a useful radiographic finding and can be the clue to the diagnosis of RML collapse<sup>16)</sup>. However there are cases of RML collapse in which the right cardiac border is clearly identified on PA chest radiograph<sup>14)</sup>. In moderate atelectasis, most cases revealed triangular or band-like opacity on PA chest radiograph. These cases revealed broad triangular or mass like opacity on CT. In one case of moderate atelectasis, PA chest radiograph revealed vague opacity near the right cardiac border and downward displacement of the minor fissure. CT showed a thin tenting that was directed from the hilum to the periphery at all levels. We speculate that it was due to pleural adhesion at the lateral side. In mild atelectasis, many cases showed discernible increase in density near the right cardiac border on PA chest radiograph. On CT of these cases, the volume loss of the medial segment of RML was severer than that of the lateral segment. According to Inners's report, ineffective ventilation of the medial segment is a factor of this condition<sup>10)</sup>. Two cases of mild

atelectasis showed a triangular opacity as Type 2 on PA chest radiograph. These cases showed moderate medial segmental collapse and maintained aeration of the lateral segment on CT.

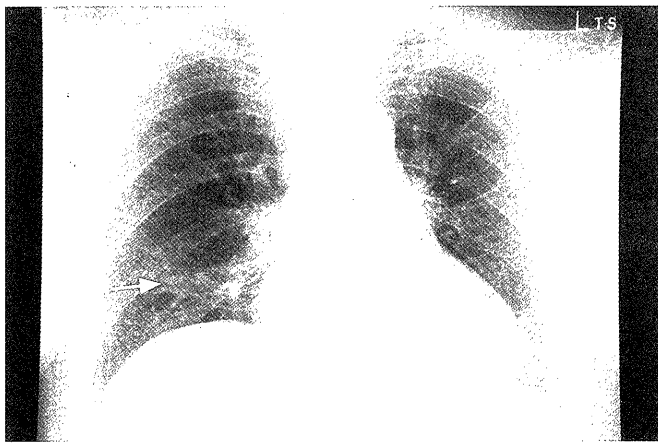The symptoms and signs in patients with the RML atelectasis included cough, hemoptysis, dyspnea, chest pain, audible wheezing, and fever and chills. These symptoms, reflecting the presence of pneumonia, were often intermittent and recurrent despite antibiotic therapy. In some cases, symptoms were absent and the middle lobe atelectasis was discovered on routine chest radiograph<sup>13)</sup>. Albo and Grimes reported 30 patients with "right middle lobe syndrome" who stopped smoking for nine months or longer after the diagnosis. Complete clearing was seen in 25 of the 30 patients. Symptoms disappeared in the remaining five patients, although their radiographs did not change<sup>17)</sup>.

This is the first report describing the correlation between the degree of RML atelectasis and patient's symptom. In our study, in moderate and mild atelectasis, approximately half of the patients presented respiratory symptoms. On the other hand, most patients with severe RML atelectasis did not have any symptom. Although the diagnosis of severe RML atelectasis is often very difficult on routine PA chest radiograph, missing severe RML atelectasis may not result in serious clinical problems.

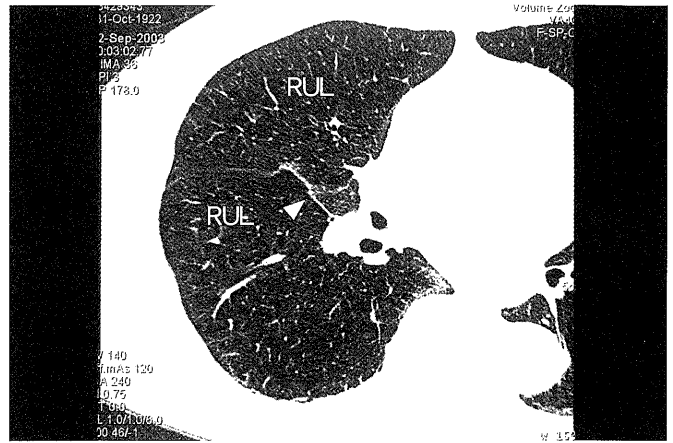
However we have experienced an interesting case of severe RML atelectasis with adenocarcinoma in pre-surgery examinations (Fig. 8). On PA chest radiograph and CT, there are two nodules, and they appear to be located in RML. However, RML shows complete collapse as indicated by arrows. Therefore the two nodules, both representing adenocarcinoma, are located in RUL, not in RML. In this way, in severe RML atelectasis there is a possibility of misdiagnose of location of the disease, so we should be careful not to overlook this pathologic condition.

During this research work, the authors were impressed by the wide spectrum of imaging findings of RML atelectasis. Classification of RML atelectasis was not easy. We believe our classification was successful, simplifying RML atelectasis into four types based on PA chest radiographic appearances and into three degrees based on CT findings.

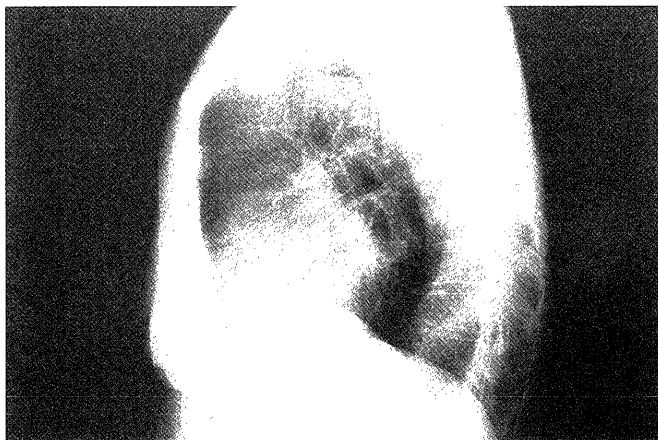There are a number of limitations in this study. Firstly, correlation between the imaging findings and laboratory data was not conducted because of the small total number of cases of RML atelectasis. Secondly, lateral chest radiographs were not analyzed because of their small number. However we believe that analyzing PA chest radiographs alone is worthwhile, particularly because lateral chest radiographs



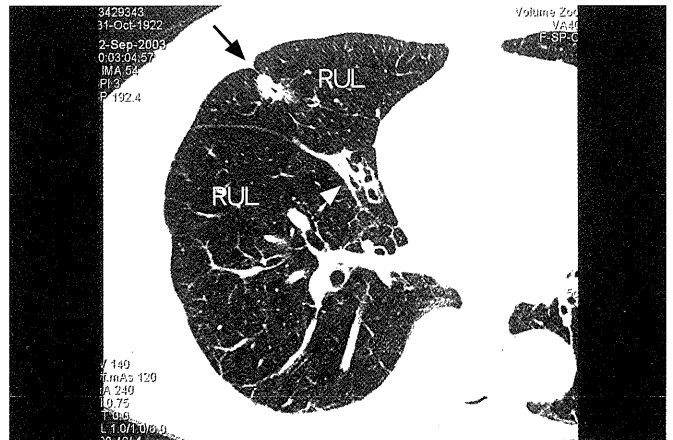
**Figure 8a.** The patient is an 80-year-old woman. There is no obliteration of right cardiac border. There is a nodule in the right lower lung field.



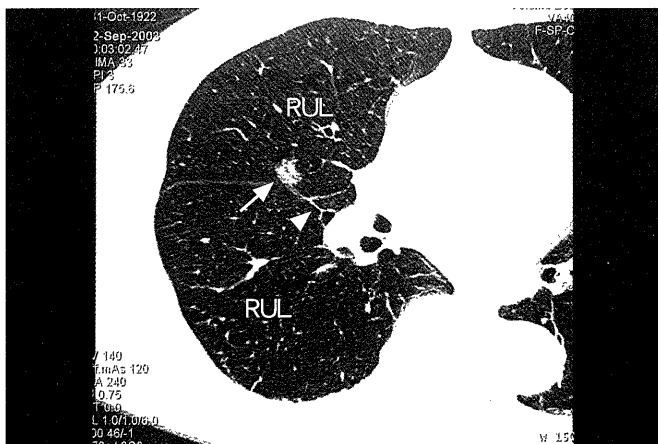
**Figure 8c-2.**



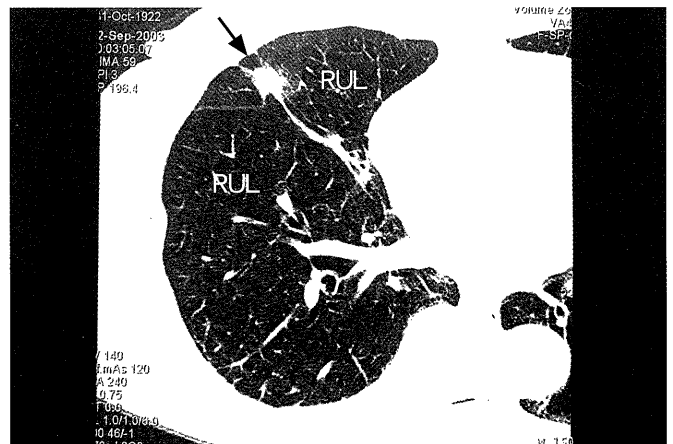
**Figure 8b.** On lateral chest radiograph, the same nodule is located in anteroinferior portion of the lung.



**Figure 8c-3.**



**Figure 8c-1.** On CT, there are two nodules (arrow), and they appear to be located in the RML. In fact, RML shows complete collapse as indicated by arrows heads. The two nodules, both representing adenocarcinoma are located in RUL, not in RML.



**Figure 8c-4.**

are seldom obtained in actual medical practice these days. Finally, no case of RML atelectasis associated with tumor was included. This should be investigated separately.

In conclusion, we have shown in this article, RML atelectasis has a very wide spectrum in terms of imaging findings of chest radiograph and CT, and patients' symptoms are related to the degree of atelectasis.

## References

1. Graham EA, Burford TH, Mayer JH: Middle lobe syndrome. *Post Grad Med* 4: 29-34, 1948
2. Rosenman, E: "Acute Transient Middle Lobe Disease". *Dis Chest* 27: 80-87, 1955
3. Culiner MM: The right middle lobe syndrome: a non-obstructive complex. *Dis Chest* 50: 57-66, 1966
4. Bross W, Kaniowski T, Rogalski R, Kozuszek W: So-called middle lobe syndrome: diagnosis and treatment results. *Med Klin* 65: 783-89, 1970
5. Ring-Mrozik E, Hecker WC, Nerlich A, Krandick G: Clinical findings in middle lobe syndrome and other process of pulmonary shrinkage in children (atelectasis syndrome). *Eur J Pediatr Surg* 1: 266-272, 1991
6. Brock RC, Cann RJ, Dickinson JR: Tuberculous mediastinal lymphadenitis in childhood; Secondary effects on the lungs. *Guy's Hosp Rep* 87: 295-317, 1937
7. Goldman HI, Becklake MR: Respiratory function tests. Normal values at median altitudes and the prediction of normal results. *Respir Function and Altitude* 79: 457-467, 1959
8. Bradham RR, Sealy WC, Young, Jr. WG: Chronic middle lobe infection. Factors responsible for its development. *Ann Thorac Surg* 2: 612-616, 1966
9. Paulson DL, Shaw RR: Chronic atelectasis and pneumonitis of the middle lobe. *J Thorac Surg* 18: 747-760, 1949
10. Inners CR, Terry PB, Traystman RJ, Menkes HA: Collateral ventilation and the middle lobe syndrome. *Am Rev Respir Dis* 118: 305-452, 1978
11. Fraser RS, Muller NL, Colman N, Pare PD: Radiologic signs of chest disease. In *Diagnosis of diseases of the chest 4th eds.* (Fraser RS, et al. eds.; Saunders, Philadelphia) pp 549-551, 1999
12. Rosenbloom SA, Ravin CE, Putman CE, et al: Peripheral Middle Lobe Syndrome. *Radiology* 149: 17-21, 1983
13. Gudmundsson G, Gross TJ: Middle lobe syndrome. *Am Fam Physician* 53: 2547-2550, 1996
14. Groskin SA. Atelectasis. In *Heitzman's the Lung Radiologic-Pathologic Correlations.* (Groskin SA eds.; Mosby, St. Louis) pp. 548-560, 1993
15. K Ashizawa, K Hayashi, N Aso, K Minami: Lobar atelectasis: diagnostic pitfalls on chest radiography. *Br J Radiol* 74: 89-97, 2001
16. Felson B: The Lobes. In *Chest roentgenology* (Felson B eds.; Saunders, Philadelphia) pp. 107-117, 1973
17. Albo RJ, Grimes OF: The right middle lobe syndrome: A clinical study. *Dis Chest* 50: 509-518, 1966