

A CASE OF REPLACEMENT OF THE ABDOMINAL AORTIC ANEURYSM

Jōji TASAKI, Shigetane KIKITSU, Masao TOMITA,
Tsuneo IKENAGA, Hideaki TASAKI, Toshiyasu
KUGIMIYA, Masumi IFUKU and Yasunori KOGA*

*First Department of Surgery Nagasaki
University School of Medicine, Nagasaki, Japan*

Received for publication September 1, 1962

This is a report on a case of successful replacement of abdominal aortic aneurysm with a crimped Dacron graft. The prognosis of such a disease is said to be very poor, and it is generally accepted that a surgical replacement of the aneurysm is the only reliable treatment at present. Therefore the importance of early diagnosis and surgery must be stressed.

Recent advance in surgery has made many fatal vascular diseases curable. On the other hand, with increasing number of aged persons, incidence of senile vascular diseases is increasing rapidly. Treatment of the aneurysm of abdominal aorta has become important for this reason. The case reported here illustrates a successful replacement of the aneurysm of abdominal aorta with a crimped Dacron graft.

CASE REPORT

H. M., a 61-year-old man, was referred to our clinic on March 12, 1961. He said he had gonorrhoea at the age of 20 but denied syphilis. He had been known to have hypertension since 8 years ago. On March 1960, local medical doctor told him of a pulsatile mass in the abdomen. But he had been quite well and did not notice a marked enlargement of the mass, so he gave it little thought until admission.

On admission this thin old man appeared fairly healthy. The blood pressure was 162/80 mm. Hg.. The chest was symmetrical and the heart sounds were clear. The abdomen was slightly concave and soft to the touch. There was a pulsatile, firm tumor about the size of an egg in the umbilical region. But there was no tenderness in the abdomen. Pulses in the lower extremities were clearly palpable.

A roentgenogram of the chest demonstrated an enlargement of the

* 田崎丞治・喜々津重胤・富田正雄・池永経雄・田崎英秋・釘宮敏定・伊福真澄・古賀保範

aortic arch (Fig. 2). The electrocardiogram showed a slight left ventricular hypertrophy (Fig. 3). Plain film of the abdomen disclosed a calcification in the mid-abdomen and it was considered to represent a rim of calcified aneurysm (Fig. 4). Intravenous aortography revealed an elongation and flexion of the abdominal aorta to the right, below the renal arteries, but an outline of the aneurysm was not clear because of a dilution of contrast media.

Examination of the blood showed 75 per cent hemoglobin, 4,000,000 red blood cells and 6,800 white blood cells. The bleeding time was 2 minutes, and the coagulation time (Sahli-Fonio) was 6 minutes 30 seconds (beginning) and 12 minutes (completion). The serologic test for syphilis was negative. The liver and renal function tests, examination of urine and stools revealed no positive findings.

The patient was discharged for a time after completion of the examinations, and was readmitted on June 19, 1961, for an operation.

On July 4, laparotomy was performed under GOE anesthesia, using general hypothermia (around 32°C of the esophageal temperature) with ice bags. The abdominal aorta was curved to the right, and an aneurysm was found to begin about 5 cm. below the renal arteries and extend to either side of common iliac arteries (Fig. 1 a). The abdominal aorta and common iliac arteries were exposed, and were encircled with umbilical tapes at the proximal and distal portions to the aneurysm. Before

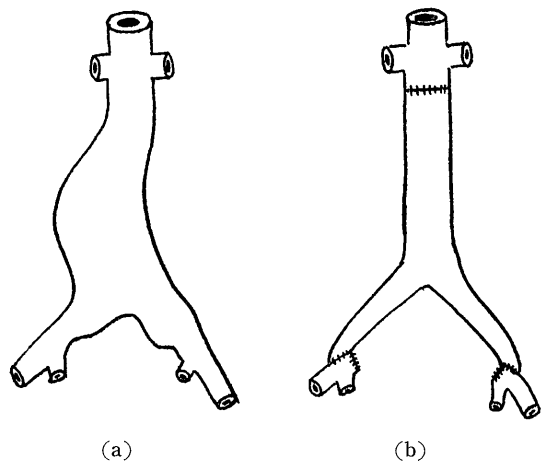


Fig. 1 Schema of the Operation

occluding the aorta, 20 mg. of heparin was injected into the aneurysm, and occlusion was made with the umbilical tapes. Then the aneurysm was excised between the tapes, and a crimped Dacron bifurcation graft, which was pre-clotted to prevent bloodloss through the mesh of the graft, was replaced by end-to-end and end-to-side anastomoses (Fig. 1 b). Pedal pulses returned immediately and the blood pressure was 115/85 mm. Hg. at the end of the operation.

The aneurysm was about the size of a goose egg, and when it was opened almost entire internal surface was found to be marked atheromatous degeneration and calcification with incomplete lacerations in places (Fig. 5).

The postoperative course was uneventful until three weeks after the operation. On the twenty-first postoperative day he had a fever ranging between 38° and 39°C and continued about three days. The

episode recurred several times in the following three months and accompanied with pain in the right knee joint, but no abdominal symptoms were noticed. These symptoms were effectively treated by salicyltherapy and chemotherapeutics. When he was discharged on November 8, 1961, he had no fever and in normal health.

COMMENT

The incidence of the aneurysm of abdominal aorta, mainly caused by arteriosclerosis has been increasing recently¹²⁾. It makes good contrast with the decreasing incidence of thoracic aneurysm which is mostly due to syphilis⁷⁾. The abdominal aortic aneurysms are most common in men about 60 year old^{12) 7) 14) 1)}.

BARRAT-BOYES,¹⁾ and ROB & WILLIAMS¹²⁾ describe in their recent reports clinical features of the aneurysm of abdominal aorta observed in many clinical cases (51 cases by BARRAT-BOYES and 100 cases by ROB & WILLIAMS). They state that most cases were asymptomatic in the early stage, but with the growth of the aneurysm majority of them suffered from abdominal and/or back pain. Severe pain in the back often preceded leaking or rupture of the aneurysm and suggested need of emergency operation. Some of the patients had pain similar to that of renal or urethric lesion. In more than half of the patients who consults doctors, tumor, mostly pulsatile, can be felt in the abdomen, but some of them it cannot be felt because of paralytic ileus, hypotension, hematoma or some other overlying abdominal rigidity. Leaking or rupture of the aneurysm is almost always accompanied by severe pain and various degrees of shock¹⁴⁾.

The prognosis in these patients is unfavorable. EDWARDS⁵⁾* noted that the average survival rate in the cases with asymptomatic abdominal aneurysms is about three years and most of them died within seven years. When symptoms of back pain or abdominal discomfort appear, a life expectancy is not more than 6 months. The diagnosis is established by palpating the pulsatile tumor in the abdomen. If calcification in the wall of aneurysm is detected by plain film examination of the abdomen, such as in our case, it provides the most reliable diagnostic base. Whether the upper extent of the aneurysm reaches the renal arteries is important in determining an operability. This can usually be established by an aortography. But practically all the aneurysms of the abdominal aorta begin below the renal arteries, so preliminary arteriographic examination is said to be not always necessary^{7) 14)}. ROB & WILLIAMS¹²⁾ stressed that all the abdominal aneurysm with its upper margin below the xiphoid process of the sternum arose below the renal arteries.

Many palliative measures had been taken for treatment of the aortic aneurysms⁷⁾ but none of them were effective until recently. In 1952,

the first successful case of surgical replacement of abdominal aortic aneurysm was reported by Dubost,⁴⁾ and in 1953 by COOLEY and DEBAKEY³⁾. In the early stage of clinical application of arterial grafts, preserved homo- and heterografts were mainly used^{3) 4) 6) 8) 10) 11)}. But in addition to the difficulty of obtaining suitable grafts, it has become clear that there have been high incidence of graft degeneration in three or four years^{5) 9) 15) 16)}. Recently most of the surgeons use synthetic grafts^{9) 15) 16) 17)}. SCALES pointed out the following characteristics as a qualification of an ideal synthetic graft,¹³⁾ that is;

The implant must

1. Not be physically modified by tissue fluid
2. Be chemically inert
3. Not excite an inflammatory or foreign body cell response in the tissues
4. Be non carcinogenic
5. Not produce an allergy or hyper-sensitivity
6. Be capable of standing up to mechanical strains imposed upon it
7. Be capable of being fabricated in the form reasonable ease at a relatively low cost
8. Be capable of being sterilized

Recently, Teflon and Dacron crimped grafts are considered as good, which are now readily available in Japan. Japanese-made Decron crimped graft was used in our case (made by Nakao Filter Laboratory).

It is generally accepted that a prognosis of nontreated aortic aneurysm is very poor^{1) 5) 12)}, and a surgical replacement has been established as a only reliable treatment. Therefore the most successful management of abdominal aortic aneurysms is dependent upon early diagnosis and surgery.

REFERENCES

- 1) BARRATT-BOYES, B. G. : *Lancet*, II. : 716-720, 1957.
- 2) BLAKEMORE, A. H. : *Ann. Surg.* 137 ; 5, 760-777, 1953.
- 3) COOLEY, D. A. and DEBAKEY, M. E. : *Surg. Gynec. and Obst.* 97 : 257 - 266, 1953.
- 4) DUBOST, C., ALLARY, M. and OEGONOMOS, N. : *Arch. Surg.*, 64 : 405 - 408, 1952.
- 5) EDWARDS, W. S. : Plastic arterial grafts, C. C. Thomas Publisher, Springfield, Ill., 1957.
- 6) KIMOTO, S. : *Rinsho-geka* 6 : 2, 51-57, 1951. (Japanese)
- 7) KIMOTO, S. : *Kokyu to Junkan* (Respiration and Circulation), 1 : 3, 143,154, 1953. (Japanese)
- 8) KIMOTO, S., SUGIE, S. and TSUNODA, M. : *Arch. Surg.*, 69 : 549- 1954.
- 9) KIMOTO, S. : *Geka* 20 : 5, 343-356, 1958. (Japanese with English abstract)
- 10) MARRANGONI, A. G. and CECCHINI, L. P. : *Ann. Surg.*, 134 : 977-983, 1951.
- 11) NAKAYAMA, K., SUZUKI, J. and KIMURA, S. : *Shujutsu* 8 : 6, 410 - 418, 1954. (Japanese)
- 12) ROB, C. G. and WILLIAMS, J. P. : *J. Cardiovas. Surg.* 2 : 1, 55-59, 1961.

- 13) SCALES, J. T. : *Proc. Roy. Soc. Med.*, **46** :647, 1953.
- 14) STALLWORTH, J. M., PRINCE, R. G., Jr., HUGHES, J. C., III. and PRAKER, E. F. : *Ann. Surg.* **155** : 5, 711-721, 1962.
- 15) WADA, T. : *Igaku no ayumi* **27** : 7, 395-399, 1958. (Japanese)
- 16) WADA, T. *Rinsho no Nippon* **5** : 10, 698-703, 1959. (Japanese)
- 17) YONEKAWA, K., KOJIMA, T. and MURAKAMI, A. : *Geka* **23** : 7, 769-772, 1961 (Japanese)

EXPLANATION OF PLATES

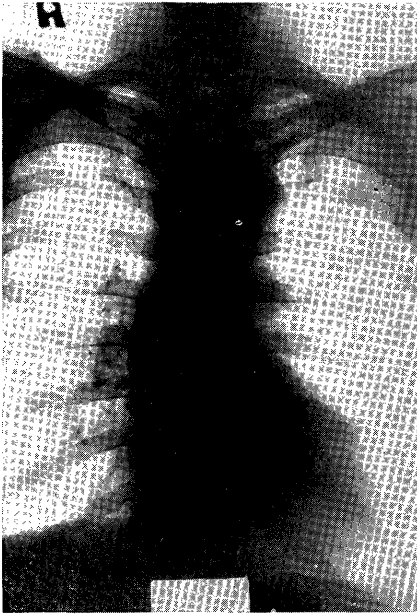

Fig. 2 Chest X-ray, demonstrating an enlargement of aortic arch.




Fig. 3 E. C. G. [before (left) and after (right) operation.

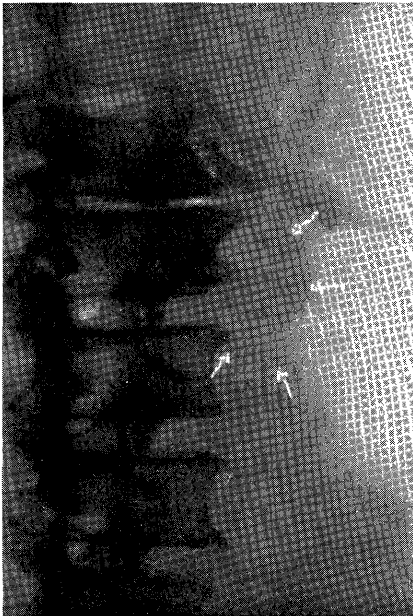


Fig. 4 Plain film of abdomen, showing rim of calcified aneurysm.

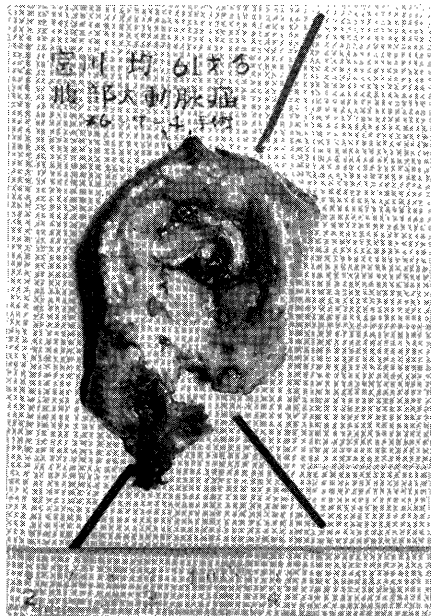


Fig. 5 Internal surface of aneurysm, showing degeneration and calcification with incomplete lacerations in places.