

# The Nerve Supply of the Anterior Supracostal Muscle in Man and Its True Nature

by

Ryosuke MIYAUCHI and Takasuke TAGAWA\*

*Department of Anatomy, Medical College of Oita,  
Oita 879-56, Japan*

*\*First Department of Anatomy, Fukuoka University,  
School of Medicine, Fukuoka 814-01, Japan*

Received for publication, February 1, 1983

For clarification of the nerve supply of the anterior supracostal muscle in humans as well as its true nature, a number of thoracic walls were examined and 10 cases of the muscle were found. In 9 cases out of 10, the muscle was confirmed to be innervated by the Ramus muscularis externus of the intercostal nerve. The nerve supply was unknown in one case. The muscle was considered to be differentiated from the external intercostal muscle from the standpoint of the nerve supply.

## INTRODUCTION

There is at present disagreement on the nerve supply to the anterior supracostal muscle of man with some reports describing it to be innervated by the R. muscularis externus of the intercostal nerve, and other reports describing it to be supplied by the lateral cutaneous branch of the intercostal nerve. MIYAUCHI (1982), who had examined a number of human anterior thoracic walls for confirmation of the nerve supply of the muscle and its true nature, found the muscle in three cases. While the nerve supply of the muscle was unknown in one of the three cases, the other two cases were confirmed to be innervated by the R. muscularis externus of the first intercostal nerve. It was considered appropriate, from the viewpoints of nerve supply and topography, to regard the muscle as that being differentiated from the external intercostal muscle. However, since the number of cases in which the muscle was found was small, doubt still remained as to whether the muscle which is innervated by the lateral cutaneous branch of the intercostal nerve would be existent on the anterior thoracic wall.

The present authors examined a number of human thoracic walls at the time of dissecting practice for medical students at the School of Medicine, Fukuoka University and Medical College of Oita in 1981 and 1982. On those occasions, 10 cases of the muscle were found. The findings obtained will be reported in the present paper along with an attempt to discuss the true nature of the muscle.

## MATERIALS AND METHODS

Materials consisted of 108 bodies which had been supplied for the dissecting practice for students at the School of Medicine, Fukuoka University (66 bodies) and Medical College of Oita (42 bodies). The both sides of the anterior thoracic wall of those bodies were investigated.

The presence of the anterior supracostal muscle was checked and bodies with the muscle were singled out. It was first examined whether the lateral cutaneous branch of the intercostal nerve innervated the muscle or not, and the following methods were taken to examine whether the muscle was supplied by the R. muscularis externus of the intercostal nerve. The external intercostal muscle was incised along the lower edge of the rib and was reflected downwards. The R. muscularis externus, which was existent between the external and internal intercostal muscles, was traced from its origin to the peripheral direction.

The examination was carried out under a magnifier with an illumination attachment.

## FINDINGS (Figs. 1-9) AND DISCUSSION

### 1. Identification of the Anterior Supracostal Muscle and the Frequency of Its Occurrence

WOOD (1865) first introduced a thin, anomalous muscle, which arose from the 1st rib near the costal cartilage, and ran downwards to insert into the 2nd, 3rd, and 4th ribs at the location between origins of the pectoralis minor and the serratus anterior muscles. BOCHDALEK (1867), who later found an analogous muscle, called it "Musculus supracostalis anterior anomalus". EISLER (1912) called generally "M. supracostalis" the anomalous muscle, arising from the rib, inserting into the lower ribs, and being superimposed on the external intercostal muscles on the thorax. He classified it into two groups: one which is existent on the medial side of the origin of the serratus anterior muscle and the other being existent on the lateral side. The former was called M. supracostalis anterior and the latter, M. supracostalis posterior. The names first employed by him have been generally used so far.

Inspection was made on the anterior supracostal muscle on the basis of the view of EISLER, and the muscle was found in 9 body-sides out of 216 (4.17% in the frequency of occurrence). MORI (1964) discovered the muscle in 126 body-sides (5.25%) out of

2400 and MIYAUCHI (1982) found it in 3 body-sides (6%) out of 50. The frequency of occurrence of the muscle obtained in the present study is smaller than that obtained by MORI and MIYAUCHI. However, it seems that significant difference can hardly be found between our results and theirs. The frequency of occurrence will possibly be close to that of MORI's, should the number of cases to be examined be increased.

In one side of a body (cadaver number 74), two of the muscle were found (Figs. 1a and b). Therefore, 10 of the muscle were found in a total of 9 body-sides in the present study. No report has been available so far in which plural numbers of the muscle were found in one side of a body.

The muscle originated from the first rib (all the cases), coursed downwards, skipping over one or two ribs, and inserted into the 3rd (7 cases), the 3rd and 4th (2 cases) or the 4th rib (1 case). These findings, being analogous to those in previous reports, can be said as nothing particular.

## 2. Nerve Supply of the Anterior Supracostal Muscle

The nerve supply of one case out of the ten cases of the muscle found in the present study was unknown. In the other 9 cases, the muscle was confirmed to be innervated from its inner surface by R. muscularis externus (according to the naming of FUJITA, 1963) of the first intercostal nerve (Figs. 1-9).

TAKESHIGE *et al.* (1968) and KANEKO *et al.* (1978) reported that the muscle was supplied by the lateral cutaneous branch of the intercostal nerve. HORIGUCHI *et al.* (1980) and YAMAZAKI (1981) reported, on the other hand, that the muscle was innervated by the R. muscularis externus of the intercostal nerve. MIYAUCHI (1982), one of the present authors, found 3 cases of the muscle and confirmed that two cases of them were supplied by the R. muscularis externus of the 1st intercostal nerve (the nerve supply was unknown in the remaining one case).

Reports by FORSTER (1917), DAVIES *et al.* (1931), SIDDIQI *et al.* (1935), FUJITA (1963), SATO (1973), and MIYAUCHI (1982) on the lateral cutaneous branch and the R. muscularis externus can be summarized as follows: The lateral cutaneous branch runs peripherally between the innermost and internal intercostal muscles and emerges onto the thoracic wall piercing the internal and external intercostal muscles near the origin of the serratus anterior muscle. On the other hand, the R. muscularis externus runs peripherally (towards the sternum) between the internal and external intercostal muscles.

The filament of the R. muscularis externus which innervates the muscle must pierce the external intercostal muscle before reaching the muscle (Figs. 1-9). If the filament is considered to have pierced the external intercostal muscle together with the lateral cutaneous branch, it would easily be mistaken as a filament from the lateral cutaneous branch. It does not mean that TAKESHIGE *et al.* and KANEKO *et al.*, tracing the filament that innervates the muscle to the central direction, confirmed it being originated from the lateral cutaneous branch. Therefore, their reports on the nerve supply of the muscle seem to be not so reliable. On the contrary, it seems, if a bold judgment is permissible, that they possibly misunderstood the filament which innervates the muscle,

namely the filament from the R. muscularis externus, as a filament from the lateral cutaneous branch.

In the present study as well as the past study by MIYAUCHI, no anterior supracostal muscle which was supposed to be supplied by the lateral cutaneous branch of the intercostal nerve was found. Therefore, even though the reports by TAKESHIGE *et al.* and KANEKO *et al.* are regarded as trustworthy, it is quite natural to consider that the anterior supracostal muscle which is supplied by the R. muscularis externus generally appears and that the muscle innervated by the lateral cutaneous branch rarely appears.

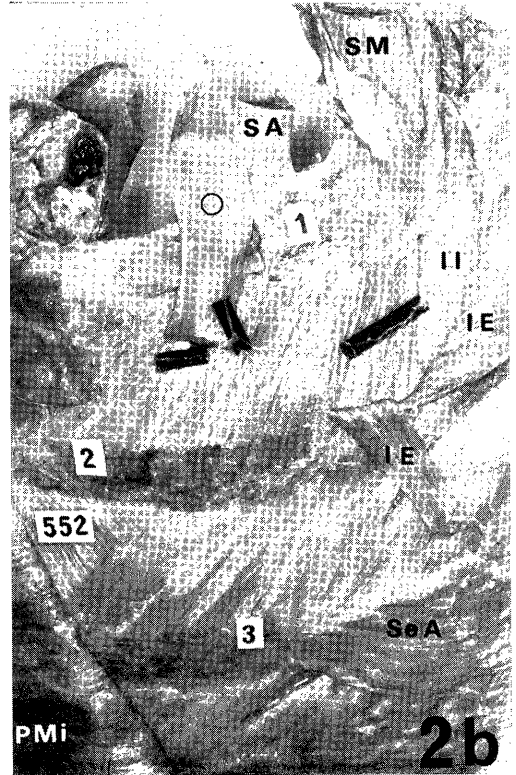
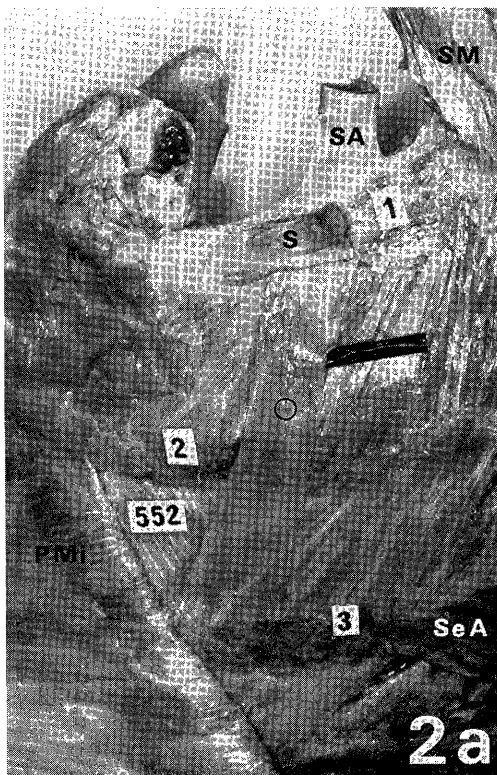

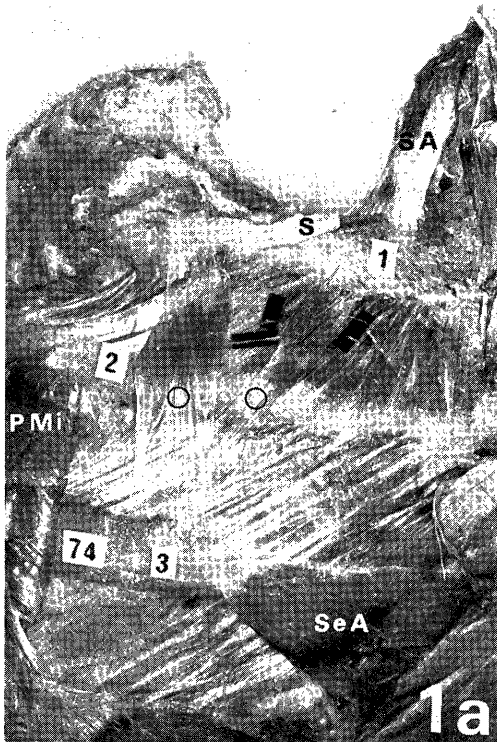
### 3. True Nature of the Anterior Supracostal Muscle

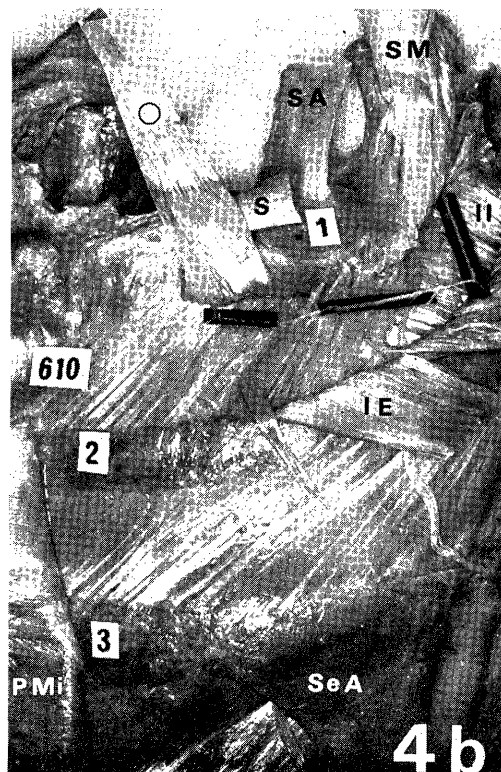
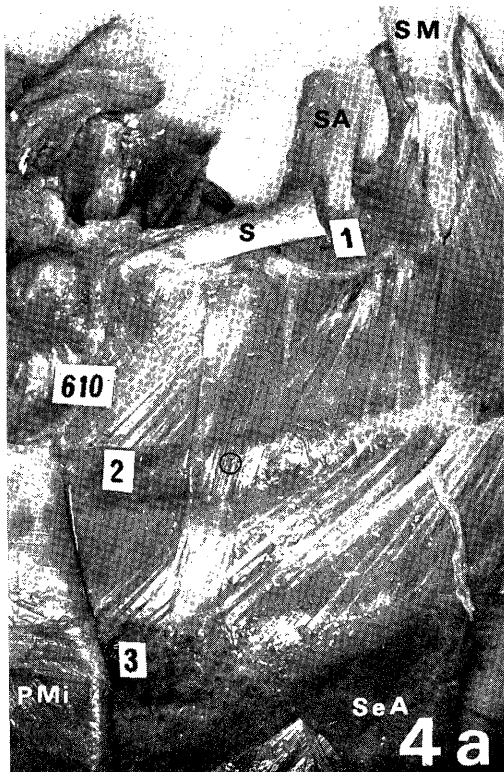
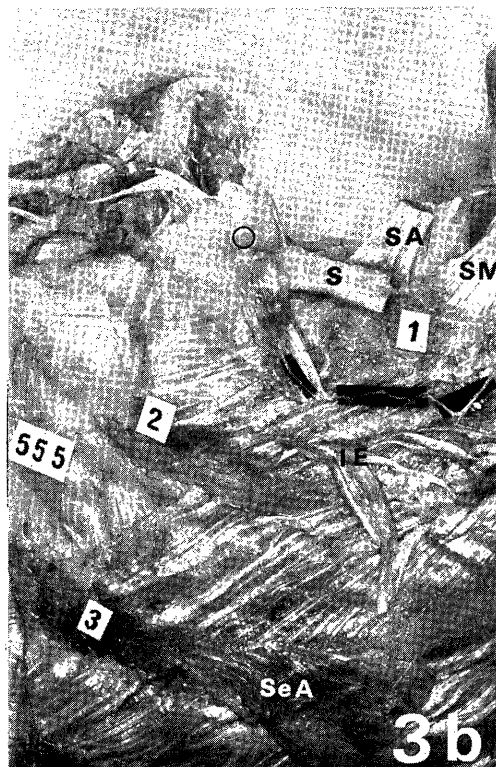
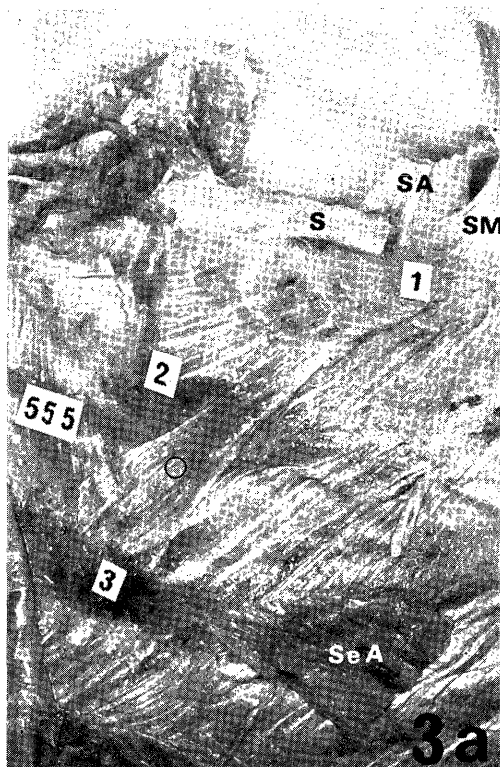
True nature of the anterior supracostal muscle has been discussed by many researchers and different conclusions have been led from the viewpoints of topography and comparative anatomy as well as nerve supply to this muscle. Views on the true nature of this muscle may be classified generally into (1) those that consider it to be homologous with the sterno-costalis muscle, which is always present on the anterior thoracic wall of mammals excluding monotremes, anthropoids and man (WOOD, 1867, 1870), (2) those that regard this muscle as being homologous with the pectoral end of the rectus abdominis muscle of mammals (TURNER, 1867, 1868), (3) those that assume it to belong to the same system as the scalenus muscles (TESTUT, 1911), and (4) those that claim it as being derived from the external intercostal muscle (BOCHDALEK, 1867; MATSUMOTO *et al.*, 1963; TAKESHIGE *et al.*, 1968; KANEKO *et al.*, 1978; YAMAZAKI, 1981, *etc.*).

It is considered theoretical to take a innervating nerve, which preserves the most stable relations with muscle, as criteria for judging to which muscular system an anomalous muscle belongs. Among 10 cases of the anterior supracostal muscle found in the present study, 9 cases were supplied by the R. muscularis externus of the first intercostal nerve. Therefore, it is appropriate to regard these muscles as being those differentiated from the external intercostal muscle within the 1st intercostal space. Moreover, based on the absence of any mention of a similar muscle with nerve supply from the R. muscularis externus in reports of studies on mammals other than man, the anterior supracostal muscle might tentatively be considered to be progressive variation.


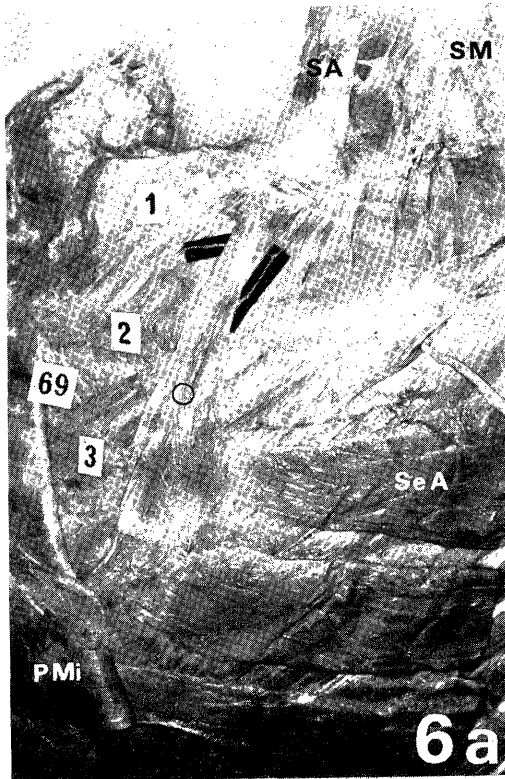
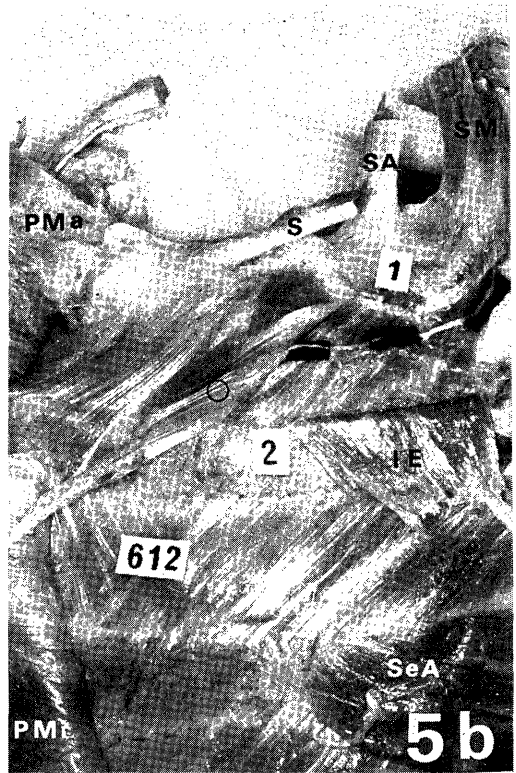
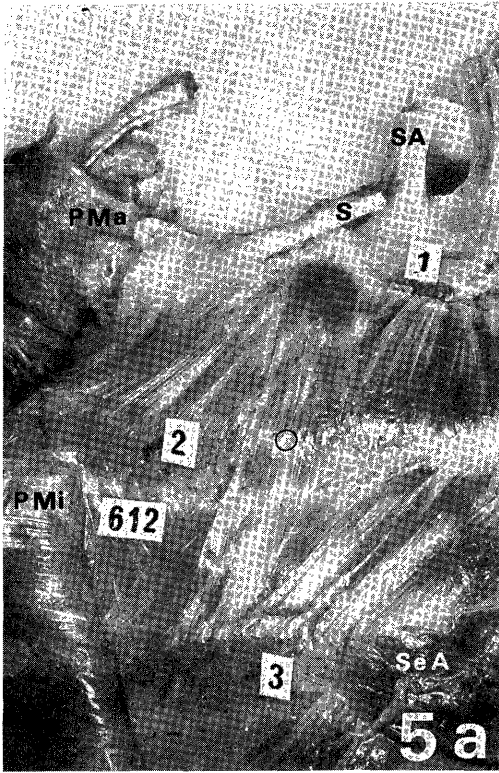
The muscles that have been reported in terms of the anterior supracostal muscle by TAKESHIGE *et al.* and KANEKO *et al.* should for the reason outlined below be more appropriately considered to belong to the same muscular system as the sterno-costalis muscle, which is always present on the anterior thoracic wall of mammals excluding man, anthropoids and monotremes. Moreover, their muscles are considered to be atavistic variation.

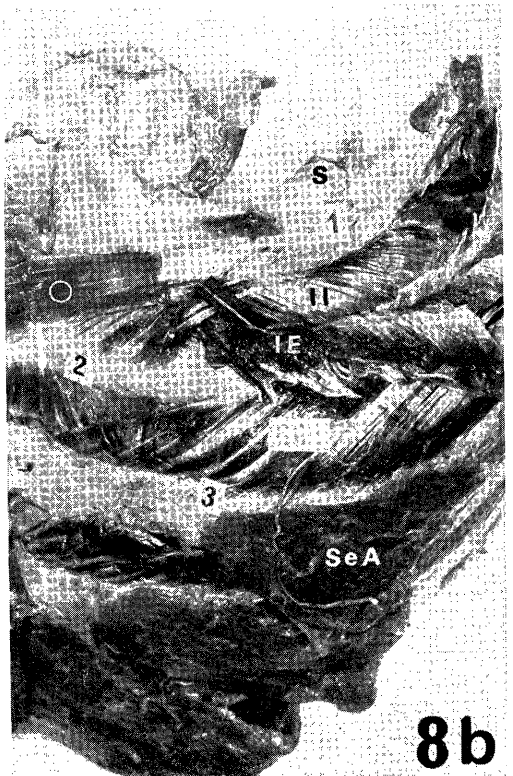
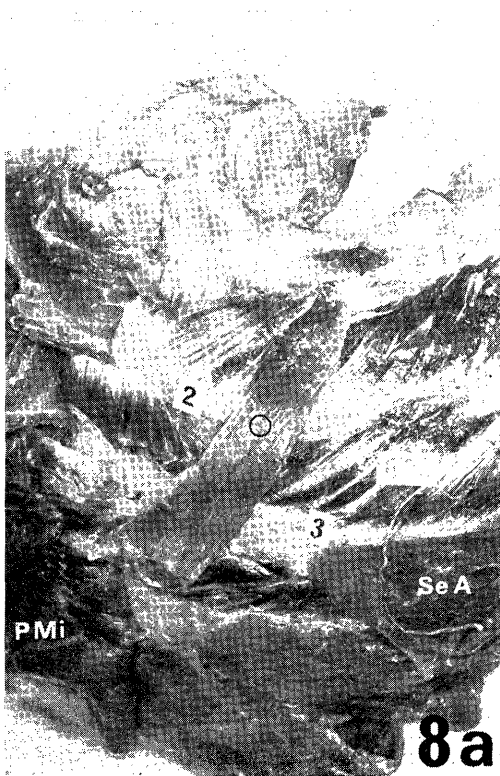
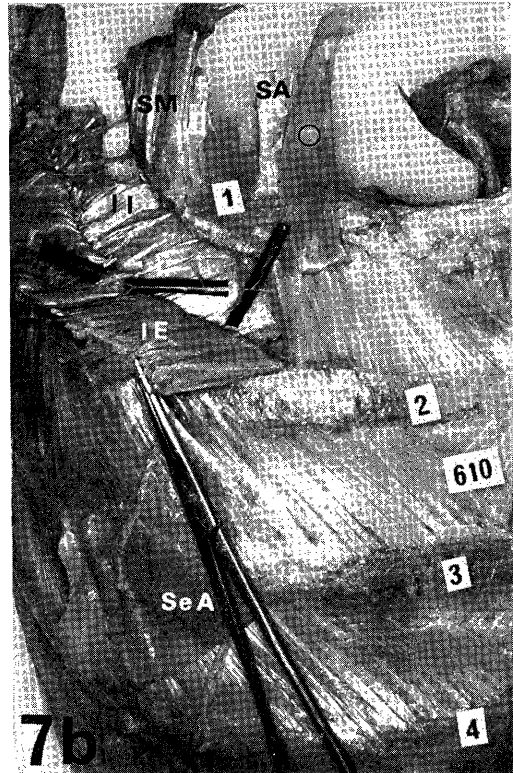
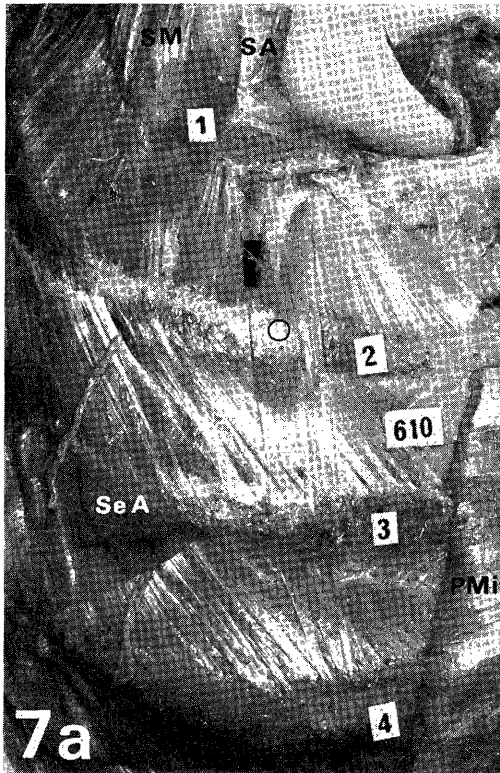
WOOD (1867, 1870), following his first report (1865) of the human supracostal muscle, carried out comparative-anatomical studies of this muscle. From the results obtained, he considered the muscle to be homologous with the sterno-costalis muscle, which is constantly present on the anterior thoracic wall of many mammals. Many investigators subsequently performed comparative-anatomical studies on the sterno-costalis muscle, the true nature of which was considered by them to be one of homology with
















## EXPLANATION OF FIGURES

### Abbreviations in figures

IE: external intercostal muscle, II: internal intercostal muscle, O mark: anterior supracostal muscle, PMa: pectoralis major muscle, PMi: pectoralis minor muscle, S: subclavius muscle, SA: scalenus anterior muscle, SeA: serratus anterior muscle, SM: scalenus medius muscle, 1-4: first to fourth ribs.

**Figs. 1a and b.** Cadaver number 74; Japanese male; age 58 years at time of death; death due to cerebral hemorrhage. Two of the anterior supracostal muscle have been existent in this case. The location of the R. muscularis externus has been indicated

with the small pieces of black paper. a. Anterolateral view. b. Anterolateral view. The external intercostal muscle within the first intercostal space has been reflected downwards so as to expose the Ramus muscularis externus of the first intercostal nerve. The anterior supracostal muscle situated laterally has been reflected lateralwards so as to expose its nerve supply.

**Figs. 2-8.** Anterolateral view. The location of the R. muscularis externus of the first intercostal nerve has been indicated with the small pieces of black paper. b The anterior supracostalis muscle has been reflected upwards or medialwards so as to expose its nerve supply. The external intercostal muscle within the first intercostal space has been reflected downwards so as to expose the R. muscularis externus of the first intercostal nerve. Figs. 2a and b. Cadaver number 552; Japanese female; age 72 years at time of death; death due to uremia. Figs. 3a and b. Cadaver number 555; Japanese female, age 98 years at time of death; death due to heart failure. Figs. 4a and b. Cadaver number 610; Japanese male; age 85 years at time of death; death due to heart failure. Figs. 5a and b. Cadaver number 612; Japanese female; age 90 years at time of death; death due to heart failure. Figs. 6a and b. Cadaver number 69; Japanese female; age 81 years at time of death; death due to bronchopneumonia. Figs. 7a and b. Cadaver number 610. Figs. 8a and b. Cadaver number 603; Japanese female; age 57 years at time of death; death due to hepatic insufficiency.

**Fig. 9.** Cadaver number 556; Japanese female; age 55 years at time of death; death due to cardiac insufficiency. Anterolateral view. The nerve supply to the anterior supracostal muscle in this case was unknown.

the rudiment of the cranial portion of the external oblique thoraco-abdominalis muscle of lower mammals (RUGE, 1892; CALS, 1902; Tschachmachtschjan, 1912; FORSTER, 1916; CORDS, 1924; MATSUO, 1960; *etc.*). According to KOHLBRÜGGE (1897), CALS (1902), CORDS (1924), MATSUO (1960), and others, the sterno-costalis muscle is supplied by the lateral cutaneous branch of the intercostal nerve, similarly to the external oblique thoraco-abdominalis muscle or the external oblique abdominis muscle. It should be mentioned also that BARDEEN (1902), EISLER (1912), FUJITA (1963), SATO (1973), and many anatomy textbooks have described the human external oblique abdominis muscle as being supplied by the lateral cutaneous branches of the intercostal nerves. Consideration of the above-mentioned reports suggests that the anterior supracostal muscle, described in man as being supplied by the lateral cutaneous branch of the intercostal nerve (TAKESHIGE *et al.* and KANEKO *et al.*), should be regarded as homologous with the sterno-costalis muscle.

The muscle, as mentioned in the part for the nerve supply of the anterior supracostal muscle, which is supposed to be supplied by the lateral cutaneous branch of the intercostal nerve seems not to be existent. Therefore, it can be conjectured that the anterior supracostal muscle, being homologous to the sterno-costalis muscle, would not be existent.

## SUMMARY

In order to determine the nerve supply of the anterior supracostal muscle as well as to determine its true nature, the anterior thoracic wall of 108 bodies were examined. Findings obtained and discussions are as in the following:

1) The muscle was observed in 9 body-sides out of 216 (frequency of occurrence at 41.7%). Two cases of the muscle were found in one side of a body. Therefore, a total of 10 cases of the muscle were found in the present study.

This muscle arose from the 1st rib and inserted into the 3rd (7 cases), the 3rd and 4th (2 cases) or the 4th rib (1 case).

2) In 9 cases out of 10, the muscle was confirmed to be supplied by the R. muscularis externus of the 1st intercostal nerve. In one case, the nerve supply was unknown.

A few researchers reported that this muscle was supplied by the lateral cutaneous branch of the intercostal nerve. As an opposition to those reports, the filament which innervates the muscle was shown to be easily mistaken as a filament from the lateral cutaneous branch. Furthermore, the muscle which is supposed to be supplied by the lateral cutaneous branch was conjectured not to be existent.

3) Discussion was made on the true nature of the anterior supracostal muscle. From the viewpoints of the nerve supply to the muscle, it was regarded as a muscle differentiated from the external intercostal muscle. It was further regarded as being

progressive variation from the comparative-anatomical viewpoints.

The muscle which is supplied by the lateral cutaneous branch of the intercostal nerve was reported in terms of the anterior supracostal muscle by several researchers. From the viewpoints of the nerve supply as well as the comparative anatomy, their muscle should have been regarded as being homologous to sterno-costalis muscle of mammals excluding man, anthropoids and monotremes. Furthermore, that kind of muscle was conjectured not to be existent in humans.

#### REFERENCES

- 1) BARDEEN, Ch. R.: A statistical study of the abdominal and bordernerves in man. *Am. J. Anat.*, 1: 203-228, 1902.
- 2) BOCHDALEK, jun.: Ein anomaler Musculus supracostalis anterior. *Arch. Pathol. Anat.*, 41: 257-258, 1867.
- 3) CALS, G.: Recherches sur queques muscles de la région pectorale au point de vue de l'anatomie comparée. *Bibliogr. Anat.*, 11: 89-111, 1902.
- 4) CORDS, E.: Zur vergleichenden Morphologie des M. sterno-costalis. *Z. Anat. Entwicklungsgesch.*, 71: 261-281, 1924.
- 5) DAVIES, F., GLADSTONE, R. J. and STIBBE, E. P.: The anatomy of the intercostal nerves. *J. Anat.*, 66: 323-333, 1931.
- 6) EISLER, P.: Die Muskeln des Stammes. Bardelebens Handbuch der Anatomie des Menschen. Gustav Fischer, Jena, 1912.
- 7) FORSTER, A.: Beitrag zur Morphologie des Scalenussystems und des M. sterno-costalis. Eine vergleichend-anatomische Untersuchung. Teil I und Teil II. *Z. Morphol. Anthropol.*, 19: 28-148, 272-352, 1916.
- 8) FORSTER, A.: Zur Morphologie der Muskeln des Thorax. IV. Teil (1. Abschnitt). *Z. Morphol. Anthropol.*, 20: 629-686, 1917.
- 9) FUJITA, T.: Ist der "M. intercostalis intermedius" Eisler anatomisch selbständig? *Fol. anat. jap.*, 39: 15-30, 1963.
- 10) HORIGUCHI, M., YAMADA, T. and ISHII, T.: Innervation of the human supracostalis anterior muscle. *Acta Anat. Nippon.*, 55: 332, 1980 (Abstract in Japanese).
- 11) KANEKO, M., NORIYASU, S. and MITSUHASHI, K.: On a case of Musculus supracostalis anterior, Bochdalek junior, variation. *Acta Anat. Nippon.*, 53: 157-166, 1978 (in Japanese).
- 12) KOHLERÜGGE, J. H. F.: Muskeln und periphere Nerven der Primaten, mit besonderer Berücksichtigung ihrer Anomalien. *Verh. Koningkl. Akad. van Wetenschappen te Amsterdam 2. Ser. Deel 5*, 1897.
- 13) MATSUMOTO, T., ARIHARA, K. and ODA, K.: Anomalies observed on anatomical dissection. V) Two cases of Musculus supracostalis anterior (Bochdalek jr., Var.). *Kansaidaishi*, 15: 178-181, 1963 (in Japanese).
- 14) MATSUO, T.: Muscles of the anterior chest of Macacus Cyclopsis. *Okajimas Fol. Anat. jap.*, 34: 571-586, 1960.
- 15) MIYAUCHI, R.: On the Musculus supracostalis anterior. *Okajimas Folia Anat. Jpn.*,

- 59: 45-64, 1982.
- 16) MORI, M.: Statistics on the musculature of the Japanese. *Okajimas Fol. anat. jap.*, 40: 195-300, 1964.
  - 17) RUGE, G.: Der Verkürzungsprocess am Rumpfe von Halbaffen. Eine vergleichend-anatomische Untersuchung. *Morphol. Jahrb.*, 18: 185-326, 1892.
  - 18) SATO, T.: On the homology of the obliquus externus abdominis with the intercostales externi. *Proc. Japan Acad.*, 49: 271-275, 1973.
  - 19) SIDDIQI, M. A. H. and MULLICK, A. N.: On the anatomy of intercostal spaces in man and certain other mammals. *J. Anat.* 69: 350-355, 1935.
  - 20) TAKESHIGE, Y., KANAYA S. and SATO, S.: Über einen Fall des M. supracostalis anterior. *Kurume Med. J.*, 31: 67-69, 1968 (in Japanese).
  - 21) TESTUT, L.: *Traité d'anatomie humaine*. 6 éd. le T., Octave Doin et Fils, Paris, 1911.
  - 22) TSCHACHMACHTSCHJAN, H.: Über die Pectoral-und Abdominal-musculature und über die Scalenus-Gruppe bei Primaten. *Gegenbaurs Morphol. Jahrb.*, 44: 297-370, 1912.
  - 23) TURNER, W.: On the Musculus sternalis. *J. Anat. Physiol.*, 1: 246-253, 1867.
  - 24) TURNER, W.: Note on the occasional occurrence of the Musculus rectus thoracis in man. *Proc. R. Soc. Edinburgh.*, 6: 268-270, 1868.
  - 25) TURNER, W.: Report on the progress of anatomy. *J. Anat. Physiol.*, 2: 392-406, 1868.
  - 26) WOOD, J.: Additional varieties in human myology. *Proc. R. Soc. Lond.*, 14: 379-392, 1865.
  - 27) WOOD, J.: Variations in human myology observed during the winter session of 1866-67 at King's College, London. *Proc. R. Soc. Lond.*, 15: 518-546, 1867.
  - 28) WOOD, J.: On a group of varieties of the muscles of the human neck, shoulder and chest, with their transitional forms and homologies in the Mammalia. *Philos. Trans. R. Soc. Lond.*, 160: 83-116, 1870.
  - 29) YAMAZAKI, M.: Innervation of the anterior supracostal muscle. *Acta Anat. Nippon.*, 56: 19-27, 1981. (in Japanese).