

Hidrotic Ectodermal Dysplasia with Ichthyosiform Erythroderma-like Skin Changes — An Autopsy Case —

Minoru YOKOTA, Kioko KAWAI, Joshu MATSUDA*
Kenji KUMAGAI, Kenji MATSUO
and Hideo TSUCHIYAMA

The Second Department of Pathology, The Department of Pediatrics,
Nagasaki University School of Medicine, Nagasaki*

Received for publication, July 2, 1984

We present an autopsy case of 30-day-old female infant who had hidrotic ectodermal dysplasia with ichthyosiform erythroderma-like skin changes and low value of migration test of neutrophils. At the time of birth she had the absence of hairs, eyelashes, eyebrows, dystrophic nails, erythema and hyperkeratosis with scales on whole body.

Autopsy revealed the presence of eccrine glands and hyperkeratosis of the epidermis, thymic involution and papillary proliferation of squamous epithelium in esophagus and vagina. Aspiration pneumonia is the immediate cause of her death.

The co-existence of ectodermal dysplasia and ichthyosiform-skin changes in this case provide an opportunity to study the relationship between congenital dysplasia and ichthyosiform erythroderma in their development. It might also be possible to correlate that relationship on common ground of immunological insufficiency.

INTRODUCTION

Congenital ectodermal dysplasia (CED) is a hereditary disease and classified into two forms, the hidrotic form and anhidrotic form. Hidrotic ectodermal dysplasia is characterized by the absence of hair, eyelashes, eyebrows, dystrophic nails and hyperkeratosis of palms and soles, and normal dentition. Sweating is present and the eccrine gland is normal in the structure and function. Recently the cases of CED associated with ichthyosiform erythroderma⁴⁾⁶⁾ or immunodeficiency³⁾⁴⁾⁵⁾⁶⁾⁹⁾ have been reported.

横田 実, 河合紀生子, 松田静宗, 熊谷謙治, 松尾健治, 土山秀夫

In this paper we present a rare case of hidrotic ectodermal dysplasia associated with ichthyosiform erythroderma-like skin changes and make on a comment on the possible relation and the classification of these disease.

CASE REPORT

This patient was a Japanese female infant aged 30 days who was born in the thirty-sixth week in the gestation, weighed 2450g and was 46.5cm in length. Apgar score was 8 points because of no crying. The delivery with amniotic fluid, placenta and umbilical cord were normal except early rupture of the membranes. Her father was 32 years old,

Table 1. Sweating Induced Test and Eccrine Sweat Gland

Site	Sweating Induced Test	Eccrine Sweat Gland (Microscopically)
Scalp	—	‡
Face	—	N.E.
Chest	N.E.	‡
Upper arm	+	N.E.
Axillae	‡	N.E.
Abdomen	+	—
Inguinal	‡	N.E.
Lower leg	—	—

‡ ... present, + ... slightly present, — ... absent, N.E. ... Not examined

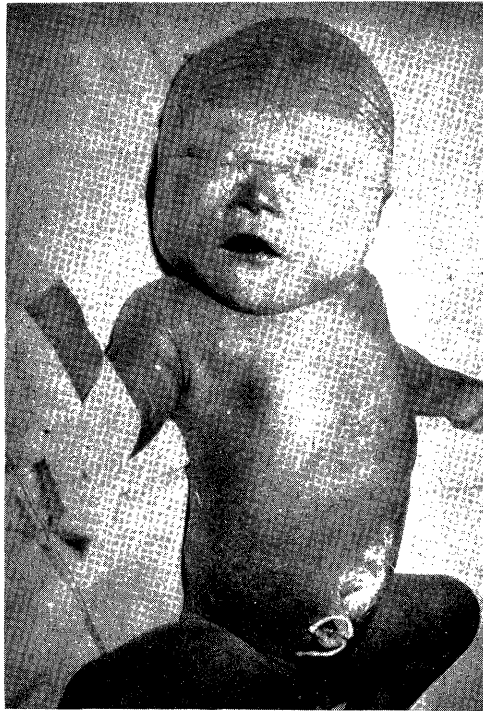

Fig. 1. Head and face: The absence of hair, eyelashes and eyebrows.

her mother was 29 years old with the pregnant history of two spontaneous abortions. During this gestation, she had no specific drugs, infection and irradiation. Her WAS-SERMAN's reaction was negative. The hereditary history was not obscure except with no parental consanguinity. Physical examination of members of her family was not able to perform. She had a healthy elder brother of 3 years age. At the time of birth, she had white coating on skin of face and head, and the erythema on whole body and absence of hair. She had tachypnea and groan, and didn't cry. She was admitted to the Pediatrics of Nagasaki University Hospital on her birth day.

Physical examination on admission revealed the absence of hairs, eyebrows, eyelashes and narrowing lid fissures (Fig. 1). All nails were hypoplastic and showed peg-

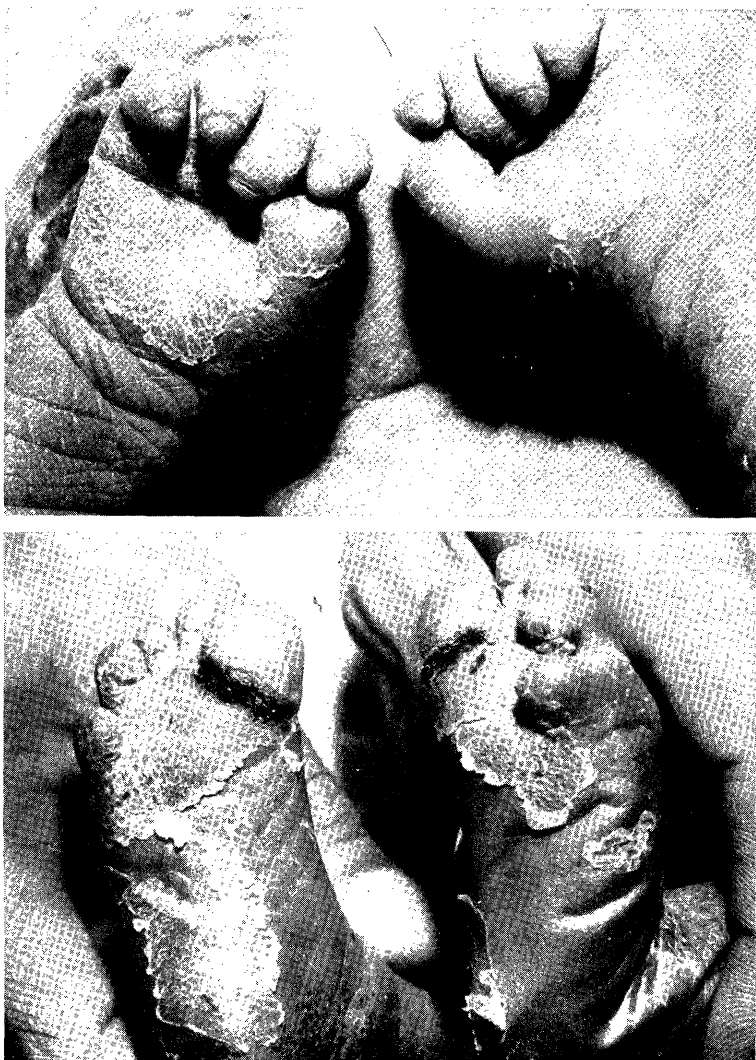

Fig. 2. Hands and feet: Marked hyperkeratosis on both palms and soles, and hypoplastic nails. Normal striped finger printing and palm-printing are disappeared and become fine granular under hyperkeratotic scales. These findings are considered to be compatible with the characteristics of hydrotic ectodermal dysplasia.

shaped deformity with small bending interphalangeal joints (Fig. 2). The generalized skin, especially of the abdomen was dry, hyperkeratotic and erythematous covered with the fish-like scales, having an appearance of ichthyosiform erythroderma (Fig. 3). Hyperkeratosis was marked on palms and soles. Normal striped finger printing and palm printing were disappeared and became fine granular under the hyperkeratotic scales. These findings were considered to be compatible with the characteristics of hidrotic ectodermal dysplasia (Fig. 2).

There was sweating on the skin of axilla, abdomen and inguinal region (Table 1). She was diagnosed as hydrotic ectodermal dysplasia. Symptomatic therapy was performed by only antibiotics. Eventually erosion and hemorrhage of axillary and inguinal skin and severe dryness of oral cavity were developed. Her respiration were grown worse. On the thirtieth day, she died of respiratory failure due to aspiration pneumonia.

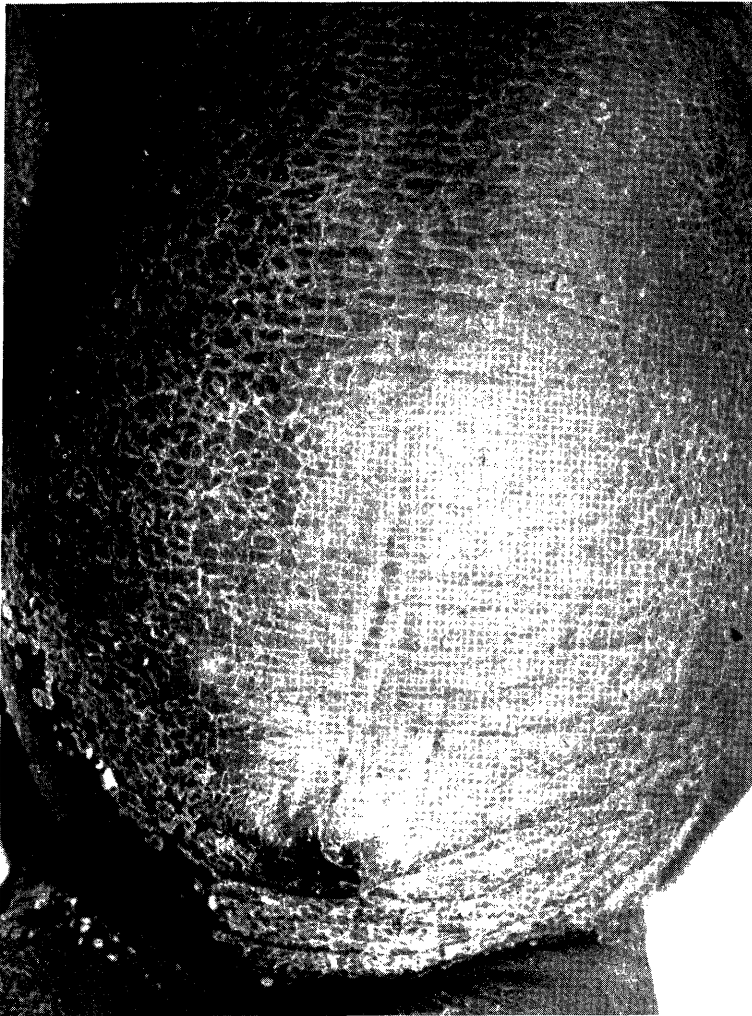

Fig. 3. Abdominal skin: Ichthyosiform erythroderma-like skin change.

AUTOPSY FINDINGS

The infant was poorly nourished, weighed 2.6g and was 107cm tall. Macroscopic observation of the body was same as the description of clinical findings in the case report.

Microscopic examination disclosed the rudimental hair follicles without hair shaft and the decreased sebaceous gland in the scalp, but the eccrine gland of the normal structure was found (Fig. 4-a, 4-b). Eccrine gland was absent in the skin of abdomen and lower leg (Fig. 5). Hyperkeratosis with partial parakeratosis was observed in the skin of head and chest (Fig. 4).

The stratum lucidum was thin, and the stratum granulosum was not thickened as that seen in ichthyosiform erythroderma. The stratum spinosum was almost normal and partially thin, but doesn't show flattening of the cell (Fig. 4, 5). Stratum basale was normal or mild loosely arrayed. Keratohyaline granule was in normal sized and found only in the skin of chest. Inflammatory change in the skin was observed on the abdomen and chest. Aspiration pneumonia with giant cells in both lungs was the immediate cause of her death.

In addition to these findings papillary proliferation of squamous epithelium in the

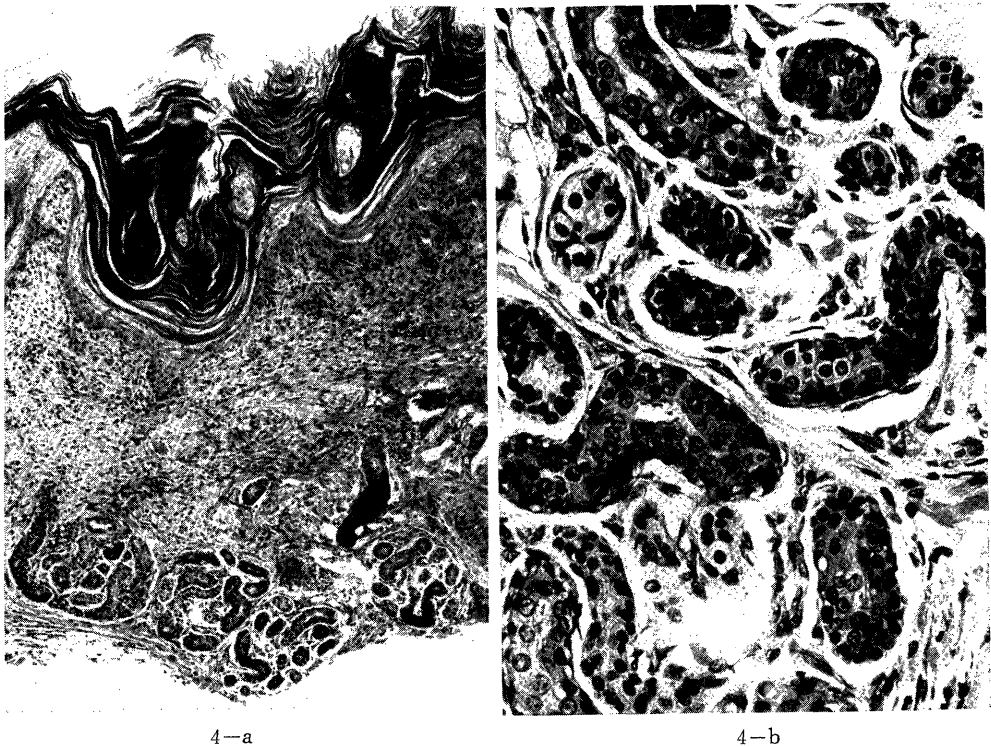


Fig. 4-a. Skin of head: Hyperkeratosis is noted. Rudimentary hair follicle is seen and eccrine glands are present.
4-b. Eccrine glands show normal structure.

esophagus and vagina without flattening of prickle cells was observed in upper portion (Fig. 6). The thymus weighed 2.6gm and revealed the pathological involution. The corticomedullary junction was indistinct and many Hassall's corpuscles were observed and

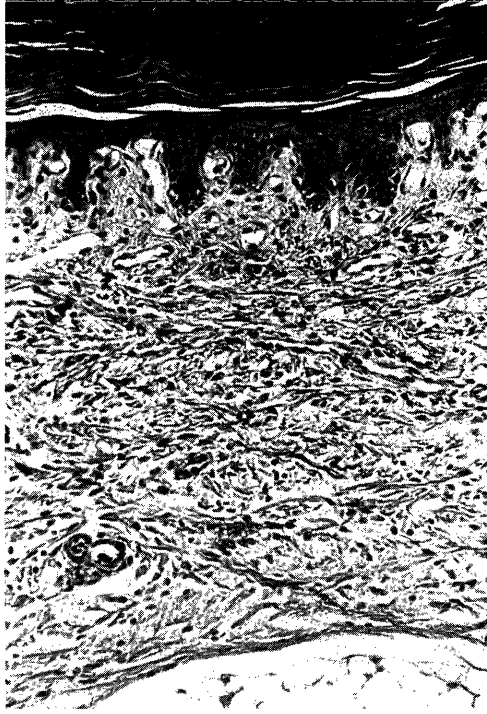

Fig. 5. Skin of lower leg: Hyperkeratosis is marked. No hair follicle and eccrine gland.

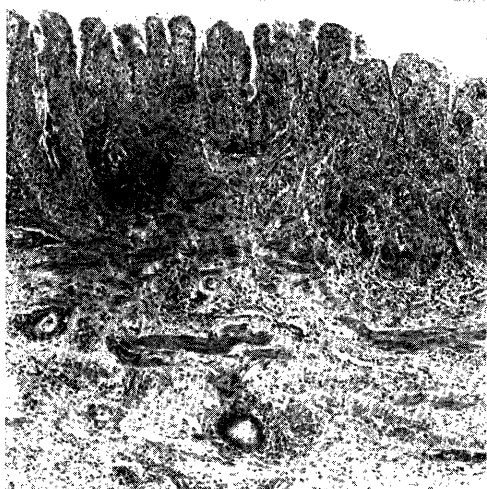


Fig. 6. Esophagus: The mucosa is thickened and discloses the papillary proliferation of squamous epithelium. In the upper portion of prickle layer, cells are cuboidal without flattening.

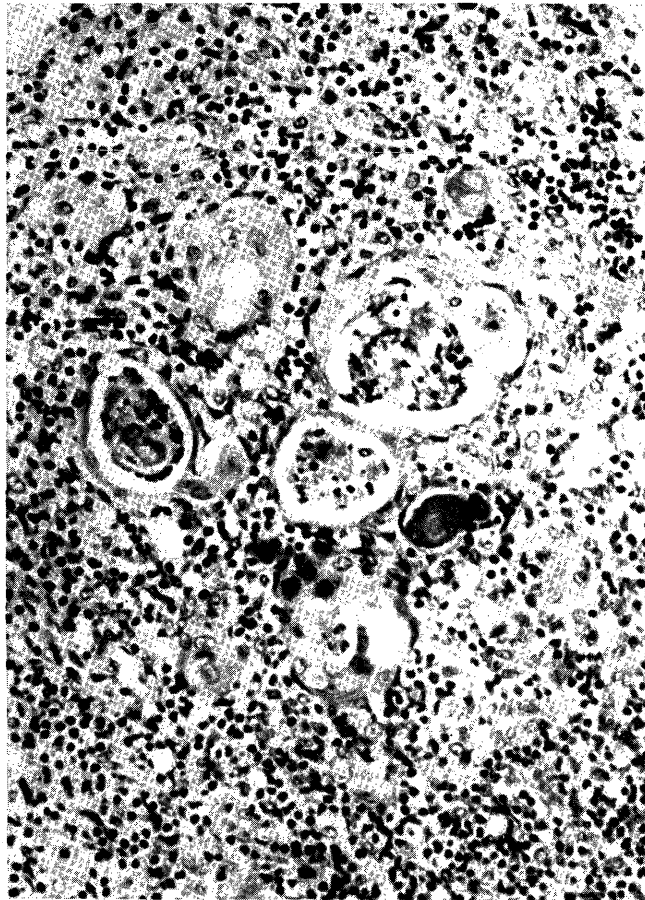


Fig. 7. Thymus: Thymus weighed 2.6gm and reveals pathological involution with HASSALL's corpuscles and cystic change.

showed partially cystic change (Fig. 7). The anomalies and abnormalities of the other organ and hypoplasia of lymph apparatus and bone marrow were not discovered.

COMMENT

In 1838, WIDDERBURN had noted ten cases of CED in a Hindu family and this was documented in a letter written to Charles DARWIN and quoted in "The Variations of Animals and Plants under Domestication"²⁾. WEECH¹²⁾ introduced the term hereditary ectodermal dysplasia and suggested the name "anhidrotic form" in 1929. In the same year, CLOUSTON¹⁾ described 119 cases of the hidrotic form in six generations of Canadian French, and stated that there were probably 6000 such patients in North America alone. He classified the CED into the hidrotic form and anhidrotic form by the presence of sweating and the form of inheritance. Most cases of hidrotic form occurs in persons of French descent and very rare in the Orient. Over one hundred cases of CED have

been reported in Japan, but there is no autopsy case that has been reported in Japan as far as we have reviewed. Ordinary the prognosis of this disease is not so poor and the clinical magnifestation is so minimal that the patient escape notice until adolescence or adult age⁸⁾. At the time of birth the infant in this case had the absence of hair, eyelashes and eyebrows, moderate dystrophy of nails, marked hyperkeratosis of whole body especially in palms and soles, and normal dentition. This infant were diagnosed as the typical case of hidrotic ectodermal dysplasia though the hereditary history was unknown.

In addition to these characteristic findings this infant revealed marked hyperkeratosis with scales and erythema on whole body. This findings suggested us that she had associated with ichthyosis erythroderma. There are some questions in the relationship of herditary keratosis and ectodermal dysplasia. UPSHAW and MONTGOMERY⁹⁾ included the hidrotic ectodermal dysplasia and congenital ichthyosiform erythroderma under congenital dysplasia, because of the overlapping among the various classification systems.

GATTI⁴⁾ and FEIGIN⁶⁾ reported the case of ectodermal dysplasia associated with erythematous ichthyosiform rash that was similar as our case. Including our case it is highly suggestive that ectodermal dysplasia and ichthyosiform erythroderma might be intimately involved in congenital dysplasia and it is the interesting case to investigate the relationship of their two diseases.

This case showed remarkable low value in migration test of neutrophil. PINCUS⁸⁾ reported the 4-year-old boy with defective neutrophil chemotaxis, hyperimmunoglobulinemia E and cutaneous disorders of alopecia, dystrophic nails and diffuse hyperkeratosis.

GATTI⁶⁾ suggested a basic association between skin, bone and immunologic development in his case of hereditary lymphopenic agammaglobulinemia associated with distinctive form of short-limbed dwarfism and ectodermal dysplasia. Similar cases were identified by several authors³⁾⁴⁾⁵⁾⁶⁾⁹⁾ suggesting some relationship between ectodermal dysplasia, ichthyosis and dyskeratosis congenita, and the defficiency of immunologic system. The thymus in this case weighed 2.6 g and the histological examination disclosed the appearance of pathological involution, There was no findings of dysplasia and hypoplasia that were reported by GATTI⁶⁾ and FEIGIN⁴⁾. Thymic involution was reported in the case of anhidrotic ectodermal dysplasia¹⁰⁾ and congenital ichthyosis erythroderma¹¹⁾. But this findings have not been regarded as common and characteristic phenomenons in CED or congenital ichthyosis¹¹⁾. In this case thymic involution might be occured as a result of severe illness, undernourishment or aspiration pneumonia.

Considering the facts above mentioned, ectodermal dysplasia may not be able to be diagnosed and classified only by previous classical criteria. Other variants of ectodermal and mesodermal anomalies and other syndromes must be investigated in detail. The new approach and classification including genetic and immunological study are expected.

The reason for the papillary proliferation of squamous epithelium in the esophagus and vagina in this case is unknown. The relatively thick esophageal epithelium was described in the case of anhidrotic ectodermal dysplasia¹⁰⁾ and the thickening of vaginal epithelium in congenital ichthyosis⁷⁾. We speculate that these findings might be related

to the faulty evolution of epidermis in CED or ichthyosis.

ACKNOWLEDGMENT

The authors gratefully thank Dr. Katsutaro NISHIMOTO, Associate Professor of Department of Dermatology, Nagasaki University Hospital, for his helpful advice.

REFERENCES

- 1) CIOUSTON, H. R.: A hereditary ectodermal dystrophy. *Canad. Med. Ass. J.* 21: 18-31, 1929.
- 2) DARWIN, C. R.: The variation of animals and plants under domestication. Vol. 2: 319, D. Appleton & Company, Inc. New York, 1894.
- 3) DAVIS, J. R. and SOLOMON, L. M.: Cellular immunodeficiency in anhidrotic ectodermal dysplasia. *Acta Dermatovener (Stockholm)*. 56: 115-120, 1976.
- 4) FEIGIN, R. D. *et al.*: Agammaglobulinemia and thymic dysplasia associated with ectodermal dysplasia. *Pediatrics*. 47: 143-147, 1971.
- 5) GIANNETTI, A. and SEIDENARI, S.: Deficit of cell-mediated immunity, chromosomal alterations and defective DNA repair in a case of dyskeratosis congenita. *Dermatologica*. 160: 113-117, 1980.
- 6) GATTI, R. A. *et al.*: Hereditary lymphopenic agammaglobulinemia associated with a distinctive form of short-limbed dwarfism and ectodermal dysplasia. *J. Pediatr* 75: 675-684, 1969.
- 7) INADA, S. and MASAOKA, Y.: An autopsy case of ichthyosis congenita gravis. *Rinsho to Hifuka*. 25: 469-475, 1971.
- 8) MONTGOMERY, H.: Dermatopathology Vol. 1. Hoeber Medical Division, Harper & Row, New York, P. 71. 1967.
- 9) PINCUS, S. H. *et al.*: Defective neutrophil chemotaxis with variant ichthyosis, hyperimmunoglobulinemia E, and recurrent infections. *J. Pediatr.* 87: 908-911, 1975.
- 10) REED, W. B. *et al.*: Clinical spectrum of anhidrotic ectodermal dysplasia. *Arch. Derm.* 102: 134-143, 1970.
- 11) WATANABE, S. and WATANABE, S.: Two brothers with ichthyosis congenita with thymic involution. *Arch. Dermat.* 114: 1225, 1978.
- 12) WEECH, A. A.: Hereditary ectodermal dysplasia. A report of two cases. *Amer. J. Dis. Child.* 37: 766-790, 1929.