

Brain Edema after Surgery of Lateral Ventricle Tumors

Shobu SHIBATA

*Department of Neurosurgery, Nagasaki University
School of Medicine, Nagasaki, Japan*

Received for publication, January 9, 1988

ABSTRACT : We reported five cases of lateral ventricle tumors all of which developed severe brain edema between nine days and eight years after surgery. Follow-up study with serial computed tomography before and after surgery were presented. Based on a review of the literature, a possible causal mechanism is suggested : 1) The cerebrospinal fluid diffuses into the white matter through the surgically damaged ependyma and causes severe postoperative edema ; and 2) surgical blockade of the flow of cerebral interstitial fluid to drain into the fenestrated vessels of the choroid plexus and other periventricular areas causes severe postoperative edema.

KEY WORDS : Lateral ventricle tumors, Postoperative brain edema

INTRODUCTION

In five cases of large lateral ventricle tumors severe brain edema and neurological deficits developed and persisted for a long period following resection of these tumors which had been reached through various cortical incisions to the ventricular wall at Nagasaki University Hospital. Their pathogenesis has been studied and reported in this paper.

CASE REPORTS

Case 1

A 16-year-old female had a meningioma in the trigone and body of the left ventricle subtotally removed through an incision of the middle temporal gyrus on September 9, 1977. Severe postoperative brain edema developed. Cystoperitoneal shunt was performed one year and five months after surgery. At present, eight years after surgery, she still has tremors of the right hand and hemianopsia (Table), and brain edema with mass effect is present surrounding a small cyst (Fig. 1).

Case 2

A 59-year-old female had an astrocytoma close to the left lateral ventricle removed after reaching the tumor by uncapping the middle temporal lobe on June 15, 1981. Severe brain edema developed after surgery and right hemiplegia persisted.

Radiotherapy was followed by reoperation, but she died of meningitis three months after the first surgery (Table). Computed tomography on the third postoperative day revealed brain edema, and it remained for three months accompanied by mass effect (Fig. 1).

Case 3

A 63-year-old female had a meningioma in the trigone and body of the left lateral ventricle subtotally resected through an incision of the middle temporal gyrus on January 23, 1984. Severe brain edema followed the surgery and the patient became comatose due to nonketotic hyperglycemic hyperosmolar coma. She died on the ninth postoperative day (Table). Computed tomography confirmed severe brain edema with mass effect on the fourth and ninth postoperative days. (Fig. 1)

Table Summary of cases

Case	Age	Sex	Localization	Histology	Transcortical approach	Edema duration from time of surgery	Outcome	
1	YS	16	Female	Left trigone	Meningioma	Middle temporal gyrus	8 years	Homonymous hemianopia tremor
2	TH	59	Female	Left paraventricle	Astrocytoma	Middle temporal gyrus	3 months	Died at 3 months due to meningitis
3	TF	63	Female	Left trigone	Menigivma	Middle temporal gyrus	9 days	Death from nonketotic hyperglycemic hyperosmolar coma on day 9
4	TN	23	Female	Right trigone	Ependymoma	Paramedian parieto-occipital	1 year 3 months	Homonymous hemianopia, agnosia
5	MM	35	Female	Right trigone	Ependymoma	Paramedian parieto-occipital	1 year 1 months	Convulsion, mental disorders

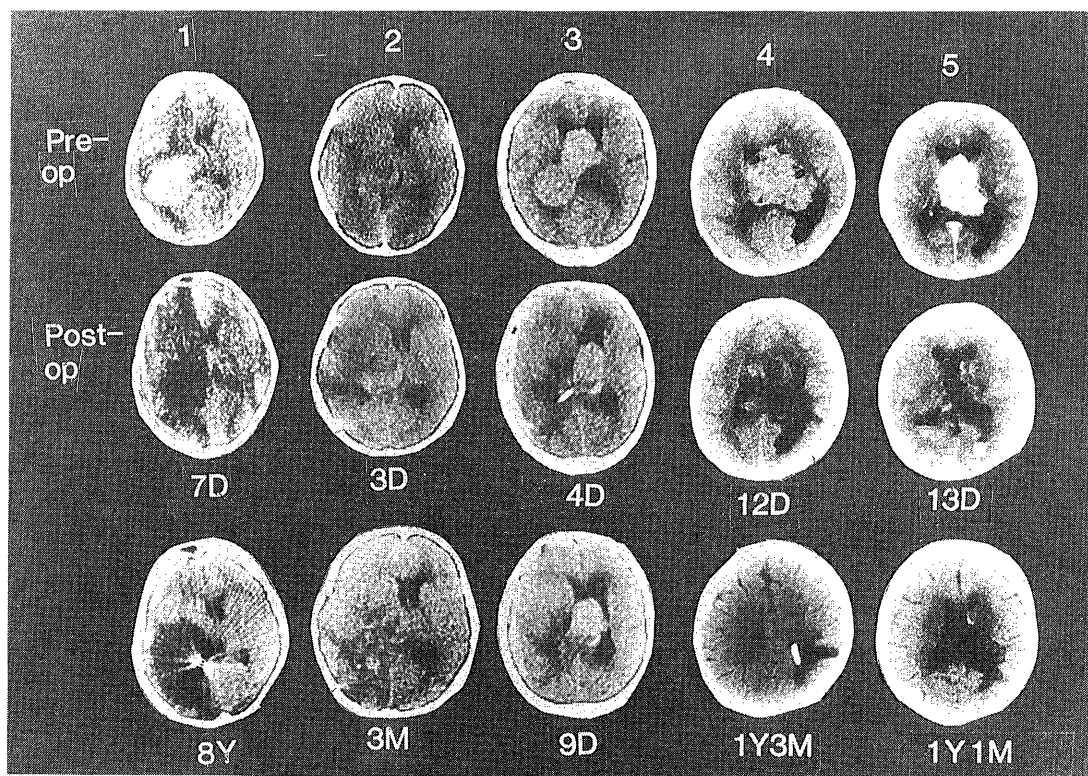


Fig. 1 Upper : Preoperative CT scan. Middle and lower : Postoperative CT scan.
Case number in figures, D : days, M : months, Y : years.

Case 4

A 23-year-old female had an ependymoma in the trigone and body of the right lateral ventricle subtotally removed through a sagittal paramedian parieto-occipital incision on September 21, 1984. Brain edema developed after surgery, leaving left homonymous hemianopsia and hemispatial agnosia. Ventriculo-peritoneal shunt was performed two weeks after surgery and radiotherapy was added (Table). On computed tomograms brain edema was found on the 12th postoperative day and remained after one year and three months.

Case 5

A 35-year-old female had an ependymoma in the right trigone and body subtotally removed through a sagittal paramedian parietooccipital incision on February 20, 1985. Brain edema was found after surgery and mental disturbances remained. She was discharged after radiotherapy, but epileptic seizure occurred one year and one month later (Table), and brain edema was still present (Fig. 1).

Pre- and postoperative angiographic study was carried on the last case, although only preoperative angiography was done on the others. In the venous phase of preoperative right carotid angiography, presence of abnormal veins, lateral shift of the thalamostriate vein, dilation of the venous angle and downward shift of the internal cerebral vein were found (Fig. 2, upper half), and the tumor stain was found in the venous phase of vertebral angiography (Fig. 2, lower half). In the venous phase of postoperative right carotid angiography, the thalamostriate vein and internal cerebral vein were poorly visualized (Fig. 3, upper half). The tumor stain was not found in the venous phase of vertebral angiography (Fig. 3, lower half).

DISCUSSION

In the five cases of lateral ventricle tumor described above, postoperative brain edema developed in all cases and persisted, as long as one year and, in one case, eight years. As a cause of postoperative brain edema in these cases, ill absorption of the edema fluid can be suspected. There are two possible absorption

routes of the edema fluid; one is the route where the edema fluid collected in the subependymal layer flows into the ventricle through the ependymal adhesive junctions, another is the route where the fluid is absorbed from the fenestrated venous capillaries of the subependymal layer and choroid plexus and flows into the internal cerebral vein and GALEN's great vein. It is assumed that the edema fluid flows into the ventricle through the adhesive junctions of the ventricular ependymal cells because of the difference in hydrostatic pressure. These routes could be damaged, and a large amount of the cerebrospinal fluid leaks into the brain parenchyma through the impaired ventricular wall. The subependymal capillaries in the periventricular areas and the venous capillaries of the choroid plexus have fenesters. The absorption route from the fenestrated venous capillaries of the subependymal layer and choroid plexus into the internal cerebral vein and GALEN's great vein can be permanently damaged by surgical maneuver. REULEN *et al.* (1977) have reported that edema fluid can move to the ventricle by bulk flow and fill the ventricle when the extracellular lumen is enlarged by edema following direct injection of the artificial cerebrospinal fluid into the white matter.³⁾⁴⁾ Besides the route of edema fluid flowing from the ependymal cells into the ventricle through the ependymal adhesive junctions, the authors presume the existence of another route where the fluid is absorbed into the internal cerebral vein and GALEN's great vein from the fenestrated venous capillaries of the surrounding periventricular areas, including the choroid plexus. This presumption is based on an experiment on rats in which anti-HRP antibody had been produced beforehand, and experimental brain edema was produced by embolization or freezing method. The brain specimen was stained with immunohistochemical technique, and absorption the edema fluid was studied microscopically using its own serum protein, anti-HRP antibody, as the tracer. As a result there was found heavily-stained anti-HRP antibodies surrounding the subependymal layer of the lateral ventricle and the choroid plexus itself. Electron microscopic studies are still in progress.¹⁾ HASHIMOTO *et al.* (1985) also reported that protein components, which

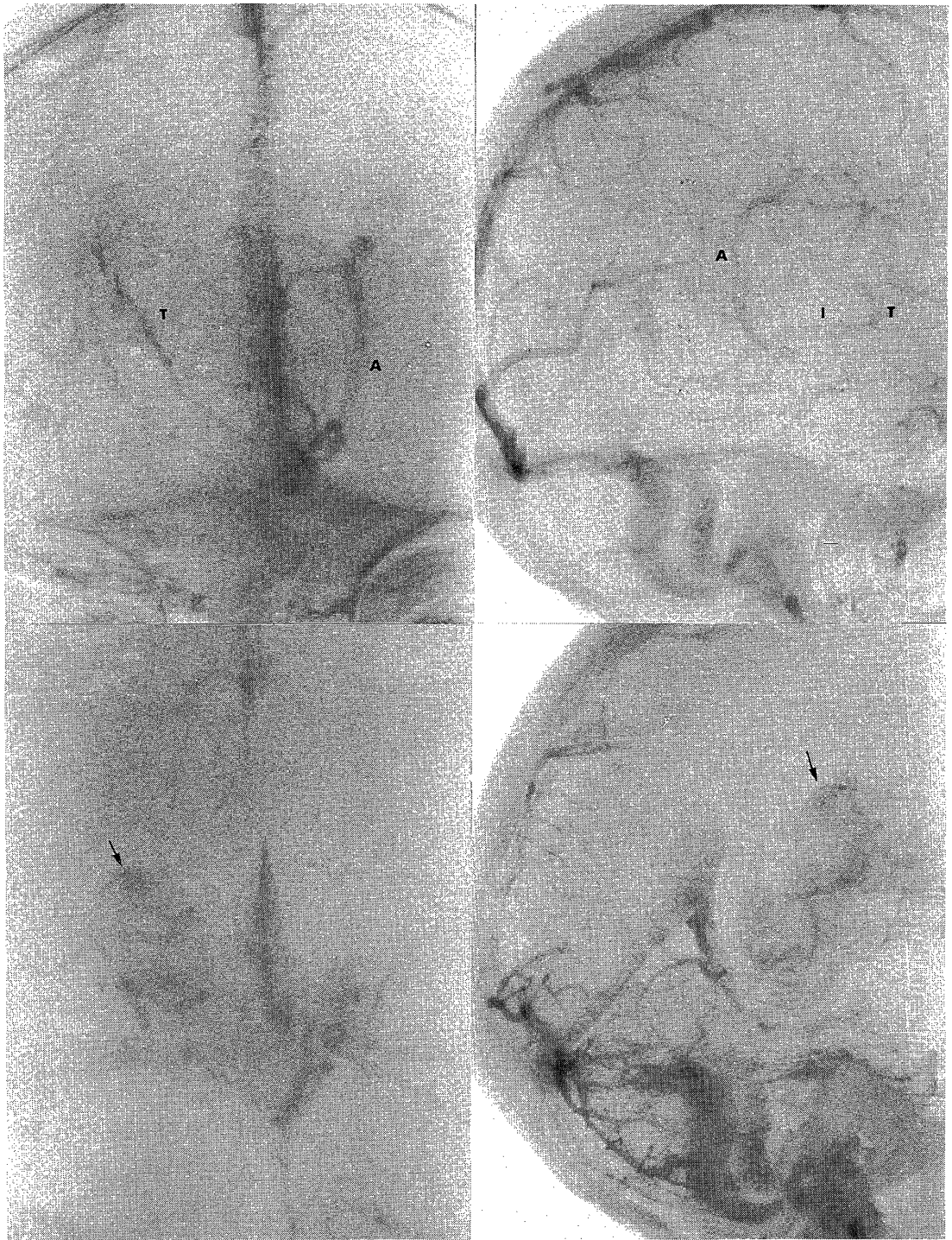


Fig. 2 Case 5, before surgery. Upper : Venous phase by right carotid angiography showing an abnormal vein (A), displacement of the thalamostriate vein (T) and depression of the internal cerebral vein (I). Lower : Venous phase by vertebral angiography showing a faint, uniform tumor blush (arrow).

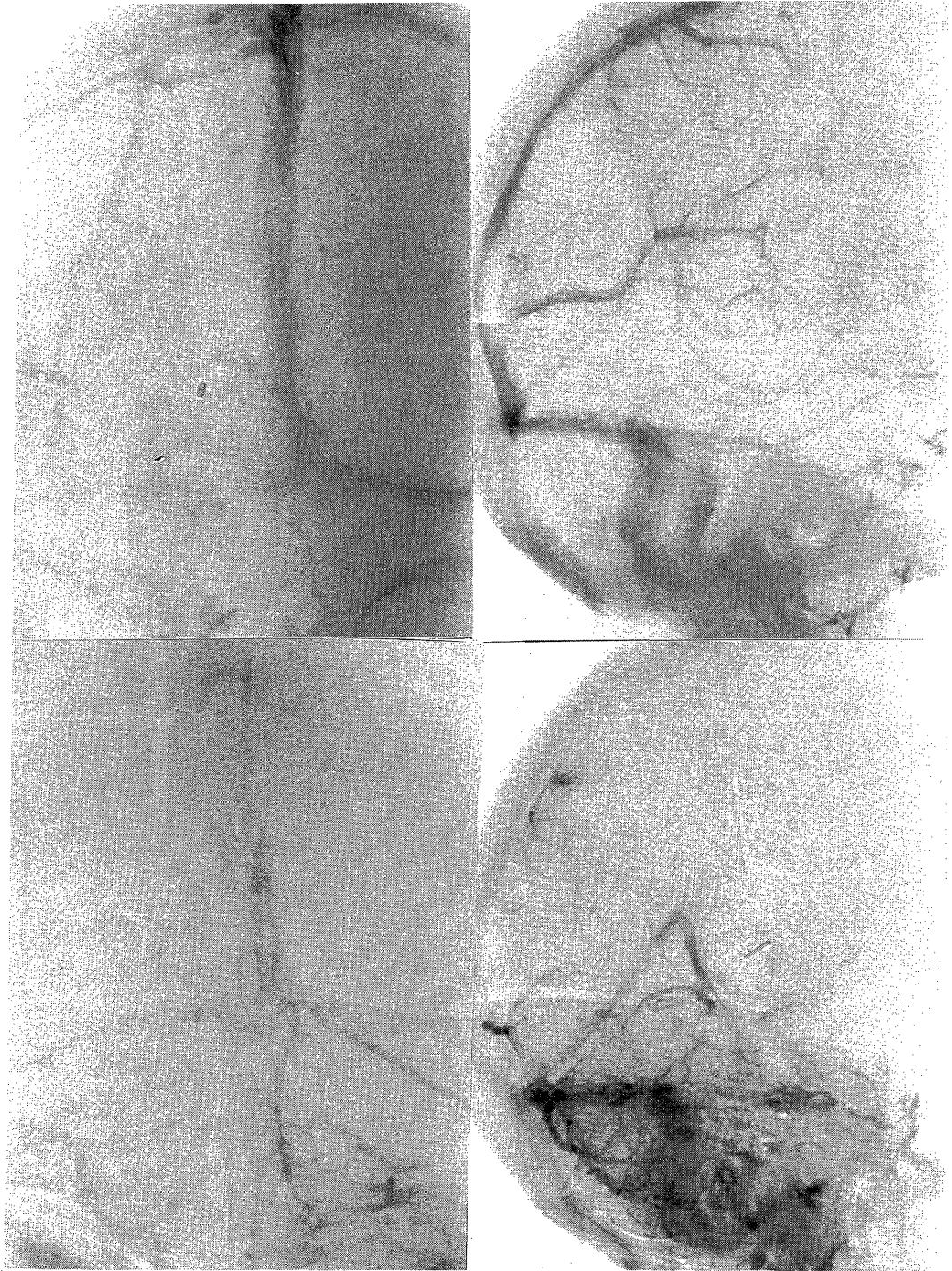

Fig. 3 Case 5, after surgery. Upper : Venous phase by right carotid angiography showing non-filling of the thalamostriate and internal cerebral veins. Lower : Venous phase by vertebral angiography showing disappearance of the tumor blush.

permeated through the capillaries spread into the cerebrospinal fluid and finally were absorbed in the venous system of the circumventricular organs.²⁾

CONCLUSION

As the causes of postoperative brain edema following surgery of lateral ventricle tumors, two factors were considered in addition to obstruction of the absorption route from the subependymal layer into the ventricle through the ependymal adhesive junctions; i.e. reverse leakage of the cerebrospinal fluid through the injured ventricular wall into the brain parenchyma and blockade of the flow from the fenestrated venous capillaries of the subependymal layer and choroid plexus into the internal cerebral vein and GALEN'S great vein.

Our findings suggest that the surgical approach to lateral ventricle tumors by incising and tunnelling through the brain over the tumor is an unwise approach on account of post-

operative brain edema. An approach from a more distant part of the brain to the lateral ventricle is preferable.

REFERENCES

1. FUKUSHIMA M, SHIBATA S, JINNOUCHI T, MORI K. Transition and absorption of edema fluid. Investigation by autoserum protein. *J Clin Electron Microscopy (Jpn)* 18 : 660-61, 1985
2. HASHIMOTO PH, GOTOW T, ICHIMURA T, ARIKUNI T. Are the arachnoid villi really the main drainage route for the cerebrospinal fluid into the blood stream? An Electron Microscopic Study. *Okajimas Folia Anat (Jpn)* 58 : 819-36, 1982
3. REULEN HJ, GRAHAM R, SPATZ M, KLATZO I. Role of pressure gradients and bulk flow in dynamics of vasogenic edema. *J Neurosurg* 46 : 24-35, 1977
4. TSUYAMA M, HIRATSUKA H, INABA Y, ITO U, REULEN HJ. A mechanism of development and resolution of vasogenic brain edema. *Neurol Surg (Tokyo)* 14 : 287-94, 1986