

Radiation-induced carcinoma of the rectum

Cheng-Shan CHIEN, Takatoshi SHIMOYAMA, Tohru NAKAGOE
Tatsuo HIRANO, Teruhisa SHIMIZU, Ryoji TAKAHIRA
Hiroyuki KUSANO, Mitoshi YOKOTA, Seiichiro WATABE
Kosei MIYASHITA, Masao TOMITA

*The First Department of Surgery
Nagasaki University School of Medicine*

Received for publication, May 23, 1988

ABSTRACT : Two patients with rectal cancer induced by irradiation for the treatment of uterine cancer were reported. Surgical outcome for radiation-induced cancer was satisfactory as far as the primary focus was well controlled. Definition of radiation-induced cancer also was discussed. It is the most important factor to be a long time interval of more than 10 years by detection of rectal cancer after irradiation and to reveal a histologic pattern concerning irradiation tissue damage.

INTRODUCTION

Radiation therapy is one of the available cancer therapies although radiation-induced carcinoma takes place. As for occurrence of radiation-induced carcinoma, there are the reports concerning carcinomas of the skin and the thyroid gland, and leukemia. This paper describes the two patients with radiation-induced carcinoma of the rectum following irradiation for the treatment of uterine cancer.

PATIENTS

As shown in Table 1, two patients were reported. The ages are ranging from 55 to 65. The primary cancers were cervix carcinoma of squamous cell cancer which corresponded to stage III in either case.

In the patient 1, the OKABAYASHI' operation was applied and postoperative irradiation was intraluminally and externally applied although

dosis could not be made clear.

In the patient 2, the operation was not carried out. Approximately 7200 rad of intraluminal radiation and 5000 rad of external one were applied respectively. The time interval from irradiation to occurring carcinomas of the rectum were 11 years in patient 1 and 19 years in patient 2, respectively.

The locations of rectal cancer were the rectum on the right below the peritoneal reflection in patient 1 and the anal canal on the anterior wall in patient 2. These were distal parts of the rectum.

The macroscopic findings were ulcerative types in both, demonstrating no characteristic of radiation-induced cancer itself.

According to histologic findings, well-differentiated adenocarcinoma was demonstrated in patient, which was showing the depth of cancer of pm, vascular invasion of ly_1 , and vo , the degree of infiltration of INF and nodal involvement of no , although moderately differentiated adenocarcinoma was indicated in

Table 1. Patient presentation

	Patient 1	Patient 2
Stage of uterine cancer	cervix sq stage III Okabayashi' op. intraluminal (+) external irradiation (+)	cervix sq stage III (-) 72 Gy 50 Gy
time interval	11 yrs	19 yrs
rectal cancer	Rb II type well. diff. pm ly 1 v o INF n o	P II type mod. diff. a 1 ly 1 v o n o
outcome	10 yrs survival	8 M died of cancer-unrelated disease

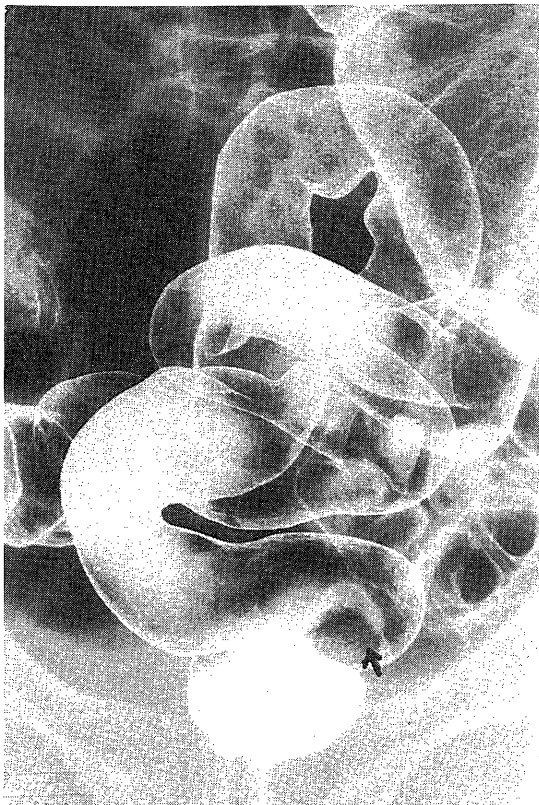


Fig. 1. Barium enema in the patient 1, showing cancer in Rb

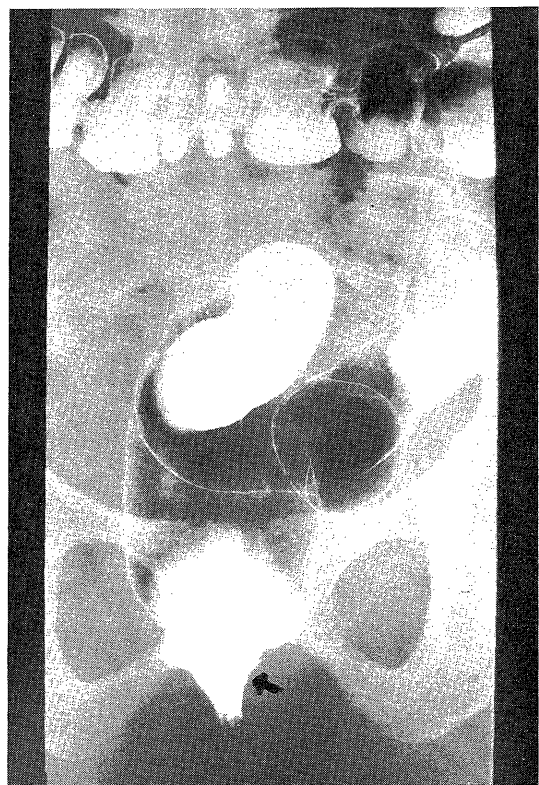

Fig. 2. Barium enema in the patient 2, showing cancer in P




Fig. 3. Surgical specimen upper in the patient 1 and lower in the patient 2

patient 2, which was a 1, ly₁, v₀, INF and no. There was no characteristics of radiation-induced carcinoma of the rectum as to histologic patterns. Of interest is the fact that the common findings were recognized as follows, the submucosal layer, cystic dilatation of atypical glandular ducts, fibrosis in the submucosa and marked vasculitis of the gut wall. These are a

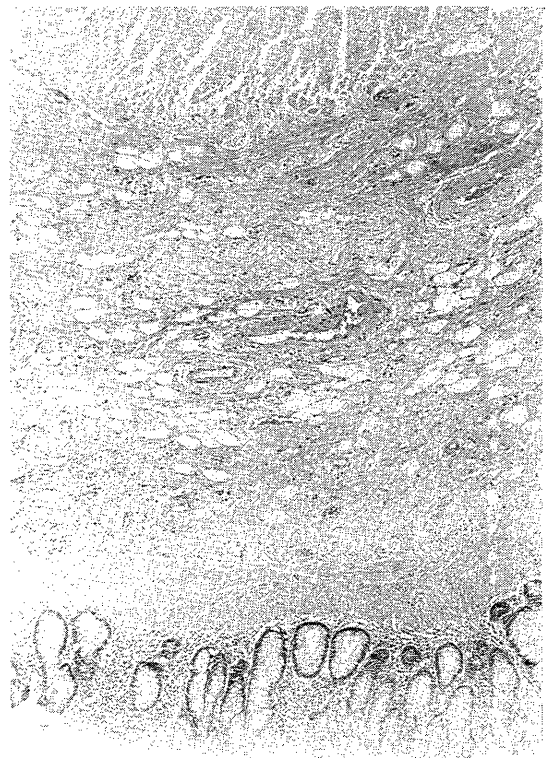

Fig. 4. Histologic finding, indicating atrophy in the submucosal layer, cystic dilation of atypical duct and fibrosis in the submucosal layer

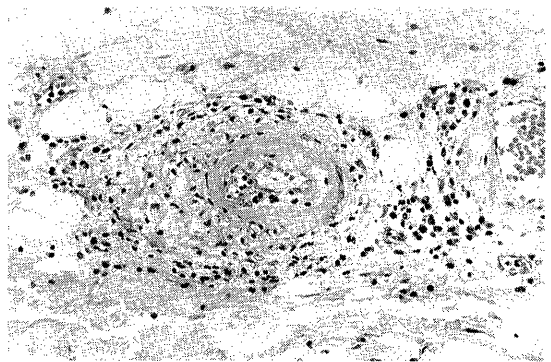


Fig. 5. Histologic finding of vasculitis, showing irradiation damager

reflection of radiation tissue damage.

Surgical outcome in the patient 1 was satisfactory without any metastasis, although the patient 2 died of myocardial infarction in spite

of no recurrent sign.

DISCUSSION

Since it has been recognized that skin cancer is caused by irradiation therapy, there are many reports concerning malignant diseases seen following irradiation as well as explosion of the atomic bomb. These were mainly composed of leukemia, thyroid cancer, osteosarcoma and skin cancer.

As for rectal cancer following irradiation for uterine carcinoma, SLAUGHTER¹⁾ reported first in 1957. However, it is not yet clear as to whether direct effect of irradiation causes carcinoma on the rectal mucosa or as to whether synchronous double cancer takes place by chance. TOKI²⁾ reported the criteria for radiation-induced cancer on the basis of the 74 cases reported in the foreign countries, that is, 1) cancer location should be within the irradiation field 2) there is the certain time interval from irradiation to appearance of cancer 3) noticeable irradiation tissue damage should be presented on the surrounding tissues. CASTRO³⁾ analyzed 26 rectal cancers whose cancers occurred following irradiation therapy and included the following conditions, that is, 1) colon cancer occurred in the field of previous irradiation 2) the tumor-bearing colon had clinical irradiation damage 3) histologic irradiation tissue damage is visualized and noted and 4) the time interval from irradiation to occurrence of cancer should be more than 10 years.

QUIZILBACH⁴⁾ reported with respect to a finding of histologic damage by irradiation as follows 1) atrophy of the submucosal layer 2) hyaline degeneration of the muscular layer and the serosa 3) the finding of vasculitis in the intestinal wall.

In this report, the histologic damage by irradiation is not pronounced except for vasculitis. As 10 years had been elapsed, the histologic damage might well have been modified.

However, surgeons must bear it in mind that irradiation damage reached in considerably wide range. LOCALIO⁵⁾ was aware of histologic irradiation damage that even when anastomotic site seemed to be normal, irradiation damage at anastomosis appears in several years.

KAKEGAWA⁶⁾ also emphasized that determination of the anastomosis line should be made by histologic collagen production as well as by the degree of intimal degeneration of the vessels. According to the collective analysis in the 15th Japanese colon cancer research meeting held in 1981, 45 (86.5%) out of the 52 colon cancers induced by irradiation were based on the treatment of uterine cancer. The clinical features are that all cases are more than age 60 and favorable location is the rectum, most elapse from 10 to 25 years, macroscopic cancer findings of II or III types, curative operation can be obtainable and surgical outcome is satisfactory to get long-term survivors.

BLACK⁷⁾ also reported in follow-up study on 100 patients who underwent irradiation therapy for the treatment of uterine cancer, that colon cancer had occurred three cases (14.3%) out of the 21 cases elapsing more than 10 years following the treatment of uterine cancer.

We must pay attention to colon cancer occurring after irradiation therapy for uterine cancer even though it had passed more than 10 years.

REFERENCE

- 1) SLAUGHTER, P.D., *et al.*: Mucosal carcinoma as a result of irradiation. *Arch. Surg.* 74: 420-429, 1956.
- 2) TOKI, Y. *et al.*: A case report of radiation-induced rectal cancer with statistical analysis on 74 cases in foreign countries. *Clinical cancer* 28: 1309-1318, 1982.
- 3) CASTRO, E.I.B. *et al.*: Carcinoma of large intestine in patients irradiated for carcinoma of cervix and uterus. *Cancer* 31: 45-52, 1973.
- 4) QUIZILBACH, A.H.: Radiation-induced carcinoma of the rectum. *Arch. Pathol.* 98: 118-212, 1974.
- 5) LOELIO, S.A. and STONE, A.: Surgical aspects of radiation enteritis. *Surg. Gynecol. Obstet.* 129: 1163-1172, 1974.
- 6) KAKEGAWA, T. *et al.*: Treatment of radiation colitis. *Dig. Surg.* 4: 1493-1501, 1981.
- 7) BLACK, W.C. and ACKERMAN, L.V.: Carcinoma of the large intestine as a late complication of pelvic radiotherapy. *Clin. Radio.* 16: 278-281, 1965.