

## Surgery for older patients with advanced esophageal cancer involving the adjacent organs.

Masao TOMITA, Hiroyoshi AYABE, Katsunobu KAWAKARA  
Koji KIMINO, Hirohara TSUJI, Tadayuki OKA  
and Kamei SHA

*First Department of Surgery  
Nagasaki University School of Medicine*

*Received for publication, December 26, 1987*

**SUMMARY :** The treatment for thirty three advanced carcinoma of thoracic esophagus with cancer infiltrations to the adjacent organs were clinically analysed. The most affected organs were the aorta, followed by the trachea and bronchus. Clinical features are that two or three organs are affected at the same time and only one organ involvement is rare in frequency. Furthermore, nodal involvement is commonly accompanied and is spreading to the mediastinum and abdomen.

Surgical outcome of combined resection with involved organs is now unsatisfactory. In contrast, to relieve severe symptoms and to ensure the quality of life, aggressive combined resection is indispensable. It is assumed that further advances in improvement of potent anticancer drugs and surgical techniques may lead to prolonged survival of advanced esophageal cancer patients.

### INTRODUCTION

Advances in diagnostic techniques for carcinoma of the esophagus have made it possible to establish early precise diagnosis for this lesion. However, surgical treatment for advanced cancers is now still main. Needless to say, curative operation is mandatory for obtaining prolonged survival, even in advanced cancer patients.

In patients with cancers involving the adjacent organs, combined resection is required for complete resection of cancer infiltration. Combined resection has a high risk for the patients aged over 70 and on the condition of under-nutrition, often leading to fatal complications. At present, it is a great issue to settle how to manage and treat such a patient.

The aim of this study is to clarify a clinical

value of aggressive surgery of combined resection for advanced cancer patients on the basis of clinical experience.

In this study, experience with aggressive surgical treatment for advanced carcinoma of the esophagus was analysed to evaluate and verify the practical value of the surgery for advanced carcinoma of the esophagus.

### MATERIAL AND METHOD

From January 1971 to December 1988, thirty-two patients with carcinoma of the esophagus involving adjacent organs were cared in the First Department of Surgery, Nagasaki University School of Medicine. The age ranged from 46 to 78 years with an average of  $60.3 \pm 8.3$ . Males were predominant in a ratio of 26 : 6. The location of the esophagus was upper thoracic esophagus (Iu) in 9, middle (Im) in 20

and lower (Ei) in 3 respectively. Nodal involvement was  $N_0$  in 3,  $N_1$  in 1,  $N_2$  in 10,  $N_3$  in 9 and  $N_4$  in 9. In the majority of patients, nodal involvement beyond the regional nodes concomitantly existed. The involved adjacent organs were the descending aorta in 18 (56.2%), the trachea and main bronchus in 12 (37.5%), the lung in 5 (15.6%), the pericardium in 3 (9.3%), the diaphragm in 2 (6.3%) and the thoracic vertebra in 1 (3.1%) respectively. Ten patients out of 18 with carcinoma involving the aorta accompanied concurrently involved other organs.

As for oncological radicality of surgery, relative non-curative operations were performed in 12 (37.5%) and absolute non-curative operations in 20 (62.5%) which comprised of involved aorta in 13 and involved trachea and bronchus in 8.

## RESULTS

Surgical outcome for carcinomas involving adjacent organs between patients who underwent absolute and relative non-curative operation was compared as shown in Table 1. The results regarding the operative and hospital death, and the survival time after surgery were almost the same. However, mean survival months of  $4.9 \pm 4.6$  months in patients with relative non-curative operation was

**Table 1.** Surgical outcome of a<sup>3</sup> patients who underwent resections for esophageal cancer

result	number of patients (%)		
	absolute curative N=20	relative curative N=22	total N=32
operative death	7 (35.0)	4 (33.3)	11 (34.3)
hospital death	13 (65.0)	8 (66.6)	21 (65.6)
operable death	13 (65.0)	8 (66.6)	21 (65.6)
survivors	3	1	4
deaths	9	8	17
mean survival period ( $\times \pm$ SD)	$3.5 \pm 2.7$ months	$4.9 \pm 4.6$ months	$4.2 \pm 3.6$ months

longer than those of  $4.2 \pm 3.6$  months who had absolute non-curative operation.

In older patients aged over 70 years who had combined resection of involved organs, their prognoses were not satisfactory as indicated in Table 2. In these patients, nodal involvement reached in  $N_2$  except 2 patients and operation curability was not ensured in all but one who now still survived 2 months without any clinical complaint in spite of having experienced postoperative respiratory failure.

On the basis of our clinical experience with the treatment of carcinoma of thoracic esophagus in carcinomas of thoracic esophagus between patients aged less than and more than 70 years, the survival time in patients older

**Table .** older patients with carcinoma involving adjacent organs

case	age sexe	location	involved organ	cura- bility	reconst ruction	combined therapy	prognosis
1	71 • M	lulmn2	aorta	CO	stomach retroster	pre chemo	pneum onitis M <sup>+</sup>
2	72 • M	lm n2	aorta	CO	stomach retro-	pre radiet	pneum onitis 23D <sup>+</sup>
3	71 • M	lm n2	aorta bronchus	CO	stomach retro-	pre radiat	pneum onitis 1M <sup>+</sup>
4	71 • M	lulmn0	aorta lung	CO	stomach retro-	pre radiat	pneum onitis 6M <sup>+</sup>
5	78 • M	lm n2	aorta	CO	stomach antestern	(-)	pneum onitis 3M <sup>+</sup>
6	72 • M	lm n2	aorta	CO	stomach retroster	(-)	resp. railure strvive 2M <sup>+</sup>

+ dead

than 70 years was superior to that in patients younger than 70 years. As shown in Fig 1. the indication for surgery is limited. In this study, the indication for surgery was extended to patients with complaints associated with advanced cancer, leaving out consideration about operative curability and just contemplating a palliative operation to relieve symptoms.

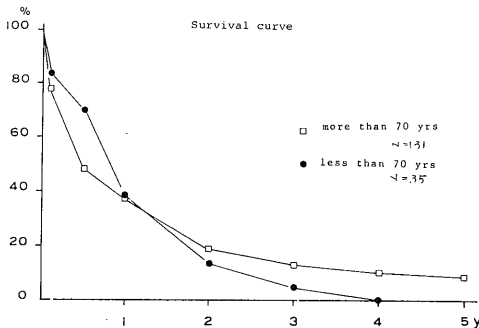


Fig. 1. Comparison in survival curve between two groups more than and less than 70 years old

## DISCUSSION

It is accepted that carcinomas of the esophagus involving the adjacent organs account for 20%, and one-third of them are involving the aorta. The prognoses of advanced esophageal cancers are unsatisfied, in particular, non-curative operation carries far poor prognosis. While involved adjacent organs are the lung, diaphragm, pericardium, their prognoses are ensured by curative operation of combined resection. In contrast, when carcinoma involves the wall of the aorta, the prognosis has become worse.

Furthermore, quite a few cases with carcinoma involving the wall of the aorta concomitantly involve another organs. Therefore, oncological radicality by surgery could not necessarily be ensured.

In this series, other organs were affected at the same time in 10 out of 18 cases with carcinomas involving the aorta, showing a wide cancer spread. A second vulnerable organ to cancer infiltration from carcinoma of the esophagus was the tracheobronchial tree.

The preoperative diagnosis for cancer

infiltration involving the neighboring organs is made by CT aortography, bronchography, bronchoscopy and endoscopic sonography. As a rule, it follows that the wall of the aorta is characteristic of having a high resistance to cancer infiltration. It is based on inherent hard wall in consistence which enables the aorta to tolerate a high intraluminal pressure. However, if cancer infiltration reaches the adventitia across the aortic walls, it spreads widely and involves vasa vasorum which is consequently obstructed by thrombosis. It causes a catastrophe of unexpected rupture due to ischemic necrosis of the wall of the aorta by thrombosed feeding arteries of vasa vasorum. As for a resection of the wall of the aorta, there are some unsolved questions, in respects of operative approach, temporary bypass and staged operation.

In an attempt to combine with concomitant resection of the aorta, left thoracotomy, or prior placement of extra-anatomical bypass between axillar artery and femoral artery to thoracotomy<sup>8)</sup> are the present surgical approaches of choice. However, when the bypass graft was constructed at the same surgical field, it is feared that contamination of the graft by manipulation of the esophagus may cause rupture at anastomosis by ensuing infection. It is assumed that washing of the thoracic cage with a large amount of saline and good expansion of the lung following thoracotomy to minimize the dead space are effective in prevention of such a complication. PAIOLEO<sup>9)</sup> also reported that wrapping of a graft with pedicled latissimus dorsi muscle is of great value to protect the graft from infection. MORI<sup>10)</sup> reported that the ideal conditions of carcinoma of the esophagus surviving more than 1 year by resection with combined irradiation and chemotherapy are that nodal involvement should be excluded. Complete resection of carcinoma should be made and full dosis of postoperative chemotherapy course should be prescribed without discontinuation.

On the other hand, the surgical outcome following combined resection with the trachea and bronchus is still poor. And also combined resection is not prevalent in clinical use because of poor patient's condition, technical

difficulty and high mortality due to grave surgical insult.

THOMPSON<sup>11)</sup> first reported a surgically successful case who underwent lower tracheal and carinal resection with subtotal esophagectomy. In patients with carcinoma of the esophagus involving the adjacent organs, symptoms are vexing and threaten their life and severely vitiate the quality of life.

The main drawback to this procedure is that complication more often occurs than conventional esophagectomy because of poor blood perfusion to the anastomotic site of the esophagus as already reported by authors.<sup>12)</sup> Little information is available for combined resection of the trachea and bronchus. In this study, it is indicated that the combined resection of involved adjacent organs with esophagectomy is technically feasible if the patient's condition permits surgery. Although the prognoses for resections of the lung, pericardium and diaphragm are relatively fair, those for the trachea, bronchus and the aorta are worse. When combined resections of the trachea and main bronchi with esophagectomy are attempted, blood perfusion at tracheal and bronchial anastomosis has become worse. Consequently anastomosis does not frequently take place. Surgeons should be aware of predisposing factors on anastomosis insufficiency as already cited by us. Omentopexy is of great value to prevent such a grave complication to lead to detrimental outcome. Needless to say, the favorable candidate for a combined resection with the trachea, bronchus and aorta is a patient with no nodal involvement and limited cancer infiltration to the contiguous organs. To relieve severe symptoms such as pain, hemoptysis, fear of possible perforation episodes of the aorta, an extension of the indication of aggressive operation is needed. Based on a result of this study, further advances in potent chemotherapy, operation techniques and pre-postoperative cares might carry a high prevalence of this operation in the near future, and would be of great help to improve the survival rate and quality of life in patients with carcinoma of the esophagus.

## REFERENCE

- 1) KAWAHARA, H. FUJITA, H. ODAGIRI, S : combined resection with great vessel and the technique of its reconstruction. *J. clin. Surg.* 40 : 1327-1335, 1985 (in Japanese).
- 2) KAWAHARA, H. FUJITA, H. ODAGIRI, S. HIDAKA, M. *et al* : combined resection of the thoracic aorta associated with subtotal esophagectomy for carcinoma of the esophagus, *JJpn Surg. Soc.* 86 : 1546-1551, 1985.
- 3) TOMITA, M. AYABE, H. KAWAHARA, K *et al* : Feasibility of extended operation for carcinoma of the esophagus in combination of a resection of the descending aorta simultaneously. *J. Ann Thorac. Surg* 6 : 77-80, 1986.
- 4) TOMITA, M. AYABE, H. KAWAHARA, K *et al* : Surgical consideration of esophagectomy combined with tracheobronchoplastic procedure for the treatment of esophageal cancer, *Acta Medica Nagasaki.* 31 : 143-151, 1986.
- 5) THOMPSON DT : Lower tracheal and carinal resection associated with subtotal oesophagectomy for carcinoma of oesophagus involving trachea. *Thorax* 28 : 257-262, 1987.
- 6) POSTOLOFF AV and CANNON WH : Genesis of aortic perforation secondary to carcinoma of the esophagus. Report of observation in two cases. *Arch. Pathol. Lab. Med.* 41 : 533, 1946.
- 7) BOTTIGLIER NG, PALMER ED, BRIGGS GW *et al* : Aorto-esophageal fistula complicating carcinoma involving the esophagus, *Am. J. Dis* 8 : 837, 1963.
- 8) ENDO, M. YAMADA, A HAYASHI, T. *et al* : A resection of thoracic esophageal cancer with combined thoracic aorta. *J. Jpn. Surg. Soc.* 84 (suppl) 111, 1983.
- 9) PAIROLERO PC. ARNOLD PG. PIEHLER JM : Intrathoracic transposition of extrathoracic skeletal muscle. *J. Thorac. Cardio vasc. Surg* 86 : 809-817, 1983.
- 10) MORI, S. : treatment of A carcinoma of thoracic esophagus. *Surgical Mook*, 24 : 64-71, 1982.
- 11) THOMPSON DT : Lower tracheal and carinal resection associated with subtotal oesophagectomy for carcinoma of oesophagus involving trachea. *Thorax* 28 : 257-262, 1987.
- 12) TOMITA, M. AYABE, H. KAWAHARA, K. *et al* : Benefit from omentopexy on bronchial wound healing in performing concurrent esophagectomy. *Acta. Med. Nagasaki.* 33 : 87-90, 1988.