

Iron Accumulation and Presence of Hepatitis B Core Antigen in Hepatocellular Carcinoma in Hemochromatotic Liver

Masachika SENBA* and Kioko KAWAI**

* Department of Pathology, Institute of Tropical Medicine,
Nagasaki University, Nagasaki 852, Japan

** Department of Pathology, Nagasaki University School of
Medicine, Nagasaki 852, Japan

Received for publication, December 26, 1987

SUMMARY : An autopsy case of hepatocellular carcinoma combined with hemochromatosis and hepatic cirrhosis were studied with iron accumulation and hepatitis B virus. Iron accumulation was confirmed by Prussian blue reaction. A positive reaction for hepatitis B surface antigen and hepatitis B core antigen were investigated by immunoperoxidase methods. Hepatocellular carcinoma with hepatitis B core antigen is accompanied by iron accumulation. This suggests that hepatitis B core antigen produces degeneration or collapse of genes of hepatocellular carcinoma resulting in iron metabolism disorder.

INTRODUCTION

Iron accumulation could not be identified in hepatocellular carcinoma lesions of siderotic human¹⁾ and experimental animals.⁹⁾ However, Hirota and his colleagues reported two iron positive cases in hepatocellular carcinoma with cirrhosis combined with primary hemochromatosis, where one case was hepatitis B surface antigen positive in non-cancerous tissue and the other was negative.³⁾ It is suggested that the hepatitis B virus infection affects the iron metabolism disorder. Therefore, the authors further searched for iron accumulation in hepatocellular carcinoma tissue using the Prussian blue reaction, and the detection of hepatitis B surface antigen and hepatitis B core antigen by immunoperoxidase methods. The purpose of this study is to find the relationship among iron accumulation, hepatitis B surface antigen and/or hepatitis B core antigen in hepatocellular carcinoma tissue.

CASE REPORT

A 67-year-old Japanese male, 170cm in height, 51kg weight was autopsied at Nagasaki University Hospital. The laboratory investigations showed the following : serum bilirubin, 6.9mg/dl ; serum glutamic oxaloacetic transaminase (GOT), 103mu/ml ; serum glutamic pyruvic transaminase (GPT), 49mu/ml. Hepatitis B surface antigen was positive, and hepatitis B surface antibody was negative. At autopsy, hepatocellular carcinoma with macronodular cirrhosis was found, and his liver weighed 1900 g. The cirrhotic liver had a large carcinoma measuring 14×9cm in diameter located in the right lobe, and smaller carcinoma nodules were scattered throughout the entire liver. Histologically, iron accumulation was seen in the liver, the pancreas, and both kidneys. The carcinoma of metastatic lesions were found in the both lungs and right adrenal gland.

MATERIALS AND METHODS

The specimens were fixed in 10% formalin and embedded in paraffin. Sections were cut at 4 micron, and stained with hematoxylin-and-eosin, and Gomori's method for iron (Prussian blue reaction). These materials were stained with hepatitis B surface antigen (Dako PAP kit : k523, Lot. 063-3), and hepatitis B core antigen (Dako PAP kit : K511, Lot. 025-3) using immunoperoxidase methods.

RESULTS

In this case, iron accumulation was observed not only in the non-cancerous tissue but also in the cancerous tissue (Fig. 1). In hepatocellular carcinoma tissue, this case was hepatitis B core antigen positive (Fig. 2), but hepatitis B surface antigen was negative by immunoperoxidase methods. In non-cancerous tissue, both hepatitis B core antigen and hepatitis B surface antigen were positive. These findings suggest that hepatitis B core antigen influences iron accumulation, but hepatitis B surface antigen does not lead to iron accumulation in the hepatocellular carcinoma lesions.

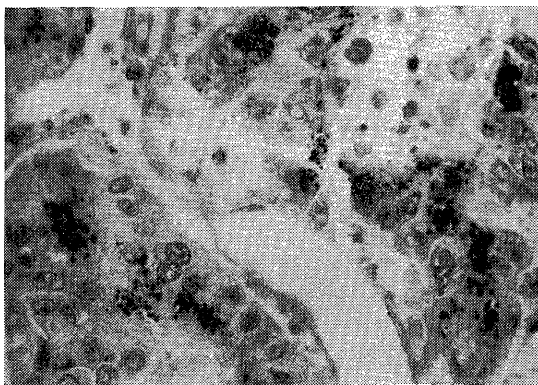


Fig. 1. Iron accumulation is seen in the hepatocellular carcinoma tissue. Prussian blue reaction ($\times 400$).

DISCUSSION

Unknown are the reasons for coexistence of iron accumulation and hepatitis B core antigen in hepatocellular carcinoma tissue. A possible

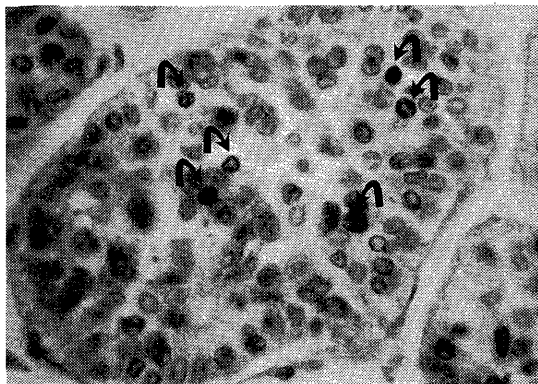


Fig. 2. Positive immunoperoxidase staining for hepatitis B core antigen (arrows) is identified in the nuclei of hepatocellular carcinoma tissue. Immunoperoxidase for hepatitis B core antigen ($\times 400$).

explanation may be that hepatitis B core antigen causes degeneration or collapse of gene of hepatocellular carcinoma, which results in iron accumulation in the cytoplasm. Generally, it is true that no stainable iron is found in hepatocellular carcinoma and precancerous nodules,^{1,9)} because hepatocellular carcinoma tissue might take up much more iron and then release iron rapidly than non-cancerous tissue of the same liver.^{2,4,8)} Therefore, the iron release process of the hepatocellular carcinoma tissue might be different from that of the normal tissue. The amount of iron contained in the ferritin was much lower in hepatocellular carcinoma than normal liver tissue.⁵⁾ Ferritin with low iron content had a relatively high turnover rate,⁷⁾ so that low iron content ferritin in the cancerous tissue could not be converted into high content ferritin or hemosiderins.⁸⁾

REFERENCES

- 1) BERMAN C : Primary carcinoma of the liver. Lewis & Co., London, 1951.
- 2) HARRISON PM, HOY TG, MACARE IG, HOARE RJ : Ferritin iron uptake and release. *Biochem. J.*, 143 : 445-451, 1974.
- 3) HIROTA N, HAMAZAKI M, WILLIAMS GM : Resistance to iron accumulation and presence of hepatitis B surface antigen in preneoplastic and neoplastic lesions in human hemochromatotic liver. *Hepato-gastroenterol.*, 29 : 49-

- 51, 1982.
- 4) HOY T, HARRISON PM, SHABIR M : Uptake and release of ferritin iron. *Biochem. J.*, **139** : 603-607, 1974.
 - 5) NIITSU Y, OHTSUKA S, KOHGO Y, WATANABE N, KOSEKI J, URUSHIZAKI I : Hepatoma ferritin in the tissue and serum. *Tumor Res.*, **10** : 31-42, 1975.
 - 6) SENBA M, NAKAMURA T, ITAKURA H : Statistical analysis of relationship between iron accumulation and hepatitis B surfacen antigen. *Am. J. Clin. Pathol.*, **84** : 340-342, 1985.
 - 7) TRUMP BF, VALIGORSKY JW, ARSTILA AU, MERGNER WJ, KINNEY TD : The relationship of intracellular pathways of iron metabolism to cellular iron overload and the iron storage diseases. *Am. J. Pathol.*, **72** : 295-336, 1973.
 - 8) YAMASHITA H : Radio-iron uptake of rat hepatoma. *Gann*, **70** : 593-600, 1979.
 - 9) WILLIAMS GM, YAMAMOTO RS : Absence of stainable iron from preneoplastic and neoplastic lesions in rat liver with 8-hydroxyquinoline-induced siderosis. *J. Natl. Cancer Inst.* **47** : 685-692, 1972.